

SARCOMA OF THE SOFT TISSUES, OTHER THAN LYMPHOSARCOMA,
TREATED BY TOXIN THERAPY.



*End Results in 186 Determinate Cases
with Microscopic Confirmation of Diagnosis:
49 Operable, 137 Inoperable.*



Helen C. Nauts, Louis Pelnér, M.D., George A. Fowler, M.D.

MONOGRAPH #3

NEW YORK CANCER RESEARCH INSTITUTE, INC.

1290 MADISON AVENUE

NEW YORK 28, N. Y.

NEW YORK 1959

Helen C. Nauts, Louis Pelnér, M.D., George A. Fowler, M.D.

SARCOMA OF THE SOFT TISSUES, OTHER THAN LYMPHOSARCOMA,
TREATED BY TOXIN THERAPY.



*End Results in 186 Determinate Cases
with Microscopic Confirmation of Diagnosis:
49 Operable, 137 Inoperable.*



MONOGRAPH #3

NEW YORK CANCER RESEARCH INSTITUTE, INC.

1290 MADISON AVENUE

NEW YORK 28, N. Y.

NEW YORK 1959

PRINTED IN U. S. A.
1959

TABLE OF CONTENTS

	<i>Page</i>
INTRODUCTION	1
FIGURES 1 TO 6	7
SERIES A. Inoperable Successes. 70 Cases	12
Brief Abstracts	12
Five Detailed Histories	26
SERIES B. Inoperable Failures. 67 Cases	38
Table I. 67 Cases Abstracted	38
Three Detailed Histories	50
SERIES C. Operable Successes. 35 Cases	53
Brief Abstracts	53
Two Detailed Histories	59
SERIES D. Operable Failures. 14 Cases	61
Brief Abstracts	61
One Detailed History	64
SUMMARY AND CONCLUSIONS	65
APPENDIX	66
BIBLIOGRAPHY	72

SARCOMA OF THE SOFT TISSUES, OTHER THAN LYMPHOSARCOMA, TREATED BY TOXIN THERAPY.

*END-RESULTS IN 186 DETERMINATE CASES WITH MICROSCOPIC
CONFIRMATION OF DIAGNOSIS. 49 OPERABLE, 137 INOPERABLE.*

Much has been said of the phenomenon of "spontaneous" regression of cancer. It has different meaning for different authors. Everson and Cole (1956) have defined a spontaneous regression of cancer as the partial or complete disappearance of a malignant tumor in the absence of all treatment, or in the presence of therapy which is considered inadequate to exert a significant influence on neoplastic disease.

If such regressions were truly spontaneous, one could learn nothing from them. They would simply be noted as esoteric phenomena and would evoke no further discussion. It happens, however, that the regressions reported in the literature are not truly spontaneous, but are almost always associated with certain unusual circumstances such as acute concurrent infection, inflammation, fever or bacterial toxin therapy. If a common denominator could be found in these cases, a first step in the solution of a giant riddle might be made.

The purpose of this review is to analyze the effect of bacterial toxin therapy on patients with sarcoma of the soft tissues (the data relating to the effect of infections on all types of neoplasia will appear in a subsequent report). It is hoped that the analysis of factors influencing success and failure in the following 186 cases will lead to more effective use of the method and to greater knowledge regarding this form of therapy and its effects on patients.

Before the remarkable discoveries of Pasteur and Koch, medical research centered upon the effects of "constitution" and "disposition" in pathological processes. With the advent of bacteriology, the reaction of the host was hardly considered in the development of a disease. However, with the development of the science of immunology, the pendulum once more is swinging in the direction of "resistance of the host", even in the field of neoplastic diseases.

The treatment of malignant tumors by infections of bacterial products is based on approximately 300 recorded cases of so-called "spontaneous" regressions, the great majority of which occurred in patients who concurrently developed an acute infection, principally streptococcal.

Most of these were cases of carcinoma or epithelioma. However, about 20 *inoperable sarcomas of the soft tissues* (other than lymphosarcoma) were found that disappeared completely under the influence of acute infections. Of the five recorded cases of *untreated operable* neoplasms in which infections developed and the tumors disappeared completely, only one was a sarcoma, in an 18-month-old child, whose parents had refused amputation for an extensive tumor of the

thigh. A severe pyocyanous infection developed in the biopsy wound. The tumor then disappeared and the patient remained free from further evidence of disease when last traced 23 years later (Muller, 1921). Of the 47 *operable* cases in which infection developed spontaneously before or after surgical removal, four were sarcoma of the soft tissues. These four patients remained free from further evidence of disease when last traced 8 to 21 years after onset.

The present report consists of all the microscopically proven cases of operable and inoperable sarcoma of the soft tissues, other than lymphosarcoma, in which toxin therapy (Coley toxins) was administered. The cases have been grouped according to the stage of the disease when toxins were begun, and the type of toxin used. Nine of the cases in the inoperable successes were reported in detail in the review of Nauts, Fowler and Bogatko (1953, as cases 1, 2, 3, 4, 8, 20, 23 & 28). All the detailed histories of the 186 cases briefly abstracted in the present report are available for study at the New York Cancer Research Institute, 1290 Madison Avenue, New York 28, N. Y. A few complete histories are included here because they illustrate certain points discussed in the text.

As to how acute infection, acute inflammation, fever or bacterial toxin therapy may exert their apparently beneficial effects on patients with cancer, it is known that neoplastic cells are more sensitive to heat than normal cells (Lambert, 1912). In addition to this, it appears that infections or their toxins may activate or mobilize various cells, tissues or systems in the body which affect tumor immunity, and which may not be functioning normally in cancer patients.

The lymphocyte was first suggested as playing a role in resistance to neoplastic diseases by Murphy and his co-workers, who, as early as 1914, were able to break down the resistance of animals to heterologous tumor transplants by destroying lymphocytes with irradiation or benzol (Murphy, 1926). More recent investigators, such as Toolan (1951), using the irradiation technic of Murphy, succeeded for the first time in propagating malignant human neoplasms in laboratory animals. Thus, while it is apparent that lymphocytes are concerned in maintaining resistance against heterologous tumors, and that radiation destroys both the lymphocyte and the resistance, the precise mechanism of action still remains undetermined.

The possible role of the reticulo-endothelial system (RES) in resistance to neoplastic disease is now beginning to be considered as its function in various physiological processes becomes more clearly defined. The RES is composed of cells scattered throughout the body which are actively phagocytic toward particulate matter, or can be stimulated to assume that function. Such elements are ranged anatomically in two ways: fixed reticulo-endothelial cells which are attached to and form an integral part of sinusoidal walls, and free reticulo-endothelial cells which wander through the tissue spaces. Fixed phagocytes and potentially phagocytic elements line the sinusoids of the liver, spleen, lymph nodes, suprarenal glands and the bone marrow. Free reticulo-endothelial cells multiply rapidly during periods of greater need and become phagocytic whenever particulate matter comes into direct contact with their cell membranes under conditions which make phagocytosis possible. It is possible that the RES plays a role in disposing of carcinogens circulating in the blood, before they can exert their deleterious effects.

The acute inflammatory reaction is another important factor in the host's resistance to neoplastic diseases (Southam & Pillemer, 1957). The implantation of cancer cells into normal volunteers elicited a marked local inflammatory reaction and rapid rejection of the transplant. In patients with advanced cancer the initial inflammatory reaction was minimal and growth of the implanted cells occurred at almost all sites.

It may be significant that the histamine liberated by acute inflammation appears to be a physiological activator of the reticulo-endothelial system (Jancso, 1947). It is well to remember that an erysipelas infection, in addition to the fever it invokes and the toxins it produces, is accompanied by the most acute inflammatory reaction of any type of infection. By far the largest number of dramatic regressions of inoperable cancer occurred in the patients who developed erysipelas. Was this due to the fact that these patients were still able to elicit a profound inflammatory reaction to their infections, or merely to the fact that they were lucky enough to contract this type of infection?

Southam and Pillemer (1957) found that none of the factors which are thought to be related to body defense mechanisms were demonstrably deficient in the 17 cancer patients they tested, except for properdin. Properdin is a euglobulin in the blood serum, discovered by Pillemer in 1953, which in the presence of complement and magnesium inactivates bacteria and viruses. The properdin system may play a role in cancer resistance. A single small injection of bacterial polysaccharides appears to stimulate the production of properdin while x-ray inactivates it. It was also found that the administration to mice of polysaccharides from normal and neoplastic tissues can depress serum properdin levels. This suggested to Southam and Pillemer (1957) that a large mass of cancer tissue may of itself absorb properdin or liberate into the circulation tissue polysaccharides which combine with properdin, thus depressing properdin levels.

The following factors influencing prognosis in cases treated by toxin therapy (Coley toxins) seem of importance.

1. *The stage of the disease when toxin therapy is begun* (see Fig. 2): A high percentage of permanent results — 67% — was obtained in primary inoperable patients who had not developed metastases. Of the recurrent inoperable cases, 50% were successfully treated, but only 28% when metastases were present. Metastases appear to affect prognosis much more than cachexia or "poor general condition" does. Every patient in the operable group receiving adequate toxin therapy remained free from recurrence five years or more.

2. *Other treatment given prior to toxins*: Cases in which three or more surgical operations had been performed, or in which heavy, prolonged radiation had been administered prior to the toxins, did not respond nearly as well to subsequent toxins, regardless of whether they were operable or inoperable when the toxins were begun.

3. *Age and sex of the patient*: The highest percentage of successes occurred in females between 10 and 20, and 50 and 60 years of age, the lowest in males between 40 and 50 years of age (see Fig. 2). Taking all males regardless of age, only 40% were successfully treated, as compared to 59% of the females. It would appear that the majority of the males between 20 and 50 received less prolonged toxin therapy because of their desire to return to work, while this

factor did not play a part for most of the females. However, another point may be considered: most physicians gave the same dosage to females as they did to males, although males weigh more than females. This would mean that the females got a slightly larger dose per pound of body weight than did the males.

4. *The type of toxin used* (See Fig. 1): It is now apparent that Buxton's V and VI and Tracy's X and XI were the most potent and least variable preparations available during the period covered by this study, 1892-1955 (Nauts, *et al*, 1946, 1953). It is not surprising, therefore, to find that the highest percentage of results were obtained in patients treated with these preparations. (A considerable number of letters and reports are on file in the office of the New York Cancer Research Institute relating to the comparative weakness of the commercial preparations and the greater potency of the Buxton and Tracy products.)

5. *Duration of toxin therapy* (See Fig. 3): This factor appears to be of great significance in treating the inoperable cases, or when using a less potent preparation. Occasionally a permanent result was obtained with the weaker preparations if they were given persistently, in adequate dosage to produce the desired reaction, and begun before metastases were present. Among the operable cases the majority of successful results were obtained in cases treated six weeks to nine months. In the inoperable cases the optimum duration appeared to be from six to twelve months. It is important to note that if recurrence or metastases developed following a brief period of toxin therapy, a permanent result was finally obtained if the toxins were promptly resumed and given persistently. For example see cases 14, 23, 39, 41, 56, 57, 66 and 67 in the inoperable successes, and cases 12, 16, 21, 22 and 26 in the operable successes.

6. *Type of reaction elicited and site of injection* (see Fig. 4): Reactions were more marked, less prolonged, and better tolerated by the patients when injections were given in or near the tumors or intravenously in sufficient doses to produce marked reactions with chills and temperatures of 101° to 104° F. or more. The highest percentage of successful results in the inoperable cases occurred in cases that had this type of reaction. In the operable series the results varied only slightly as regards the cases receiving injections in or near the cicatrix or tumor, intramuscularly remote from the tumor, or a combination of these two routes.

Several surgeons who described the technic they used advised injections in the vicinity of the growth and gradually into the tumor itself; these include Coley, Matagne, Odier and Wyeth (who also used living cultures of streptococcus injected into the wound following surgical removal of sarcomas). If tumors were inaccessible, that is, in the abdominal cavity or pelvis, they advised injections in the gluteal region or in the abdominal wall in the immediate vicinity of the neoplasm.

7. *Frequency of the injections*: The majority of the successful results had injections every 24 to 48 hours during the first part of the treatment.

Effects of Toxin Therapy on Normal Tissues or Organs:

A careful analysis of all the cases of sarcoma of the soft tissues and of about 800 cases of other types of neoplasms in which the toxins were used indicates that Coley Toxins produced no deleterious effects on normal tissues or on the kidneys, heart, liver or other organs. One patient with chronic Bright's disease responded satisfactorily to the toxins without any ill effects on her diseased kidneys (Case 30, inoperable successes).

Stimulus to wound healing and regeneration of bone: Many surgeons noted remarkably rapid wound healing in patients who were receiving toxin therapy. Others noted that large areas of bone which had been destroyed by the neoplasm regenerated completely. Most of the latter occurred in the bone sarcoma cases (see case 63, inoperable successes, for an example in the soft tissue group. This patient had had parts of two ribs resected at the time of the exploratory operation).

Pain Relief: A great many surgeons noted that there was marked relief of pain occurring almost immediately after the injections were begun. In a few cases pain returned as soon as the toxins were stopped temporarily, and again disappeared when they were resumed. Patients requiring large doses of narcotics were able to stop taking them. Pain relief occurred even in patients who were too far advanced to respond markedly to toxin therapy, and who were not ultimately cured. This suggests that toxin therapy may be of value as a palliative in such cases.

Cessation of Hemorrhages: A few physicians noted that patients in whom hemorrhages had occurred prior to toxins ceased hemorrhaging when the toxins were administered. (Note: in two far-advanced cases, necrosis of the tumor following toxins caused fatal hemorrhage from a vessel in the growth).

Stimulation of hematopoietic tissues: There are a few histories which suggest that the toxins may stimulate the hematopoietic tissues (for an example see case 63, inoperable successes). This effect is sometimes masked by the fact that absorption of large quantities of necrotic tumor tissues may produce anemia.

Effects on Concurrent Pregnancy, and Fetus: Only three pregnant women are known to have received Coley toxins during their pregnancy. The first was case 12, inoperable successes. She was given intramuscular injections during the second trimester, followed by complete regression of the sarcoma. A normal child was born at full term. A second patient with very far-advanced malignant melanoma also received the toxins intramuscularly during the latter half of her pregnancy, with marked palliation as regards pain relief, improved sleep, etc., and some evidence of temporary arrest of the extensive growths. Her child was also born at about full term (labor was induced), and was entirely normal. The third case, a reticulum cell sarcoma of the humerus, was given a fairly large initial dose intravenously in the sixth month of her pregnancy. This caused a very marked reaction: the temperature reached 105.4° F. within two hours, preceded by a severe chill which began immediately after the injection. An abortion occurred a few hours later. The toxins were resumed nine days after abortion and given concurrently with x-ray therapy (2,000 r.) followed by complete regression of the tumor. This patient was seen alive and free from disease 12 years later.

Dangers of Toxin Therapy:

The available evidence suggests that Coley toxins are without harmful or dangerous effects to patients or animals suffering from various type of neoplasms, provided these toxins are administered properly as to dosage, site and the usual aseptic precautions. They should not be given to patients with severe hepatic insufficiency due to metastatic disease or other pathology, nor to patients who have had severe heart conditions, nor to patients who are almost moribund, because such patients do not respond. It is not even possible to elicit the desired febrile reactions.

Current research on Toxin Therapy: During the past five years the New York Cancer Research Institute has been investigating various factors which appear to stimulate the natural resistance of patients or animals to neoplastic diseases. In this connection, the apparently beneficial effects of bacterial products (Coley toxins) are being evaluated.

The Institute's major laboratory and clinical project is being done at New York University — Bellevue Medical Center. The first objective was to obtain a bacterial product which would be more potent as regards the tumor destructive properties, without being more toxic to the patient or animal. Over one hundred different variations in formulae were tested, using virulent, freshly-isolated strains of streptococcus, combined with *Serratia marcescens*. The most effective of these, based on extensive experiments on animal tumors, is being administered to patients with advanced inoperable cancer and to certain patients before and after operation as a prophylactic to prevent recurrence. This potent preparation, developed by Dr. Barbara Johnston, Research Director of the New York Cancer Research Institute, is available for treatment of patients by physicians who have used toxin therapy in the past, or who are now beginning long-term research on this form of therapy. Directions for their administration are available. One of the objectives of our Institute has been to act as a center of information regarding the possibilities and limitations of toxin therapy. Thus we have stimulated and helped other investigators to begin serious evaluation of this method by supplying them with formulae, data, etc. The first of these studies to be reported is that of Drs. Havas and Donnelly in *Cancer Research*, February, 1958. (48a, 59a).

The analysis of the inoperable successes and failures may be helpful in evaluating some of the points just discussed and will be found on page 65, in the Appendix. For a more graphic picture of most of these factors see Figures 1-6 immediately following this introduction.

Brief abstracts of all the cases are presented in four series:

Series A: 70 inoperable successes

Series B: 67 inoperable failures

Series C: 35 operable successes

Series D: 14 operable failures

(The decision as to whether a case was operable or inoperable in these 186 cases was made by the attending surgeon at the time the toxins were begun. It is recognized that such a distinction is occasionally difficult to make).

The references are given after each case abstract or detailed history and are listed in the bibliography.

FIG. 1.

END RESULTS ACCORDING TO TYPE OF TOXIN

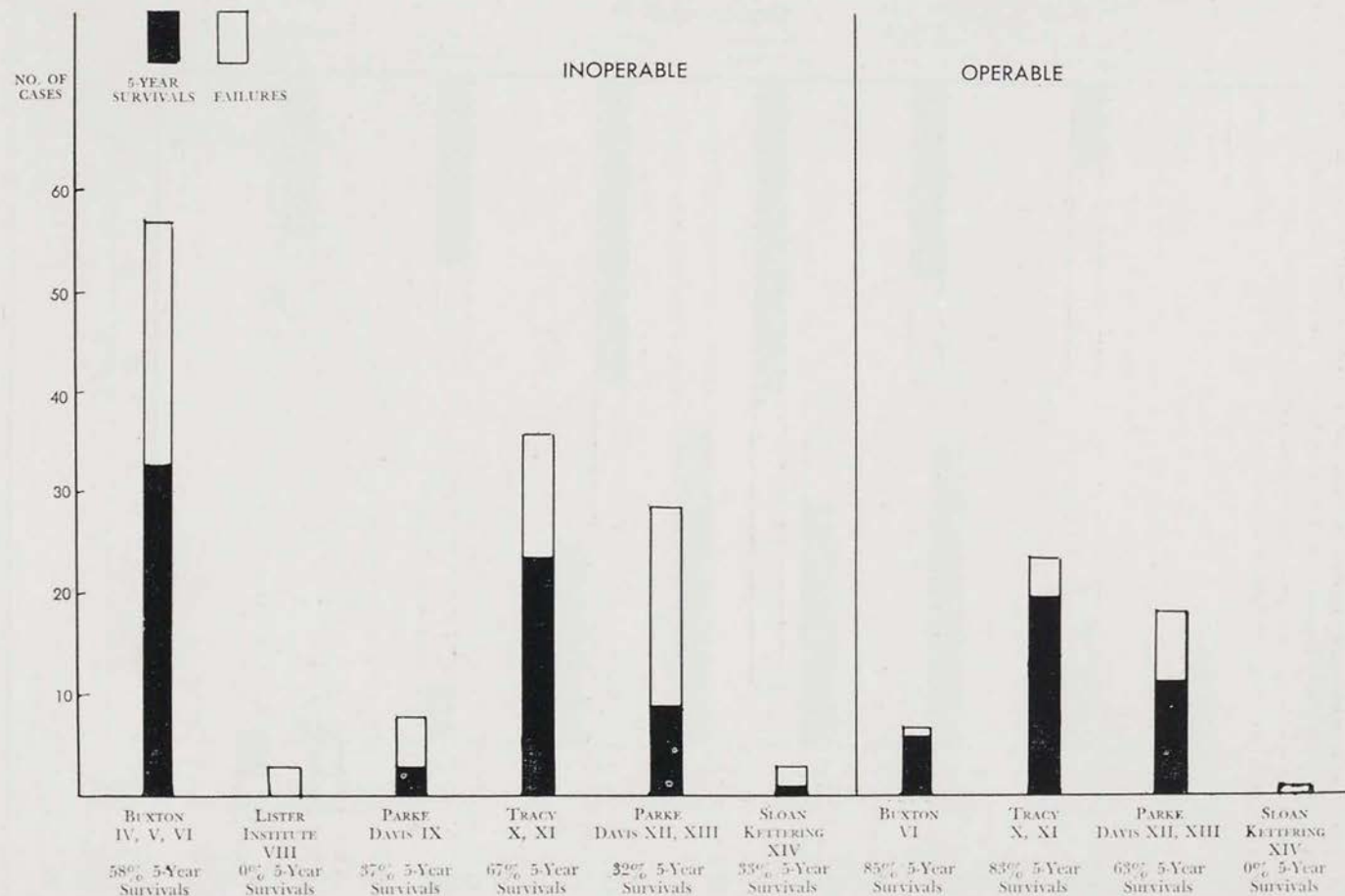


FIG. 2 END RESULTS ACCORDING TO STAGE OF DISEASE WHEN TOXIN THERAPY WAS BEGUN

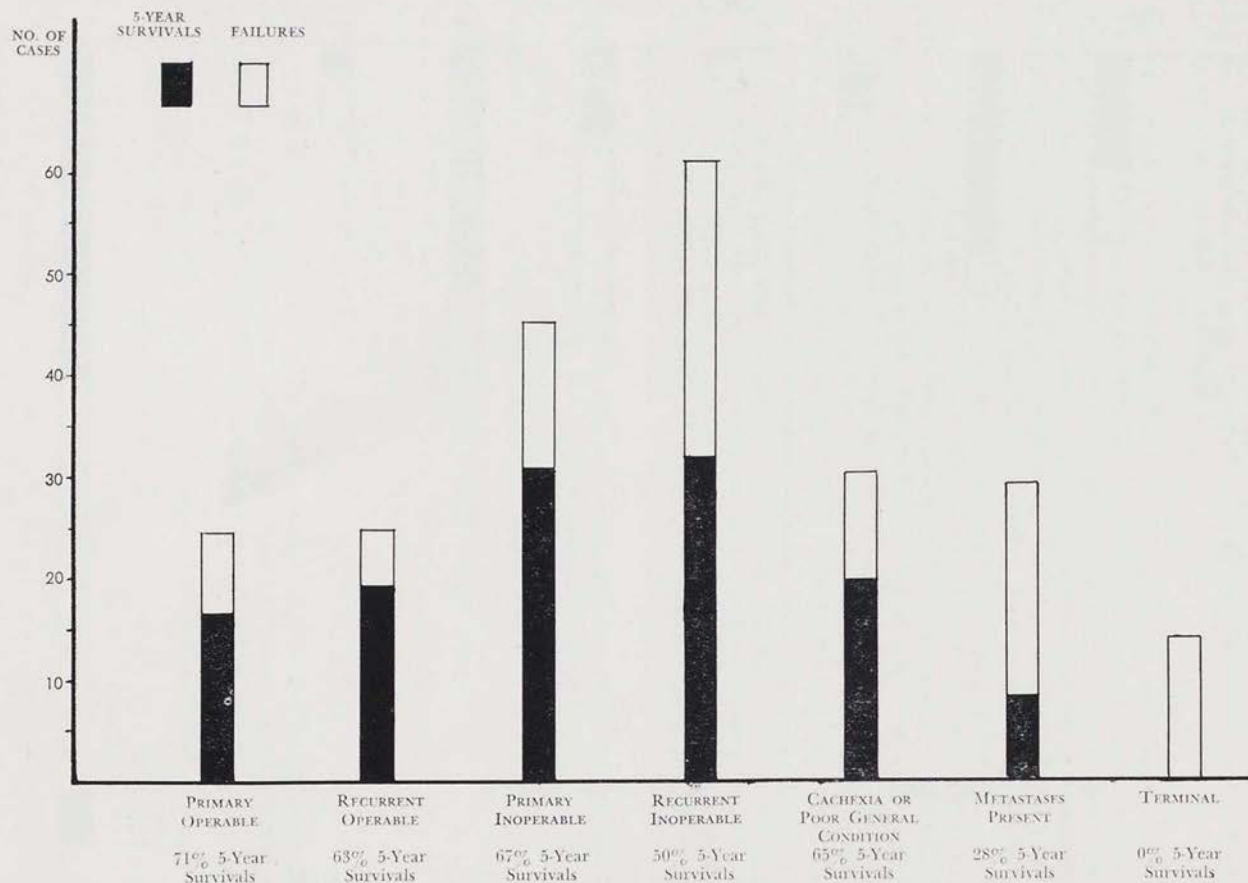
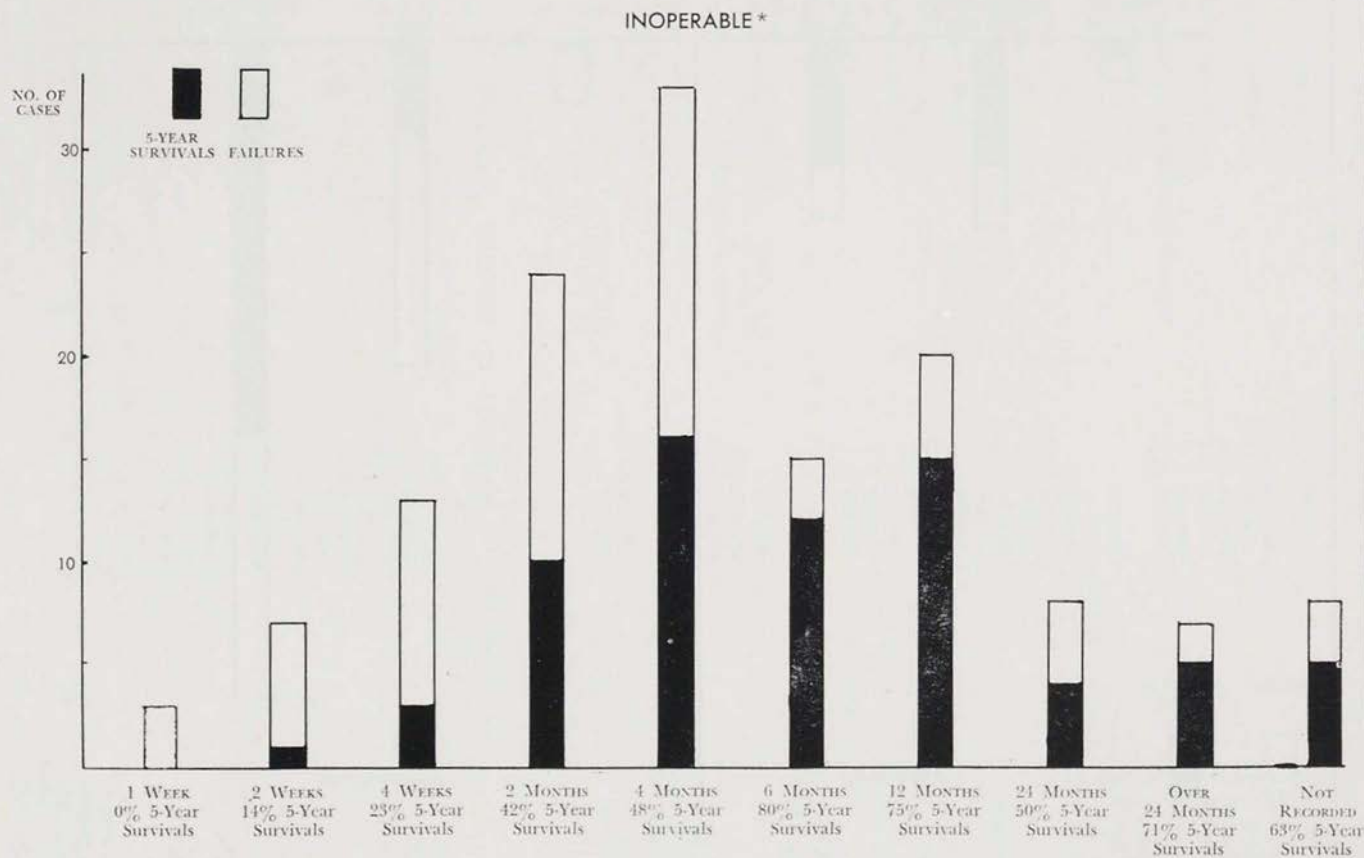


FIG. 3.

END RESULTS ACCORDING TO DURATION OF TOXIN THERAPY



* THE MAJORITY OF THE OPERABLE 5-YEAR SURVIVALS RECEIVED TOXIN THERAPY FOR FROM 6 WEEKS TO 9 MONTHS.

FIG. 4. END RESULTS ACCORDING TO REACTION ELICITED

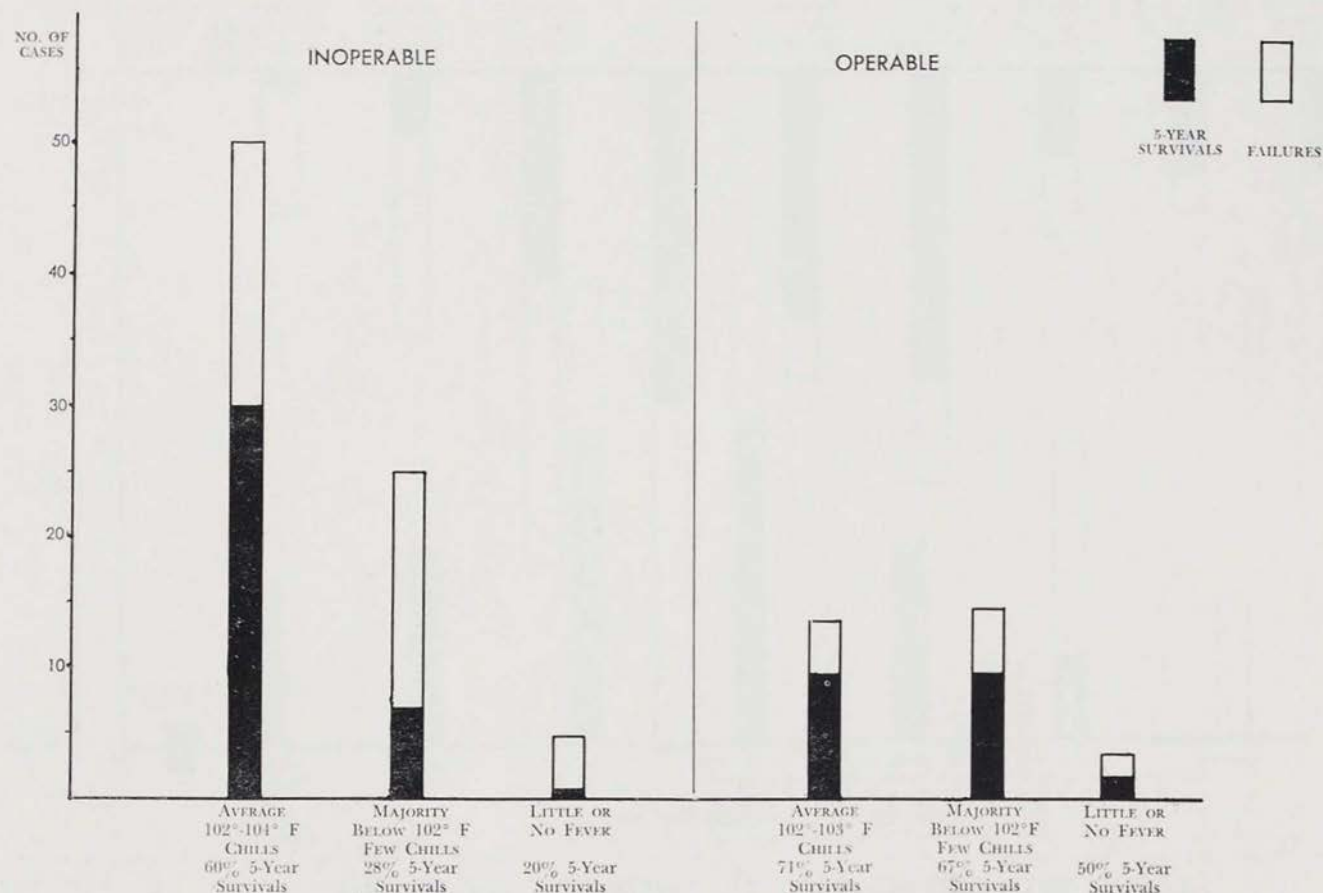


FIGURE 5. END-RESULTS AS REGARDS TYPE OF TUMOR:

<i>Type of Tumors</i>	<i>Inoperable</i>	<i>Operable</i>
Spindle cell sarcoma	{ 20 successes 17 failures	{ 5 successes 2 failures
Round cell sarcoma	{ 18 successes 17 failures	{ 6 successes 4 failures
Mixed round and spindle cell sarcoma	{ 5 successes 6 failures	3 successes
Alveolar sarcoma		1 success
Fibrosarcoma	{ (1 was neurofibrosarcoma) 7 successes 5 failures	{ 5 successes 3 failures
Fibroangioma	1 success	
Fibromyosarcoma	1 success	
Myxosarcoma	{ 1 success 4 failures	4 successes
Angiomyxosarcoma	1 failure	
Angiosarcoma	{ 4 successes 1 failure	
Hemangioendothelioma	1 success	
Endothelioma	{ 1 success 2 failures	
Reticulum cell sarcoma	{ 1 success 1 failure	1 failure
Synovioma		1 success
Mycloid sarcoma	1 failure	
Leiomyosarcoma and malignant myoma	{ 2 successes 2 failures	
Neurogenic sarcoma		{ 4 successes 2 failures 1 failure
Polyhedral cell sarcoma		
Desmoid sarcoma	1 success	
Sarcoma, unclassified	8 successes	8 successes

FIGURE 6. END-RESULTS ACCORDING TO SITE OF TUMOR:

Intra-abdominal }	{ 20 successes	{ 4 successes
Abdominal wall }	{ 6 failures	{ 1 failure
Uterus	{ 5 successes 4 failures	
Ovary	{ 4 successes 4 failures	
Kidney	2 successes	
Colon, intestines	1 failure	1 success
Breast	{ 2 successes 3 failures	4 successes
Head & Neck	{ 15 successes 16 failures	5 successes
Parotid	{ 3 successes 2 failures	{ 1 success 1 failure
Mediastinum	1 success	
Muscles, tendons, fascia }	{ 17 successes	{ 20 successes
Extremities or Trunk }	{ 30 failures	{ 11 failures
Synovial membrane		1 success
Primary unknown (metastases generalized over entire body, hemangioendotheliomata) }	1 success	

SERIES A. INOPERABLE SARCOMA OF THE SOFT TISSUES OTHER
THAN MALIGNANT LYMPHOMA SUCCESSFULLY TREATED
BY COLEY TOXINS: 70 CASES

Diagnosis confirmed by histological examination in each case.
Bibliography reference number follows each summary.
Cases are listed chronologically according to type of toxin used
and date of first injection.

NOTE: The following 10 cases received the filtered
preparations known as Type IV or V. (For a brief
description of the various formulae used see our ear-
lier publications 77, 80).

*Years Traced
After Onset*

1. COLEY: J. F. F., male, aged 16; inoperable spindle cell sarcoma entire thickness abdominal wall, attached to pelvis, involving bladder wall, measuring 5" by 6½"; general condition poor, micturition involuntary; confined to bed most of time; (onset 10/92); 1/24/93: toxins injected into tumor for six months; *steady decrease in size which continued after toxins stopped; complete regression*; no recurrence; in perfect health; sudden death 2/28/19, chronic myocarditis, 26 years after onset. First case of any type of cancer to receive Coley's *mixed* toxins. (References: 9, 11, 12, 21, 22, 29, 41, 73, 80, 102). 26
2. COLEY: W. S. G., male, aged 15; twice recurrent inoperable angiosarcoma nasal septum, nasopharynx (onset 7/91); tumor removed by Abbe, promptly recurred; Abbe again operated taking away most of left superior maxilla; again prompt recurrence of considerable size; two electrolytic treatments (unsuccessful); 6/93: toxins in region of tumor; marked reactions, *uninterrupted improvement*; tumor *completely disappeared*; no further recurrence; remained in good health, married, had 5 children; developed small epithelioma on back of neck, excised 1950; died severe heart attack 1/15/51, aged 75. (41, 42, 73, 81). 59½
3. COLEY: Mrs. E. J. L., aged 29; extensive inoperable fibrosarcoma abdominal wall filling lower left quadrant; cachexia; (onset 4/93); exploratory operation; no attempt at removal (small piece removed for biopsy); prognosis grave; 10/93: toxins given directly into tumor daily, causing inflammation; large doses, febrile reactions 101-102° F.; *improvement evident in 2 weeks; complete regression* in 4 months; no recurrence; died heart failure 1918. (12, 13, 14, 29, 41, 80, 89). 25
4. JOHNSON: T. C., male, aged 16; inoperable spindle cell sarcoma involv-

- ing tonsils, palate, roof of mouth, nasopharynx, pillars of fauces, part of pharyngeal wall, whole base of tongue, epiglottis, upper larynx; uvula entirely destroyed, cervical glands enlarged; patient had lost much weight, strength; deglutition difficult, nasal breathing impossible; prognosis hopeless; (onset early 1893); untreated; 10/31/93: toxins given 8 months intramuscularly (legs, arms); reactions 99° to 103° F., *steady slow improvement, deglutition easy in 2 weeks; extensive growth completely disappeared, partly by absorption, partly by necrosis*; gained 22 pounds, stronger; no recurrence; alive and in very good health June 1915; not traced thereafter. (12, 24, 31, 41). 22
5. COLEY: Miss M. L., aged 35; inoperable retroperitoneal round cell sarcoma apparently recurrent from a primary growth in the uterus; recurrent after hysterectomy; pain in back, abdomen; (onset 1889); second operation attempted but abandoned; 1/12/94: toxins for 8 weeks intramuscularly in thigh; *considerable regression*; exploratory celiotomy, tumor still size of goose egg and inoperable; toxins resumed, given every 48 hours; *tumor did not disappear until several months after toxins were stopped*; no further recurrence; last traced 1917. (29, 41, 42, 73). 28
6. COLEY: F. K., female, aged 16; extensive infiltrating inoperable fibrosarcoma tendon sheath over metatarsal bone, recurrent in stump, leg, thigh, gluteal regions; (onset 1889); excision 1889; recurrence 3 years later; Syme's amputation; further recurrence in stump, popliteal space; also inguinal lymphadenopathy; at 3rd operation popliteal recurrence not entirely removed, stump recurrence untouched; 3/94: toxins; *complete regression*; gained 17 pounds; further recurrence in gluteal region 10/95; toxins caused *diminution*; later; mid-thigh amputation; toxins resumed, given with intervals of rest for 3 years; *no further recurrence*; in excellent health 1936. (12, 13, 14, 14a, 16, 29, 34, 35, 43 (Case 1), 73). 40
7. COLEY: Mrs. M. S., female, aged 29; very large recurrent inoperable fibrosarcoma gluteal region and thigh; (onset about 1886); surgical excision 10/91 when 4" x 6" in size; recurrence in 3 mos., became very extensive, caused much pain; prognosis hopeless; 4/7/94: toxins given locally for 3 months, dosage increased to produce marked reactions; *pain ceased but improvement very slow; growth continued to decrease after injections stopped*; 4/29/99, fibrous remains were excised, showed microscopic evidence malignancy; no further recurrence; in very good health; death 2/2/41, coronary heart disease. (11, 20, 29, 41, 44, 73, 81). 51
8. MYNTER: C. P., female, aged 12; inoperable spindle cell sarcoma involving parietal peritoneum, mesentery, pelvic organs, caecum; abdomen enormously distended, micturition involuntary; (onset about 3/94); laparotomy, 2 quarts chocolate-colored fluid escaped; specimen from soft vascular growth removed; profuse hemorrhage checked by packing; patient moribund; 7/26/94: toxins started 4 days after operation, given daily into upper thigh; no marked reactions; *immediate, steady complete regression*; (necrotic pieces tumor sloughed and evacuated through drainage tube); in good health; no recurrence June 1898; not traced

- subsequently. (No record death found 1898-1954 in Buffalo or New York Bureau of Vital Statistics). (28, 34, 77, 78). 4
9. COLEY: J. T., male, aged 32; thrice recurrent inoperable fibroangioma upper lip; (onset 1891); first operation 1892; recurrence; 2nd operation; extensive recurrence of very rapid growth followed third operation; 11/19/95: toxins (Type V) into growth; *immediate decrease, almost entire disappearance* in 3 weeks; plastic operation later to restore lip; no further recurrence; alive and well 1903. (13, 16, 41, 76a). 8
10. COLEY: M. S., female, aged 5; twice recurrent inoperable small round cell sarcoma lip; (onset 7/96, following trauma); two operations; recurrence of rapid growth, extending from mucous membrane of lip downwards 1½ inches; 2/10/97: toxins into tissue near tumor (Type V); slight reactions; *complete disappearance*; scar tissue then excised; no evidence tumor remained; toxins given one year; no further recurrence; married, had 3 children; alive and well 1958. (14a, 20, 29, 39, 81). 61½
- THE FOLLOWING 23 CASES RECEIVED BUXTON'S UNFILTERED TOXINS TYPE VI:
11. COLEY: S. C., female, aged 16; inoperable spindle cell sarcoma left scapular region (13" across); extensive involvement entire left chest wall from clavicle to costal margin; (onset 3/94); incisional biopsy 6/23/94: toxins all given into tumor; fairly marked febrile reactions; *immediate and rapid improvement; complete regression* in 9½ months, entirely by absorption; as a precaution toxins given 10 months; no recurrence; alive and well 12/13. (12, 13, 14, 18, 20, 29, 73, 80). 19½
12. McARTHUR: Mrs. D. P., female, aged 40; recurrent inoperable fibrosarcoma originating in sheath of tibial muscles, calf of leg; (onset 1891); very radical excision primary growth 3/30/94; recurrence size of walnut; patient 3½ months pregnant when toxins begun 9/28/94; *progressive improvement*, no marked reactions, no unfavorable effects on pregnancy, normal child born at full term; *complete regression*; no further recurrence; alive and well 11/12. (16, 85a). 19
13. PACKARD: Female, aged 39; recurrent inoperable spindle cell sarcoma parotid; (date of onset not given); primary growth removed 1894; recurrence within year; 8/95: toxins daily for several mos. into growth or surrounding tissues; *marked rapid regression*; growth "shrank away to an unoffending node"; further injections failed to dissipate this fibrous stroma which was dissected out; excellent healing; no further recurrence; in excellent condition 1898. (20, 41, 29, p. 152). 4½
14. COLEY & COBB: Mrs. M. D., female, aged 40; spindle cell sarcoma iliac fossa size of cocoanut, involving ilium and abdominal wall; (onset 5/95); exploratory laparotomy, specimen removed; 11/1/95: toxins by Cobb for 6 weeks; *complete regression*; extensive recurrence few months later, filled right lower quadrant; toxins resumed for 2 months by Coley causing regression to 1/5 former size; injections not given during hot weather; again recurrence; toxins resumed, continued 7 months, again

- immediate decrease in size; *complete regression*; no further recurrence; alive and well 1907. (19, 20, 24, 38, 73). 12
15. STORRS & GRISWOLD: E. E. F., female, aged 42; inoperable rapidly growing spindle cell sarcoma pectoral region and breast, rapid loss of weight and strength; (onset 10/95), tumor size of orange in two months; biopsy; 12/16/95: toxins into tumor; incision and drainage to evacuate necrotic tumor tissue; *complete regression* in 3½ months; no recurrence; in good health, married; 45 years later developed basal cell epithelioma on nose; died bronchopneumonia and arteriosclerosis, age 89, 5/2/43. (15, 16, 17, 20, 24, 29, 41, 77, 80, 102). 47½
16. NICHOLSON: Mrs. J. R. C., female, aged 47; inoperable twice recurrent spindle cell sarcoma thigh, extensive involvement inguinal glands; entire limb edematous; (date of onset not given); primary and first recurrent tumor removed surgically; further extensive recurrence; surgery not possible; 1/96: toxins every 48 hours for 2½ months, febrile reactions 101.5° to 103° F.; *complete regression recurrent tumor, inguinal involvement and edema*; alive and well 7/99, about 5 years after onset. (82a). 5
17. WILLIAMS: Mrs. E. Z., female, aged 37; recurrent inoperable spindle cell sarcoma uterus; large growth projected several inches above surface of abdomen; (onset 1895); exploratory laparotomy 3/24/96; portion removed for biopsy; 4/4/96: toxins directly into tumor; very severe reactions (high dosage for intratumoral route), poultices also applied; necrotic tumor tissue drained through sinus 2-3 inches deep in center of tumor; *steady rapid regression, complete disappearance extensive hard tumor*; no further recurrence, alive and well 1914. (20, 29, p. 151, 41). 19
18. PACKARD: E. P., female, aged 15; inoperable round cell endothelial sarcoma pelvis, (date of onset not given); exploratory laparotomy, biopsy; 5/96: toxins; *rapid local and general improvement; complete regression*; no further recurrence; alive and well 1906. (29, p. 152; 41). 10
19. PACKARD: Female, aged 55; extensive recurrent inoperable sarcoma inseparately adherent to the abdominal viscera (date of onset not given); primary tumor had been removed previously; fragments of recurrent growth removed at second laparotomy; prognosis hopeless; 5/96: toxins; *rapid local and general improvement; complete regression*; no further recurrence; alive and well 1906. (20, 23, p. 182; 29, p. 152; 41). 10
20. ROBERTS: Female, aged 18; round cell endothelial sarcoma left ovary, with many secondary nodes in adjacent viscera, ascites; (date of onset not given); exploratory laparotomy; 5/4/96: toxins begun soon after; given subcutaneously in abdominal wall steadily for several weeks; *all growths disappeared*; no recurrence or further metastases; patient later married; alive and well 1908. (16; 19; 23; 29, p. 152; 85b). 12
21. ZABRISKIE: Female, aged 43; recurrent extensive inoperable intra-abdominal sarcoma; (onset late 1895); primary growth size child's head

- when removed; large recurrence in 4 months, of rapid growth; 11/96: toxins thrice weekly for 3 months; *marked decrease in size; remained stationary for a time, then regressed completely* under continued injections (given 12 months); no further recurrence; alive and well 1908. (16; 29, p. 155). 13
22. COLEY: Mrs. B., female, aged 34; inoperable thrice recurrent mixed round and spindle cell sarcoma parotid; (date of onset not given); primary and first two recurrences removed surgically; further operation inadvisable; 1/97: toxins in small doses; *marked decrease in size; increase in mobility; most of remaining tissue easily excised under ether, found to be fibrous stroma of former growth*; toxins given another 3 months (total of 7 months); no further recurrence; last seen 1907. (17, 17a, 20, 29, p. 60). 10
23. GRINDON: Mrs. R. B., female, aged 50; recurrent inoperable spindle cell sarcoma supraclavicular region, involving thoracic wall behind 1st and 2nd ribs; (onset early 1897); incomplete operation few days after mass above left clavicle first noted; incomplete removal, prompt recurrence; mass soon exceeded its former size; general condition very poor, bed-ridden; 4/15/97: toxins, 58 injections in 6 months into tumor and vicinity; marked reactions from beginning of treatment; *complete regression* in 4 months; regained health; 3 months after last injection recurrent nodules appeared in neck, breast, axilla; toxins resumed without effect (only 6 doses in 8 weeks); several nodules excised 4/98; toxins then given more aggressively; *remaining growths sloughed, healed*; no further recurrences; died unrelated causes 1905. (31, 41, 81, 108a). 8
24. COLEY & WRIGHT: W. W. L., male, aged 40; twice recurrent inoperable spindle cell sarcoma parotid, involving submaxillary glands; onset early 1897; first operation 3/97; rapid recurrence; two more operations, third, incomplete; very rapid growth thereafter; 7/20/97: toxins by Wright for 3 weeks, little effect except some softening and sloughing of central ulcerated portions; toxins by Coley given aggressively (daily large doses); *complete disappearance in 2 mos.*; no further recurrences; in perfect health until death 11/22/03; severe hemorrhage from gastric ulcer. (15a; 16; 16a; 17; 18; 20; 29, p. 98; 102; 113a). 6
25. ROBERTS: Adult (sex not given); inoperable intra-abdominal sarcoma; (date of onset not given); exploratory laparotomy, specimen removed; 1899: toxins; *complete regression*; well and free from recurrence 10/05. Roberts had at least two other successes in similar cases. (29). 5
26. COLEY: Mr. E. S., male, aged 55; recurrent inoperable small round cell sarcoma parotid, highly malignant histologically; (onset 11/99); incomplete operation 4/5/00; prompt recurrence; 10/5/00, toxins into tumor 4 or 5 times weekly, small doses, moderate reactions, no very marked change except slight decrease in size, increase in mobility during first month's treatment; after another 2 months' treatment improvement more marked; *growth disappeared after 8 months' treatment*; no further recurrence; died 1907 of severe herpes, involving Gasserian ganglion; no evidence of recurrence at death. (17b, 18, 20, 29, p. 92). 7

27. COLEY & MEAD: Mrs. H. G. L., female, aged 40; inoperable fibrosarcoma abdominal wall, involving bladder (onset early 1900); exploratory laparotomy 12/19/00; several nodules removed for biopsy; toxins begun 5 days later, dose increased daily, given 5 months; *complete regression*; no recurrence; 23 years later developed primary carcinoma of liver, causing death 10/17/24 (no toxins given for this neoplasm). (24, 29, 73, 81, 102). 24
28. COLEY: M. J. H., female, aged 34; extensive inoperable fibrosarcoma anterior abdominal wall, filling entire right iliac fossa (6½" x 6" in diameter); patient had had pan-hysterectomy for "fibroadenoma" of uterus 8/98; onset 2 years later, pain; mass in region of cicatrix few months later; exploratory incision 4/19/01; portion excised for biopsy; 2 days later toxins, 20 doses in 1st 60 days, some in tumor, 12 of which caused adequate febrile reactions; *growth softened and decreased more than half in 8 weeks; after discontinuing toxins growth increased to former size*; became harder; toxins resumed 10/3/01 for 6½ weeks; *at first marked diminution; then no further effect*; cachexia; condition hopeless; partial removal 12/27/01; 46 x-ray treatments January to June '02; tumor increased to 15" in diameter; *had several attacks of fever, toxemia lasting few days; general health then improved considerably*; had total of 136 x-ray treatments in 849 days; *complete regression* by 5/04; gained 19 pounds; considerable skin damage, ulceration, etc., from x-rays; skin-grafting required; later x-ray cancers developed, required excision; alive and quite well at 91, 1958. (17a, 18a, 19a, 41, 73, 81, 87a). 57
29. DAVIES: A. G. W., male adult; recurrent inoperable mixed cell sarcoma neck, involving anterior border sternocleidomastoid muscle, deeper structures; (onset 7/00); primary growth excised 2/2/01; prompt recurrence; 5/4/01: toxins given about 3½ months with 4 weeks' rest between first and second course; *complete regression* during treatment; no further recurrence; in good health many years; died 11/12, of what appeared to be pulmonary tuberculosis. (29, 31, 41). 12
30. CHAPIN: Mrs. B., female adult; inoperable round cell sarcoma thoracic cavity beneath sternum; biopsy; 1/02: toxins at first every 48 hours; skin and subcutaneous tissue in upper part of *tumor necrosed, with profuse discharge necrotic tissue*; during 5th month of treatment 30 minims given once weekly; *complete regression* by 5/15/02; no harmful effects to kidneys, although patient had chronic Bright's disease; no recurrence; in better health than at any time prior to treatment; alive and well about 4 years after onset. (29, 41). 4
31. COLEY & BOYNTON: H. B. M., male, aged 56; recurrent inoperable spindle cell sarcoma triceps muscle deltoid region (onset, summer 1902); excision with some of deltoid muscle 9/02; recurrence 2/03; 2/12/93; toxins; *regression*; no further recurrence; well until death 12/25/28, at 81, of auricular fibrillation and cerebral embolus. (29, 41, 102). 26

32. COLEY: F. Q., male, aged 63; recurrent inoperable large spindle cell sarcoma cheek; (onset 1/04); excision week after onset; prompt recurrence; second attempt at removal abandoned; 3/16/04: toxins (Buxton VI & Parke Davis IX) given 3 months, also few x-ray treatments; *complete regression, cheek regained normal appearance*; no further recurrence; last seen 1910, aged 69, in good health. (29, p. 95; 73). 6
33. COLEY: W. J., male, aged 10; inoperable thrice recurrent round cell sarcoma scapular region (onset 1/02); incomplete removal 1/02; x-ray therapy; regression; recurrence, further radiation ineffective; 3rd operation, further x-ray; third recurrence 6/04; 7/01/04: toxins for one year in vicinity of scars; also further x-ray for a time; *slow, but complete regression*; no further recurrence; 20 years later developed x-ray carcinoma on left shoulder; repeated excisions, skin grafts and finally shoulder joint disarticulation failed to control it. At death, 2/4/52, 50 years after onset of sarcoma, autopsy also showed presence of bilateral bronchiolar carcinoma. (17, 17b, 18a, 19a, 20, 26, 22, 41, 73, 81). 50

The following case is the only successful result in sarcoma of the soft tissues treated by *Buxton's erysipelas and prodigious serum*. (This preparation, known as Type VII, was only made for a short time and appeared to be less effective than the *unfiltered toxins, Type VI*).

34. COLEY: Mrs. A. C., female, aged 59; inoperable thrice recurrent angiosarcoma breast; (date of onset not given); 2 excisions large ulcerated nodular growth, foul discharge, general condition very poor; 2/1/95: 51 injections serum given in several months; also 7 doses of filtered toxins (Type V); these seemed less effective than the serum; *slow decrease in size, increase in mobility; improvement in general health*; remains of growth excised 8/18/95; no further recurrence; well until death of injuries after fall downstairs, 1903; no evidence of sarcoma at this time. (13, 16, 24, 29, p. 88, 73). 8

The following three cases received the commercial preparation of Coley toxins available from 1900 to 1907 known as Parke Davis IX.

35. HUNDLEY: Mrs. A. C., female, aged 38; inoperable recurrent round and spindle cell sarcoma uterus; (onset fall 1903); growth size fetal head removed by supravaginal hysterectomy 12/03; attempt to remove cervix 1/15/04 abandoned due to weak heart; recurrence in right lateral fornix, springing from broad ligament, pelvic bone and fascia; 1/22/04: toxins, 33 doses given directly into fornix and cervix; immediate decrease in size; *complete regression*; no further recurrence; in good health until sudden death from severe duodenal ulcer, 7/32. (20, 29, p. 155; 41). 28
36. SPENCER: C. W. L., male, aged 33; inoperable spindle cell sarcoma entire lower abdomen, infiltrating peritoneum, involving rectus muscles, firmly attached to symphysis pubis; frequent micturition, progressive weight loss; (onset 10/05); exploratory laparotomy, specimen removed;

- 6 days later attempt at removal made and abandoned, due to extensive involvement; 9/22/06: toxins into tumor, sharp local and general reactions; 3 courses totalling 43 doses in 6 months; *complete regression*; no recurrence; alive and well 1912. (12, 29, 45, 80, 99, 100). 6½
37. GREEN: J. P., male, aged 20; extensive small round cell sarcoma abdominal wall, region of umbilicus, apparently originating in urachus; extremely adherent to omentum; (onset, early November 1906); very large calculus (3½ inches in diameter) removed from prostatic urethra, 3/06, followed by purulent cystitis; exploratory operation: 1/1/07: toxins, 60 doses into tumor in 5 months, causing intense local inflammation and violent systemic reactions; *complete regression*; gained 40 pounds; alive and well 1911. (29, 41, 55). 5
- The following 23 cases received Tracy's preparations of Coley toxins known as Tracy X and XI, unfiltered, or X F or XI F, filtrates.
38. MUDD: Miss C. N. J., female, aged 30; sarcoma, primary in left ovary, recurrent in abdominal wall; (date of onset not given, but was prior to fall of 1906); curettage, 11/13/06; ovariectomy 7/19/07, tumor 7" wide, almost gangrenous; rapid inoperable recurrence in abdominal wall; 8/1/07: toxins (Tracy X); *complete regressions*; no further recurrence; alive and well 1919. (33, 41, 108). 12½
39. COLEY: Miss M. L. W., female, aged 42; recurrent leiomyosarcoma (primary in uterus) following hysterectomy, filled lower pelvis, involved bladder wall, frequent painful micturition; general health bad; 10/1/07: toxins (Tracy X, XI, XI F, XII & XII F); improvement noted in 2 or 3 weeks; *marked cessation in pain, softening, decrease in size, general health improved*; toxins not given for 8 weeks during hot weather; immediate return of symptoms, increase in size of tumor; toxins resumed, given with intervals of rest for nearly 2½ years in low dosage, causing mild reactions; *complete regression*; no further recurrence; well next 35 years; died cerebral hemorrhage, hypertension at 80, 3/29/44. (26, 41, 73, 81, 102, 108). 37
40. COLEY: C. E. C., male, aged 27; inoperable metastatic round cell sarcoma, primary in muscles lower lumbar region; metastasis involving entire thickness lower jaw; (onset 9/07); primary tumor became size two fists in few weeks; excision; unhealed wound 6 x 8 inches; patient generally emaciated, unable to walk unaided; 11/19/07: toxins (Tracy X) given in gluteal muscles, also 5 doses of filtrate (Tracy X F) given into tumor of jaw; slow decrease in size, marked increase in mobility, general health improved; gained weight; toxins given 8 months; improvement more rapid after first 6 weeks' treatment; *complete regression*; no further metastasis; in good health and very active for 37 years; fall 1944, developed carcinoma at site of original growth in lumbar region, causing death 6/11/46 at 73; no toxins given for this neoplasm. (22, 24, 29, 73, 80, 81). 39

41. HOWE: Mrs. C. McM., female, aged 50; recurrent inoperable round cell sarcoma uterus, infiltrating mass filled pelvis, clinically resembled carcinoma, severe, pain, bladder symptoms; general health bad; prognosis hopeless; (date of onset not given); 4/7/08; toxins 4 times weekly; *general condition improved, pain ceased, tumor decreased steadily in size*; toxins stopped during hot weather; severe pains immediately returned; toxins resumed, given steadily; total 119 doses in 26 months; *complete regression*; no further recurrence; in good health until death, at 81, of cerebral arteriosclerosis. (10, 25, 29, 41). 28
42. RESHOWER: Mrs. S. R., female, adult; extensive recurrent round cell sarcoma involving all abdominal viscera; (date of onset not given); primary growth cleaned out of pelvis as well as possible; but all organs were involved in the adhesions; fistula remained; x-ray treatment given briefly, stopped because it caused so much dermatitis; recurrence developed, filled whole abdomen; prognosis grave; 7/7/08; toxins aggressively given for 9 months; *complete regression*; no further recurrence; alive, in excellent health 1915. (41, 81). 7
43. TOSIER: Female, aged 22; inoperable spindle cell sarcoma left ovary, involving broad ligament, uterus and intestine; (onset 10/07); exploratory laparotomy 12/08; due to extensive involvement and fear of hemorrhage only biopsy was done; prognosis hopeless; toxins begun after her return home, given daily at first; *immediate improvement; gained 60 pounds*; toxins given 10 months; periods regular; no recurrence; had second child autumn 1909, year after toxins stopped; in good health 1913. (26, 29, 41, 58, 108b). 5
44. LEACH: H. H., male, aged 33; twice recurrent inoperable spindle cell sarcoma right kidney; metastases involved intestines extensively; (date of onset not given); had been ill six months, lost 40 pounds, coughed; chest films revealed only "bronchial trouble" thought to be tuberculosis; exploratory laparotomy 5/30/08; practically solid growth weighing 13½ pounds and filling whole abdominal cavity removed; recurrence size orange 4/17/10; whole omentum removed up to stomach; metastases right side, involving intestines; exploratory incision, condition inoperable; 7/1/10; toxins, 41 doses in 60 days; *complete regression, regained 40 pounds, and former strength*; perfectly well 1916. (41, 42, 81). 6
45. DA COSTA: Female adult; huge inoperable spindle cell sarcoma thigh and groin; (date of onset not given); portion of growth removed surgically 1910; toxins begun immediately thereafter, given daily, violent reactions every day for weeks; *complete regression*; no recurrence. (45a). 4
46. HAINES: J. M., male, aged 52; inoperable round cell sarcoma right rectus, internal oblique muscles, size hen's egg, immovable; (onset prior to 4/10); exploratory operation, incomplete removal 4/25/10; 2 days later toxins begun; 3 courses in 6 months; *considerable sloughing necrotic tumor tissue; complete regression*; well and free from recurrence until death, heart attack, 1933. 22

47. HARMER: L. E. F., female, aged 46; extensive recurrent infiltrating spindle cell sarcoma antrum, ethmoid; (onset 1904); had 6 operations, recurrences; 2/19/12: toxins given for 6 weeks after 6th (incomplete) operation; *apparently remains of growth destroyed*; no further recurrence; in excellent health next 20 years; died cerebral hemorrhage, 4/16/32. (58, 59, 72, 81). 32
48. COLEY: J. C. K., male, aged 52; inoperable spindle cell sarcoma retroperitoneal region and iliac fossa; (onset 12/11); toxins given for 4 weeks, decrease in size, softening; incision, necrotic tissue evacuated; toxins resumed, given several weeks longer; *complete regression*; no recurrence; alive and well 1918. (29, 31, 42). 6
49. STEWART: D. A. D., male, aged 56; mixed cell sarcoma right groin, "decidedly malignant"; loss of strength, appetite, 15 pounds weight lost; (onset 2/1/12); inoperable; 4/12: toxins meticulously administered; *complete regression*; no recurrence; remained in excellent health over 20 years; then developed carcinoma of stomach, metastases to spine; death 9/21/34, aged 77, generalized carcinomatosis, chronic myocarditis, arteriosclerosis. (41, 72a, 102).
50. McDONALD & BURNS: M. P., female, aged 27; inoperable round cell sarcoma kidney, involving retroperitoneal glands; (onset early 1912); exploratory operation, condition inoperable; exploration revealed large retroperitoneal mass as well as mass occupying lower pole of kidney; no attempt at removal; condition absolutely hopeless 9/12; toxins (Tracy XI) intramuscularly in buttocks, reactions to 105° F.; *immediate improvement, sinuses healed; complete regression*; gained 20 pounds; well; developed multiple fibroids, requiring pan-hysterectomy 1927; no evidence of disease seen at site of former sarcoma or elsewhere; she subsequently had several operations, due to intestinal obstruction from adhesions; no evidence of disease; alive 1958, 46 years after onset. (29, 40, 41, 42, 77, 80, 108). 46
51. SHIELDS: Mrs. F. H. D., female, aged 48; inoperable myxosarcoma left tonsil, palate, submaxillary glands enlarged; tumor size hazel nut beneath left ear; (onset spring 1913); biopsy buccal tumor; 9/29/13: toxins, at first daily then every 48 hours, some into tumor; dose increased to 21 minims; *complete regression; gained 16 pounds*; in excellent health; no recurrence; sudden death pneumonia, following influenza 1918. (31, 41, 94a). 5
52. CRUIKSHANK: W. L. W., male, aged 28; large spindle cell sarcoma retroperitoneal glands; (onset about 10/13); exploratory operation; 3 months later colostomy necessary due to complete obstruction; mass extended to umbilicus; prognosis regarded as 2-3 weeks; 2/4/14: toxins into abdominal muscles; (no reactions from Parke Davis XII given first 5 days; thereafter Tracy XI given, causing marked local and general reactions); total 87 doses in 5 months; *complete regression*; no recurrence; (subsequently he and his wife had five children in 12 years);

remained in excellent health except for gall stones in 1942 (operated); and coronary thrombosis 1949; slight cerebral hemorrhage 1956, complete recovery; in excellent health 1958. (31, 41, 81).

44½

53. COLEY: J. K., male, aged 31; inoperable round cell sarcoma nasopharynx and right superior maxilla, involving ethmoid and frontal bone; (onset 4/13); neuralgic pain at sites of involvement and also in temporal and supraorbital regions, right naris occluded; weight loss; biopsy; 4/22/14: toxins intramuscularly in right chest for 5 months; *almost immediate diminution evident; complete regression in 4 months*; no recurrence; alive and well 1924. (1c, 41, 73).

10

54. COLEY & ZACHARIE: Mrs. D. B., female, aged 22; extensive inoperable fibromyxosarcoma calf, thigh and hip; possible lymphadenopathy; (onset 11/13); circumference of larger mass 28" in length by 17"; smaller tumors also present filling popliteal space; 50 pounds weight loss, general health poor; very severe pain; biopsy; 5/18/14: toxins (Tracy XI & Tracy XI F); at first in buttocks; later into growths on hip or surrounding tissues; *some decrease in size, increase in mobility; atrophic changes; no necrosis, sloughing or discharge; very little absorption; apparently toxins destroyed malignant elements without affecting fibrous stroma*; regained strength and weight very slowly; alive and well except for some hypertension, 4/57. (41, 73, 81).

43

55. WILLIAMS: Mrs. R. A. H., female, aged 56; inoperable recurrent sarcoma naris, superior maxilla; (onset fall 1913); nose cauterized; primary growth removed; recurrence; extensive 2nd operation left superior maxilla, left lower orbital plate removed; again recurred; condition believed hopeless; 9/1/14: toxins daily, 62 intramuscular injections in 6½ months (only 7 marked reactions); *tumor disappeared* in 3 months; in good health 5 years; then developed epithelioma of hard palate; 3 radium treatments 1920; disease not controlled; later extended to left naris and antrum; further palliative radiation 3/21 & 3/22; (no toxins); death 3/9/23. (29a, 41, 81).

9

56. TUHOLSKE: M. B., male, aged 28; round cell sarcoma right pharynx, nasopharynx, almost complete obstruction air; (date of onset not given); biopsy; 5/15: toxins (no effect at all from massive doses Parke Davis XII given intramuscularly, remote from tumor; 1st dose Tracy XI caused violent reactions, chills, high fever, necrosis in center of tumor; *complete regression in 6 weeks*; left hospital feeling perfect; few months later recurrence opposite side pharynx, abducens nerve paralysis (metastasis in region of hypothalamus); daily intramuscular injections in arms for week; no reactions or effect on tumor; then injections given in thighs, abdominal wall alternately; marked febrile reactions, causing *rapid complete regression* except for nerve paralysis; toxins stopped last week of January 1916; patient began to vomit 1/25/16; very drowsy, in coma 3½ weeks, weight reduced to 89 pounds; then began to improve, gained 28 pounds in 7 weeks; *complete regression cerebral metastasis*, speech and sight normal; nerve paralysis subsided; however, symptoms

of eunuchism apparent when he came out of coma; no further recurrence or metastases; remained in good health; developed mild hypertension 1942; slight hemiplegia 1945; moderate arteriosclerosis 1946; died coronary occlusion and arteriosclerotic heart disease 11/23/48, aged 63 (detailed history deserves study, see 80, case 23). (41, 42, 80, 81).

33

57. FOLLANSBEE: Mrs. D. M. W., female, aged 23; recurrent small round cell sarcoma gluteus maximus muscle; (onset 2/13); motion hip joint steadily diminished; tumor grew slowly until after birth of child 10/10/15; lost 35 pounds; severe pain; surgical removal (tumor weight 24 oz.); prompt recurrence size egg; 2/2/16; toxins (Tracy X & XI); first dose into tumor, later in region of growth; *complete regression in 3 weeks*; toxins stopped for 1 week; prompt recurrence on inner thigh (adductor muscles); toxins resumed given into tumor daily; tumor continued to increase (to size of grapefruit) *then broke down, discharged necrotic tumor tissue; disappeared completely* under toxin therapy (given 8 months); patient had 4 more children; 1956: developed ulcerative colitis, peritonitis, operated; seriously ill, but recovered; alive and free from any evidence sarcoma 3/58. Detailed history deserves study, see 80, case 24. (41, 73, 80, 81).

45

58. DONALDSON: Female, aged about 20; recurrent inoperable sarcoma of scalp (date of onset not given); primary tumor excised; local recurrence; 1918: toxins for 2½ months directly into tumor; little febrile reaction; *complete regression*; no further recurrence; alive and well 1943. (81).

25

59. MACLEAN: Male, aged 2; recurrent rapidly growing angiosarcoma right cheek; (date of onset not given); primary excised; prompt recurrence; 1918: toxins for 2½ months directly into tumor; little febrile reaction; *complete regression*; no further recurrence; alive and well 1943. (81).

25

60. CALKINS: Mrs. M. M., female, aged 26; inoperable mixed cell sarcoma ovary, extensive involvement intestines, pelvis; (onset 9/19); exploratory operation 1/29/20; findings: large degenerated sarcoma right ovary, double hydrosalpinx, degenerated dermoid cyst left ovary, large cauliflower masses between tumor, cecum, sigmoid flexure and rectum; appendix size of large cucumber; bilateral salpingo-oophorectomy, panhysterectomy, appendectomy; impossible to remove areas of involved intestine; toxins begun 1 week after operation; given steadily for 12 months; *complete regression metastatic growths*; no further recurrence or metastases; alive and well (in excellent health) 1927. (5, 41, 42, 81).

7

The following 9 cases were treated by the commercial preparations of Coley's toxins available from early 1907 to 1950, known as Parke Davis XII & XIII. (See Nauts, *et al*, 77, 80 regarding the comparative weakness of these products.)

61. PILCHER: Male, aged 55; inoperable round cell sarcoma abdominal wall; (date of onset not given); exploratory operation, specimen removed; 8/08: toxins for 4 months; *gradual complete disappearance; gained 20 pounds*; well and free from recurrence 1914. (29, p. 165; 41). 6
62. OCHSNER: Mrs. V. H., female, aged 17; inoperable small round cell sarcoma axilla; (onset 2/10); extensive operation 3/11/10; mass size grapefruit excised but involved some areas could not be completely removed as axillary nerves and vessels were completely surrounded; 3/26/10: toxins into deltoid, febrile reactions 102°-105° F.; continued 6 months; *remains of growth regressed completely*; no recurrence; married, had 3 children; alive and in excellent health 1946. (81). 36
63. POLLAK: P. H., female, aged 22 months; inoperable angiosarcoma mediastinum, causing pressure erosion spine and ribs, paralysis both legs; (onset at 5 months, 12/22); child suddenly stopped walking at 21 mos., total inability to stand due to paresis both legs; mass between scapula and spine; anemia; Lilienthal operated 4/15/24; removed portion of tumor; condition hopeless; 4/25/24: toxins in gluteal muscles daily for 11 days, severe reactions (to 106° F.); extraordinary healing of operation wound; anemia became worse, then blood picture rapidly improved; began walking 3 weeks after 1st injection (relief apparently due to decompression); developed severe pertussis, severe measles and bronchitis in next few months; *complete regression remains of tumor*; resected ribs regenerated; married; had 2 children; alive and well 1958. (53, 67, 76, 80 (Case 28), 81). 36
64. BLUM: Mrs. E. A., female, aged 37; malignant myoma of uterus weighing 15 pounds, removed surgically, (onset 1923); x-ray examination indicated extensive bone metastases to femur, sacrum, skull; anemia, poor condition; 7/21/27: toxins in large doses; *complete recovery; gained weight, strength*, no recurrence or further evidence skeletal metastases; alive and well 1933. (6, 35a, 41, 67, 76). 6
65. CRAWFORD: L. V. McH., male, aged 26; recurrent reticulum cell sarcoma, primary in bicipital region; with metastases in axilla and abdominal wall; (onset 11/27); primary excised 2/28; recurrence under left arm month later; biopsy; 1 x-ray treatment; 5/29/28: toxins given over 5 years with intervals of rest; *at first further metastatic nodules developed, but regressed completely under continued treatment*; no further metastases after fall 1931; in excellent health except for appendectomy 1952; alive and well 3/26/58. (41, 81). 30½
66. FOWLER: C. S., female, aged 21; inoperable neurofibrosarcoma popliteal space; (onset 2/29); exploratory operation 5/14/29; removal impossible due to involvement of vessels and nerves; 2 specimens removed; 5/26/29: toxins; *tumor disappeared in 5 or 6 weeks*; evidence of recurrence; toxins resumed, given with intervals of rest for 6 years; *complete regression*; no further recurrence; patient married, said to have had a child; alive and well 1945. (81). 16

67. BURKE: H. R., female, aged 19; terminal sarcoma neck, face, submaxillary region involving bones, subcutaneous tissues, especially the forehead, parietal regions, left cheek, and jaw; (onset 3/31, hard nodular mass in neck below angle right jaw); incision; x-ray caused no relief; tracheotomy for edema of glottis; radium given, without help; developed bilateral chronic mastoid, operation 1/28/32; radium again; marked exophthalmos both eyes; morphine required; 6/12/32: toxins intramuscularly *caused improvement*, but were stopped due to painful indurations; recurrence; x-ray given; recent recurrent nodules disappeared leaving mass in right submaxillary region and submental region; extensive mass in floor of mouth; further toxins — 2 more courses intravenously, marked reactions; *all tumor masses disappeared, part of tongue sloughed*; patient made complete recovery; married, had 2 children; alive and well 1958. (41, 81). 27
68. COLEY: N. P., female, aged 26; inoperable retroperitoneal sarcoma, unclassified; firm mass filled whole left lower abdomen and pelvis; clinically regarded as neuroblastoma, myosarcoma or liposarcoma; (onset 1928); needle biopsy; traction to leg; local applications; *diathermy, physiotherapy; recovered full use of limb; well 5 years*; pain recurred; exploratory operation; pain increased; large bulging mass arising from pelvis extending almost to mid-axillary line in flank filling lower right quadrant to umbilicus (27 cm. in diameter); x-rays indicated upper anterior half of right ilium was involved, due apparently to external pressure erosion; x-ray therapy; apparent complete regression in 3 mos.; 6/3/35: toxins 20 in 28 days, first 11 i.m., next 7 i.v., last 2 i.m., febrile reactions to 105° F.; gained weight, general condition improved; married, fall 1935; artificial menopause (radiation induced) 1936; menstruation again occurred 3/6/37; periods regular after 8/37; had two normal pregnancies and confinements 2/13/39 and 7/15/40; ectopic pregnancy (operation) 1945; alive and well 1957; unusual case. (73). 29
69. DODD: Mrs. Y., female, aged 52, extensive recurrent inoperable desmoid sarcoma left erector spinae muscle; onset prior to 3/36; primary growth excised 4/30/36; post-operative x-ray therapy during next 18 months did not prevent recurrence 10/36 or control it; another excision attempted 11/37; skin, scapula, rib and pleura fused into homogenous mass of tumor tissue; biopsy taken; operation abandoned; further deep x-ray therapy proved ineffective; condition hopeless; huge lumpy mass; 4/2/38: toxins into shoulder muscles, continued weekly for 8 months; marked reactions; *complete regression* by absorption and sanious discharge in 20 months; second course toxins begun 1/29/40, given every other week alternating with T.A.B. vaccine to relieve causalgic pains and cause *complete resolution of scar tissue*; continued 7 months; no further pain after 8/40; alive and well 1957. (Case treated as outpatient as she had 4 children and could not afford hospitalization). (81). 21

THE FOLLOWING CASE RECEIVED TYPE XIV.

70. HASLEY: Male, aged 53; generalized hemangioendotheliomata (site of primary unknown), with lesions on hands, arms, face, head, body and

legs; onset 12/46; some bled; were painful; telangiectasia under tongue, but no bleeding from mucous membranes; penicillin, rutin and x-ray tried without benefit; 3/24/47; surgical removal of tumors on abdomen and head, some by scalpel, other by electro-desiccation; aspiration biopsy of tumor on left arm (see below for detailed history, including pathological reports); given x-ray (1200 to 1800r.) to a few lesions without apparent benefit; 4/1/47: toxins intravenously, 12 in 18 days; febrile reactions averaged 102-104° F.; *within 5 days lesions were "quite dry and were falling off, with considerably less bleeding of the irritated lesions"*; very marked regression in 8 weeks; *complete regression* all tumors; little atrophy and no telangiectasis; no evidence of disease; well 11 years; spring 1958 developed malignant melanoma on right shoulder; excisional biopsy 6/13/58; patient well, no further evidence disease 7/58.

11½

COMMENT: It is of interest to note that only nine cases in this successful series received radiation.

The following five histories, selected from series A, the inoperable successes, are given in detail because they are of special interest.

CASE 12: *Diagnosis:* Recurrent inoperable spindle cell sarcoma of the calf of the leg (fibrosarcoma), confirmed by microscopic examination following operation.

Previous History: Mrs. D. P., female, aged 40, of Chicago, Illinois. The family and early personal history was essentially negative. The patient was the mother of nine children. She was admitted to St. Luke's Hospital, Chicago, on March 28, 1894, for a small tumor on the lower third of the inner aspect of the right leg which is said to have been first noted in 1891.

Surgery: On March 30, 1894, this growth was removed by Dr. L. L. McArthur. Operation revealed a tumor springing from the muscles of the calf. Although a very radical operation was performed the patient was warned of a probable recurrence and advised to have an immediate amputation if evidence of recurrence was noted. Dr. John E. Owens stated: "The patient came under my care in April, 1894. The healing of the operative wound was very slow and unsatisfactory. On May 20 skin grafts were used. The open sore finally healed and the patient was discharged."

Clinical Course: A week after leaving the hospital, the leg grew sore and gradually became worse. The patient was readmitted on September 25, 1894, under McArthur's care. At this time there was an ulcer about three inches in diameter at the site of the operation. The edges were ragged, infiltrated and very painful at times. The leg was somewhat swollen, but the swelling for the most part disappeared when the patient lay down. There existed a recurrent tumor the size of a walnut which appeared to be closely attached to the bone or periosteum (very limited motion). As the patient was 3½ months pregnant, McArthur decided it would be wiser not to attempt amputation, but to try Coley's toxins.

Toxin Therapy: (Buxton VI) Injections were begun on September 28, 1894, the initial dose being 7 minims. The first lot of toxins was used during the first 38 days, during which time 33 injections were given in doses of 7 to 11 minims (mostly 7 or 8). No marked or even moderate febrile reaction occurred from these doses, only a mild one after the third injection on September 30 (.6 rise, vomiting and then a chill). On October 6, after nine injections, "some improvement" was noted, and on October 12, "progressive improvement" was noted. The appetite was variable. On October 12, the patient had pain on urination and passed 23 ounces. Occasionally the injections would cause some nausea or vomiting.

New Preparation of Toxins: A new lot of toxins was used, beginning November 5, and the initial dose of 2 minims was given at 8 P.M., causing a febrile reaction of 101.8° F. and a chill, but the patient felt comfortable and slept after 12 o'clock. During the next three weeks 18 injections of these toxins were given, in doses of 2 to 5 minims. They did not produce any real febrile reactions after the first dose (only slight elevations of less than a degree on two occasions). This patient received a total of about 17 cc. of the first lot of toxins during the first five weeks, and about 3½ cc. of the second batch.

Owens and McArthur, who both published this case, do not state the site used for the injections. It is believed that they were all made intramuscularly rather than into the tumor, as the majority of cases given intratumoral injections in doses of 5 to 10 minims had marked febrile reactions.

In describing the results when presenting the case before the Chicago Medical Society on December 17, 1894, Owens stated: "When we began this treatment we had a well-marked tumor, about the size of a walnut, movable in a very slight degree, so it seemed to be closely associated with the periosteum. This has disappeared and the open wound has healed without any other treatment than a protective covering." McArthur added: "This was undoubtedly to my mind a growth from the sheath of the tibial muscles of the calf of the leg. On removing it I made a crucial incision, enlarging the wound widely because I found the main growth starting from that sheath. At the time of operation I made a diagnosis from the clinical appearance as well as the microscopic appearance of a fibrosarcoma and predicted its return, no matter how radical an operation was done, and I told the patient that although I had removed it as radically as possible without taking off the leg, I expected she would have to have that done within six months, on account of recurrence. She returned with a very distinct observable growth in the cicatrix, and with the idea of having the leg removed, but in the meantime much more favorable reports having been made in regard to the toxins, this treatment was tried, with the results you see. Instead of a scar standing out three-fourths of an inch above the surrounding surface, it is now hollowed out to compensate for the loss of muscular tissue beneath the sheath."

Clinical Course: There were no unfavorable effects upon the pregnancy. The patient returned to the maternity ward at full term. There was no further recurrence of the growth. The patient was reported well and free from disease in November, 1912, over 18 years after onset.

References: 16, 85a.

CASE 28: *Diagnosis:* Extensive inoperable fibrosarcoma of the anterior abdominal wall and iliac fossa, confirmed by microscopic examination following exploratory operation

Previous History: M. J. H., female, aged 34, school teacher of Winchester, Mass. The patient's aunt had died of cancer of the uterus and her mother died 16 years previously of what was believed to be intra-abdominal cancer. One sister had a lipoma of the shoulder and an ovarian cyst. The lipoma was removed without recurrence. The patient had measles and pertussis as a child. Menses began at 13, and were regular and moderate in amount. She had always been comparatively healthy until 1894, when she had "nervous prostration." She did not entirely recover until 1896. There was no history of trauma or strain prior to onset.

Surgery: In August, 1898, she was operated upon by Dr. Booth for what was supposed to be a fibroadenoma of the uterus. A hysterectomy, double oophorectomy and salpingectomy was performed, but no microscopic examination was made of the specimen.

Clinical Course: The patient took two years to recover. In the summer of 1900 she felt pain in the lower abdomen but no evidence of tumor was apparent at this time. She first noticed a growth in the region of the cicatrix of the operation in the early winter of 1900-1901. The pain diminished as the tumor became larger. During the next few months the growth increased quite rapidly in size. She was then seen by Dr. Maurice H. Richardson who pronounced it inoperable and referred the patient to Dr. William B. Coley. She was admitted to Memorial Hospital on April 19, 1901. Physical examination on admission showed a hard, non-tender tumor the size of a cocoanut ($6'' \times 6\frac{1}{2}''$) in the lower abdomen filling up the entire right iliac fossa and extending beyond the median line on the left. The growth was firmly fixed and seemed to involve the abdominal wall.

Exploratory: An exploratory incision about $1\frac{1}{2}$ inches long was made under cocaine, and a portion of the growth which infiltrated all the muscles of the abdominal wall was removed. It was found to be a fibrosarcoma.

Toxin Therapy: (Buxton VI) Injections were begun by Coley on April 21, 1901. During the next 60 days about 20 were given in doses of 1 or 2 minims, at least 12 of which produced febrile reactions of 102° F. or more (5 over 103° F. and one 105.6° F.) A few of these were made into the tumor. During these first two months the growth decreased more than half, and became softer. The patient was discharged on June 27, 1901. Apparently the injections were continued more or less constantly until about September 10, 1901, almost five months. There was no further diminution in the size of the growth after the first two months, and for a long time thereafter there was no distinct increase in size.

Clinical Course: The patient was readmitted to Memorial Hospital on October 3, 1901, stating that since her discharge her general health had been very good. She added that the tumor had diminished in size, and become softer when she was taking the toxins, but that since discontinuing the injections she thought it had become harder and had increased in size. Physical examination on October 3, 1901, revealed that the hard, smooth tumor bulged considerably more than when the patient had left the hospital in June. Measurements were approximately the same as they were when the patient was first referred to Coley, $6 \times 6\frac{1}{2}$ inches.

Further Toxin Therapy: (Buxton VI) Injections were resumed on October 3, 1901, and were continued three to six times a week during the next 6½ weeks. They usually caused good febrile reactions (102-104° F.). At first there was marked diminution in the size of the growth, but later little effect was noted and finally the tumor began to grow very rapidly. The patient lost much weight and became cachectic. Coley regarded the case as entirely hopeless at this time.

Surgery: However, he decided to make a partial removal. This operation was performed on December 27, 1901, though a median incision four inches long below the umbilicus. The growth was found to be encapsulated. Much of the mass lying just below the skin was removed. The patient received one more toxin injection on January 23, which caused a marked reaction (105° F.). She was discharged on January 25, 1902. At this time the abdomen had the appearance of a seven-months' pregnancy. The patient was very weak, markedly cachectic and complained bitterly of pressure symptoms. Coley advised a trial with the x-rays.

Radiation: X-ray treatments were administered by Dr. Clarence E. Skinner of New Haven, Conn., beginning January 28, 1902. Forty-six were given up to June 5th. By this time the lateral circumference of the tumor had increased from 13¾ inches to 15 inches. Coley saw her in May, 1902, and believed the condition to be "out of control."

Concurrent Fever: The patient then had several attacks of fever lasting a few days, with symptoms of toxemia, possibly due to absorption of necrotic tumor products, following which the general health improved considerably.

Further Radiation: From June to September she received 31 more treatments and during this time there was so much local and general improvement that the patient decided to resume her work as a school teacher in September. X-ray treatments were continued about every five days until April 25, 1903, and for the next four months were given once in two weeks. From August, 1903, to May 20, 1904, five more treatments were given making a total duration of x-ray treatment of 849 days, with 136 treatments in all.

Clinical Course: The tumor had entirely disappeared by May, 1904, and the patient had gained 19 pounds, her weight being 147 pounds. Coley examined her in July, 1904, and was unable to detect any evidence of tumor, but there was considerable skin damage from the radiation.

X-Ray Cancer: Dr. Charles A. Porter reported: "She remained perfectly well until August, 1907, though she noticed that the skin of the hypogastric region was irregularly mottled and much thicker than normal, especially on the right side. Pain, from which she had been free, began to be severe and ulceration commenced. Severe and characteristic x-ray lesions developed, not only in the scar of the shrunken tumor but on the skin over the whole anterior abdomen. No treatment seemed to avail, the ulcerative process gradually spreading, undermining the skin, which subsequently necrosed. In addition to the ulcerations there were numerous papules of undoubted epidermoid cancer." The patient "lost weight and strength, becoming anemic, and suffered severely from the pain . . ." Porter first examined her on March 7, 1908, at which time there was an irregular triangular undermined ulcer in the hypogastric region about the size of the palm of one's hand, extending to the right side of the pubis, nearly to the iliac spine, the other angle approaching the umbilicus. The base was

sloughing in parts, in others presenting poorly vascularized granulation tissue, in which necrosis was advancing rapidly. Several areas in the surrounding skin showed characteristic appearances of x-ray changes. The irregular ulceration with a firmly adherent fibrinous base was surrounded by a very bright scarlet red areola which bled at the slightest touch. Certain points in the ulceration were exquisitely painful on pressure. There was slight fever.

Further Surgery: After attempting to cleanse the wound with antiseptics for a few days, the whole ulcerated area was excised with a one-inch margin down to the aponeurosis of the abdominal muscles. The excision left apparently normal fat, except over an area two by three inches to the right of the median line, where extremely firm scar tissue showed the site of the former growth. The skin at the periphery, however, was very tough and three times the normal thickness. The whole area was thoroughly disinfected with phenol, 95% alcohol and saline, and an attempt was made by tension sutures to diminish the gaping wound. It was dressed with protective tissue, gauze and swaths. The tissue was examined by Dr. S. B. Wolbach, Director of Harvard Medical School Pathological Laboratory, who reported: "The atypical character of the epithelium, the presence of pearls and many mitoses and the relationship of epithelium to connective tissue in these growths warrant the diagnosis of epidermoid carcinomata." (For greater detail see Wolbach, 1909).

Post-Operative Fever and Infection: The operation was followed by marked reaction, pain, temperature of 102° F., rapid pulse, exhaustion, and at the end of three or four days, continuous sloughing of the edges of the wound, involving the skin more than the fat. Porter stated that "operation was followed by marked infection which was questionably diphtheric." The wound was extremely sluggish and granulations formed very slowly, covered by unhealthy fibrin. (For photograph of the condition see Wolbach, 1909, Figure 2). The general condition was poor.

Clinical Course: After months of convalescence, granulation gradually was established and epidermization slowly took place from the pubic and inguinal regions, but the thickened skin ulcerated upward and laterally, with great pain and some fever. Six months after the first operation Porter again operated under ether, and removed the remaining thickened skin and upper half of the subcutaneous fat of the anterior abdominal wall for a distance of four inches above the umbilicus, and laterally to the level of the anterior superior spine. The wound was dressed with protective dressings.

Post-Operative Fever: The reaction was well marked but less severe than after the previous operation, and the temperature became normal in ten days.

Clinical Course: By December 5, 1908, the patient had gained in general strength and color and was walking about. The wound was granulating healthily at this time, and 14 Thiersch grafts were applied from the arm of a friend. These grew vigorously, but "after three or four weeks all the grafts . . . were raised by blisters and slowly disappeared . . ." Further grafting was done from the patient's own thigh. Porter stated that there was copious discharge from the whole granulating surface. He added that he "never had seen anything like it," and considered that it might be due "to some peculiar condition, or possibly to the irritation of the green soap." By April 1, 1909, almost all the autogenous Thiersch grafts had taken and the huge wound was continuously covered with sound,

thick, somewhat movable skin, except for an area 2 x 3 cm. in the right upper margin. There was no tenderness in the scar and no pain. The patient had been up and about for three weeks, having been hospitalized 13 months. Owing to continued flexion of the thighs there was some subluxation of both knee joints and she walked clumsily and somewhat in a stooping manner, owing to the contraction of the anterior muscles of the body. Her general condition was excellent. Porter published this case in 1919 and stated that it was "of extreme interest from many points of view."

The patient was seen periodically by Coley until 1923. She remained in very good health after her long hospitalization in 1908-1909. There was never any recurrence of the sarcoma. The patient stated in 1947 that the skin-grafting done in 1908 "has held through the years. The surrounding area is not normal; several operations have been necessary, the last one in 1943. Usually if a small break occurs, it will heal in time." On August 28, 1948, she again reported: "My general condition the past year has been as good as anyone who has entered the eighties has a right to expect. This spring there was an attack of what seemed like neuritis, causing severe pain on the left side and shoulder. It yielded to daily exposures to direct sunlight, but did take some of the strength I had enjoyed before. The area of the x-ray burn still causes discomfort, at times breaking then healing. The scar tissue seems to be hardening somewhat." Her weight at this time was 130 pounds, her height being five feet four inches. In November, 1949, she had a slight attack of coronary thrombosis, being hospitalized for a month and another month in a rest home. This somewhat limited her activity thereafter. The scar tissue continued to break and heal, but caused no special pain. She reported in October, 1950: "A small growth near the right groin was removed about eight years ago by Dr. A. A. Palermo. He finds another slight recurrence at the same place. He feels that if my strength permits it should be removed." Palermo reported on November 28, 1952: "She is now 84 years old, looks quite well still, and is up and around and able to do her usual light household duties. There are no enlarged superficial lymph nodes. The liver and spleen are not enlarged and there are no intra-abdominal masses suggesting tumor. The skin of the abdomen shows the typical radiation reaction with several masses of recurrent disease. . . . Most of these have been present for several years and are very slow-growing and apparently do not bother the patient appreciably. The one in right groin is the largest and the patient states has doubled in size the past year. They bleed easily but she controls this by applying ordinary cotton which becomes adherent to the lesion and controls the oozing. Particular attention to the groins shows no evidence of lymphadenopathy. The areas of involvement were 1 to 3 cm. in diameter. In March, 1954, the patient had a slight cerebral hemorrhage for which she was hospitalized a few days. The only residual effect was some loss of memory.

When last contacted on June 30, 1958, at the age of 91, the patient had had no recurrence of the sarcoma for which she had been treated 57 years previously, and she appeared to be in fair physical health, having had only an occasional cold in the preceding four years.

Porter wrote to Coley in 1923, stating that he believed this case was one of the most remarkable results of combined x-ray and toxin therapy in the literature.

References: 17c, 18a, 19a, 41, 73, 81, 87a.

CASE 65: *Diagnosis:* Recurrent reticulum-cell sarcoma, primary in the bicipital region, with metastases in the axilla and the abdominal wall, confirmed by microscopic examination in December 1953 by Dr. Henry L. Jaffe, Director of Laboratories, Hospital for Joint Diseases, New York (81). Note: see below for the reports of pathologists in 1928-1935.

Previous History: L. V. McN., male, aged 26, of Hattiesburg, Mississippi. The patient had measles, mumps, chicken-pox, whooping cough and typhoid as a child. He was a strong, healthy man. Onset, in November, 1927, he developed a small growth in the right bicipital region which was excised by Dr. C. C. Hightower, in February, 1928. A month later a growth was noticed under the left arm which gradually became larger. On May 21, 1928, the patient reported to the Crawford Clinic in Hattiesburg with what appeared to be a malignant nodule at the outer border of the left pectoralis muscle and four smaller nodules extending down into the axilla. A specimen was removed by Dr. W. W. Crawford and sent to Dr. John A. Lanford, of Aouro Infirmary, New Orleans, who reported that the growth was a melanosa sarcoma of the most highly malignant type; the cells were dividing so rapidly that no pigmentation was in evidence. Sections were also examined by Drs. Francis Carter Wood and James McWorter, both of whom agreed it was a malignant tumor but did not classify it (41). One x-ray treatment was given at the time of biopsy.

Toxin Therapy: (Parke Davis XIII) Injections were begun by Crawford on May 29, 1928, the initial dose being 1 minim. This was increased by 1 minim at each injection until the maximum of 15 had been reached. The frequency was daily for the first 11 days and thereafter every two or three days during all of 1928. The maximum febrile reaction was 103.8° F., with a chill which occurred on June 7 following a dose of 9 minims. In August 1928 a small metastatic nodule appeared on the abdominal wall which was removed and also reported to be malignant melanoma by Lanford. The injections were continued, the dosage ranging from 10 to 16 minims. During 1928 a total of 63 injections was given from May 29 to December 31. During 1929 a total of 65 injections was given. In January, 1930, a small, typical lesion appeared on the neck, about the size of a small hazel nut, of a purplish-red hue. This could have been removed surgically, but in view of the fact that it was metastatic, Crawford felt it was best to persevere with the toxins. Accordingly the injections were continued, and at the end of three months nothing remained but a small scar. The patient received 6 injections in January, 1930, 3 in February, 4 in March, 1 in April, 4 in May and 3 in September, 1930. Further courses of the toxins were given at intervals of several months, until about September, 1933, in doses of about 12 to 16 minims, making a total duration of over five years. No further metastatic lesions developed after about October 1931. Prior to that, one or two other small lesions appeared and gradually subsided under continued treatment.

Clinical Course: The patient remained in excellent health, except for an appendectomy in early 1952. He was last traced on March 26, 1958, 30 years after onset.

Note: Crawford used the toxins over a period of 27 years and he regarded the above case as the most outstanding. In sending us the history he added: "The late Dr. Coley seemed to feel that our success in this particular case was due to our systematic and persistent treatment over a period of years." (81) In discussing his experience with the toxins, Crawford stated in 1943 that he had

used intramuscular injections in all his cases, usually in the gluteal region, using Tracy's product (Type XI) as long as it was available (to 1921) and thereafter Parke Davis (Type XIII). He usually began with one minim, increasing daily until a definite reaction occurred, the dose necessary to accomplish this varying from 6 to 15 minims. When a definite reaction was obtained a further injection was not given until the temperature had returned to normal, usually a day or two. The dosage was then reduced by 2 or 3 minims and daily administration resumed until another reaction was obtained. He added: "Whenever a patient was hospitalized it was possible to follow up an aggressive program . . . for several weeks, and later courses were administered at intervals over a period of a year. . . ." Among the cases that did not recover, a number showed signs of disintegration of the lesion and in some instances sloughing. In other cases there was a definite shrinkage of the lesion temporarily.

References: 41, 81.

CASE 67: *Diagnosis:* Terminal sarcoma of the neck, face and submaxillary region involving the bones and subcutaneous tissues; the forehead, parietal regions, left cheek and jaw being most affected, confirmed by microscopic examination. There was marked bilateral exophthalmos.

Previous History: Miss H. R., female, aged 19, of Mahanoy, Pennsylvania. The family history was negative for cancer, tuberculosis and diabetes. The patient had had the usual diseases of childhood, but no serious illnesses. She had a tonsillectomy at the age of nine. Thereafter she had chronic bilateral otitis media. (She never had any ear trouble until after her tonsils were removed, but she was regarded as a "sickly" child). Menses began at the age of 14½ years, a normal cycle. Onset, in March, 1931, a hard nodular swelling of the neck was first noted directly below the angle of the right jaw. This gradually became larger and in a few months was 1½ inches in diameter. A provisional diagnosis of deep cervical abscess was made at a hospital in Pennsylvania.

Surgery: Upon operation no free pus was found. A specimen of tissue was sent to the Research Institute of Cutaneous Diseases in Philadelphia, and a diagnosis of chronic interstitial adenitis was made. Shortly after this operation the hard fixed swelling gradually began to extend inwards until it had filled the entire right submaxillary region and by pressure produced edema of the pharynx.

Radiation: Several small doses of x-ray therapy were then given without any relief.

Clinical Course: On June 14, 1931, the patient was admitted to Jefferson Hospital, Philadelphia, where a tracheotomy was performed because of edema of the glottis.

Further Radiation: Radium treatment was given at this time. (She was hospitalized four weeks). Further radium treatment was given on August 15 and again in September, 1931, apparently without benefit. By September 21, 1931, the swelling had extended into the face and bones of the skull. Further radium treatments were given after November 31, 1931.

Concurrent Chronic Infection: On January 28, 1932, the patient was operated upon for chronic mastoiditis, a left mastoidectomy being performed at Jefferson Hospital, Philadelphia.

Further Radiation: Radium treatment was given "to its full extent" during the next few months. No burns were produced, but the patient experienced marked "radiation sickness."

Clinical Course: The patient was discharged on May 12, 1932, "extremely ill, the end being expected at any time. The tumorous condition was localized to the region of the head and face, seemingly involving the bones and subcutaneous tissues. The forehead, parietal regions and left cheek were most affected. There was marked exophthalmos of both eyes, the lower lids were everted, and greatly swollen. The left mandible was involved and almost completely ankylosed. A foul smelling slough was present in the region of the left lower molar. Treatment at this time was entirely symptomatic, mostly morphine." Her weight had declined steadily from a normal of 120 pounds at onset to 70 pounds in early June, 1932. Her height was 5 feet 2 inches.

Toxin Therapy: (Parke Davis XIII) Injections of Coley's toxins were begun by Dr. Clemens S. Burke, of Mahanoy City, Pa., about June 12, 1932, the initial dose being $\frac{1}{4}$ minim, increasing every 38 hours by $\frac{1}{4}$ minim. Burke stated: "An improvement was noted following the first few treatments, subsequently on larger dosage a more rapid result. Although there was always some improvement and the swelling disappeared, another would develop elsewhere. . . . The larger dosage that it became necessary to use caused much pain and areas of painful induration." The patient and family objected to further use of the toxins at this time, and Burke was forced to discontinue treatment. (This course was given subcutaneously into the arms and buttocks, a route that is no longer considered effective, and which does produce painful indurations and slow absorption).

Clinical Course: The tumor again began reappearing at various sites.

Further Radiation: At a local hospital x-ray therapy was then given with very marked benefit. The tumor disappeared from all parts of the face and head where it was showing evidence of recent growth. By March 27, 1933, it was limited to the right submaxillary region and under the chin as one large extensive mass involving the floor of the mouth causing the tongue to be elevated, and great difficulty in breathing and swallowing.

Further Toxin Therapy: (Parke Davis XIII) Injections of Coley's toxins were resumed and two more courses were given with an interval of rest between them. The intravenous route was used and marked reactions were produced ($102-103^{\circ}$ F.). The total duration of treatment at this time was several months. The tumor mass broke down, a part of the tongue sloughed out and also a portion of the lower jaw. The remains of the extensive growth disappeared and the patient made a complete recovery. She gained over 40 pounds of weight that she had lost.

Clinical Course: She married in March, 1937. Her first child, a son, was born the following autumn. The second and third children, both daughters, were born in 1939 and 1945, all being healthy and normal. The patient stated that her only complaint during the years following her recovery was that when she caught cold she tended to get ear trouble in both her ears (otitis media, no further mastoid). However, she was strong enough to do all her own work and in addition, for $2\frac{1}{2}$ years, to have an outside job as well. Her normal weight in 1955 was 114 pounds. She remained well and free from recurrence when last traced on March 26, 1958, 27 years after onset.

Note: In this case the initial course of toxins given in small doses subcutaneously did not prove beneficial. It is now recognized that subcutaneous injections are not effective, and the indurations produced due to poor absorption are unpleasant for the patient. It is of interest to note that radiation in this case had no effect at all until after the initial course of toxins. However, prolonged radiation caused only temporary incomplete regression. The disease was not finally controlled until prolonged intravenous toxin therapy was given. The possible role of the chronic bilateral otitis media and the mastoiditis is difficult to evaluate in this case. However, this infection may have played a part in supplementing the toxin therapy, to which Burke attributed this remarkable recovery.

References: 41, 81.

CASE 70: *Diagnosis:* Generalized hemangioendotheliomata (site of primary unknown), with metastases throughout the body, confirmed by microscopic examination of several tumors removed for biopsy at Grace Hospital, Detroit, Michigan, March 23, 1947. The pathologist reported:

"Gross: Specimen A consists of tumors from the abdomen and head removed with a knife. Specimen B consists of a tumor from the left arm removed with a needle.

"Microscopic: The specimens from the three areas are identical in composition and contain a new growth within the corium and subcutaneum. The new growth is unencapsulated and is composed of numerous small blood vascular spaces. The latter are lined with tumor cells which are endothelial in type and the septae between the blood spaces are made up of a proliferation of the lining cells of the blood spaces. There is a tendency for the new growth to form isolated masses of vascular spaces separated by connective tissue trabeculae which vary in thickness. In general, the cells that comprise the new growth vary somewhat in size, shape and staining qualities although all of them are small. The epidermis varies considerably in thickness and in places exhibits a marked hyperkeratosis.

"In view of the fact that this individual has multiple tumors of identical composition, it is entirely logical to believe that he had one primary tumor which has metastasized throughout the body. Internal metastases may be present or occur. *Diagnosis:* hemangioendotheliomata." The sections were reviewed by Dr. Henry L. Jaffe, Director of Pathology, New York Cancer Research Institute, in September 1958. He concurred with the above diagnosis.

Previous History: Male, aged 53, of Detroit, Michigan. The family history was negative for similar types of neoplasia and the previous personal history was also essentially negative. The patient had "several bluish lesions" removed from his lip in 1938 by another surgeon. Onset, in December, 1946, he noticed that many reddish macules and papules were appearing on various part of the body which he referred to as "warts". He was seen by Dr. Felix Pinkus, the well-known German dermatologist. A biopsy was performed. Pinkus considered the lesions to be probably Rendu-Osler's type of telangiectasia. His son, also a prominent dermatologist, did not accept this diagnosis.

Radiation and Other Therapy: Various types of treatment were tried, including penicillin and rutin, and also x-ray therapy (to three lesions on the face), without benefit.

Clinical Course: The patient was referred to Dr. Clyde E. Hasley on March 24, 1947, at which time he had multiple lesions on the hands, arms, face, head, body and legs, which had been developing since December, 1946. About two months after they first appeared many of the lesions bled and were painful, but there was no bleeding from the mucous membranes. Telangiectasia was detected under the tongue. The other physical examinations were negative.

Laboratory tests showed his coagulation time as $4\frac{1}{2}$ minutes, his bleeding time as $1\frac{1}{2}$ minutes.

Surgery: Several lesions were removed from different parts of the body, some with the scalpel, others by the electrodesiccation method; (see above for the pathological report on three of these lesions).

Further Radiation: Some of the lesions on the hands and arms were then treated with x-ray therapy (1,200 to 1,900 r.). There was no beneficial response to radiation in the period when benefit should have been noted.

Toxin Therapy: (SKI XIV): Injections of Coley Toxins were begun on April 1, 1947, by Hasley. The initial dose was 1/80 minim, which caused a slight chill but no severe reaction. The next day a dose of 1/60 minim caused a febrile reaction of 104° F. On April 4 the same dose caused no reaction. The fifth injection on April 5 (1/40 minim) caused a rise in temperature to 100° F. It was noted that day that "some of the lesions were quite dry and were falling off . . . there was considerably less bleeding from some of the irritated lesions." The patient was given a total of 12 injections intravenously in a period of 18 days, the maximum dose being $1\frac{3}{4}$ minims. The febrile reactions averaged $102-104^{\circ}$ F. The patient was discharged on April 19, 1947. He was examined at frequent intervals during the next five weeks. On April 24, three weeks after the first injection, Hasley observed that the lesions were getting much smaller. On May 1, as the patient seemed extremely nervous, he was placed on phenobarbital. A week later the lesions were still smaller, and on May 28, 1947, very much smaller.

Concurrent Infection: After the patient was discharged from the hospital many of the lesions became secondarily infected. No details are known concerning what type of infection was present or what treatment was given.

Clinical Course: The patient made a complete recovery. He was not seen again by Hasley for 11 years, until June 5, 1958, at which time he presented a pigmented lesion over the right shoulder area. Clinically it appeared to be melanoma. This was the only pigmented lesion present on the body. All the former lesions present in 1947 were healed with very little atrophy and no evidence of telangiectasis.

Surgery: The melanotic nodule was removed as an excisional biopsy on June 13, 1958. The pathologist reported "multiple foci of new growth . . . melanoblastoma of skin." (This section was reviewed by Jaffe, who agreed with this diagnosis).

Clinical Course: The patient was advised to have further toxin therapy post-operatively, but refused. He was reported to be "doing well" in July, 1958, over $11\frac{1}{2}$ years after onset of the widespread hemangioendothelioma from which he recovered following toxin therapy.

Reference: (81).

Table I. SERIES B: FAILURES OF INOPERABLE SARCOMA OF SOFT TISSUES TREATED BY TOXIN THERAPY; 67 cases

Doctor References	Sex Age	Type of Tumor	Site of Tumor	Other Treatment Before or After	Type of Toxin Site, Duration	Immediate Result of Toxins	Final Result
1. Lloyd & Coley 9, 12, 13, 41	female 20	spindle cell sarcoma (tendon sheath)	palm of hand 5 times recurrent, axillary metastases	5 operations prior to toxins; incomplete curettage during toxins (6/94)	Type IV spring 1893; stopped during summer; resumed 10/93; intramuscularly or near growth in hand; treated as an ambulatory case by Lloyd, hospitalized by Coley	when toxins given steadily, adequate dosage, tumor decreased; incomplete curettage; gained 20 pounds	well 15 months; further recurrence; amputation; died brain metastases 7 years after onset, 2½ years after toxins begun
2. Coley 16b	male 48	myxosarcoma	muscles of thigh; far-advanced; multiple tumors recurrent	surgical removal of primary	Type IV, 4 weeks, 1/94; site not stated	temporary decreases; later rapid growth	death 4 months after toxins begun
3. Coley 2, 41, 73	female 48	sarcoma (type not stated)	face, orbit (exophthalmos) also extensive involvement cervical glands	none prior to toxins	Buxton V & VI. 28 in 58 days; site?	some regression	died 2 years after onset
4. Coley 16a, 73	female 7½	round and spindle cell sarcoma	bilateral ovary, thrice recurrent (trauma)	surgical removal of primary and first recurrence	10 doses Buxton V in 3 weeks; site?	considerable decrease in size	contracted typhoid died 6 weeks later
5. Coley 2, 41, 73	male 43	round cell sarcoma	recurrent thigh (trauma, onset 4 mos. later)	surgical excision (incomplete)	5 doses (daily) (V) 10 days post-operative, little reaction (site?)	wound healed	death 11/21/96, "septic poisoning and sarcoma"
6. Andrews & Smith 1	male adult	sarcoma	iliac fossa extended ¾ of way to umbilicus,	aspiration biopsy; later abscess opened freely, irrigated with hydrogen peroxide	VI intramuscularly (ineffective) then into tumor every 48 hours, duration not recorded	tumor softened, broke down, immense abscess formed, much of tumor necrotic	life prolonged but died of exhaustion 8 months after onset
7. Rumbold 12, 16, 29	female adult	round cell sarcoma	breast 7 times recurrent	6 operations (prior)	VI 4 weeks, local injections probably	patient weak, persistent nausea, complete regression	developed internal metastases; death; (autopsy)

8. Coley 29, 108	male 37	myxosarcoma	chest wall, many times recurrent infiltrating	great many oper- ations; whole anterior chest scarred	VI for 3½ years, with intervals of rest; site not recorded, probably in chest wall	complete regression	well 8 yrs.; again recurred; toxins resumed briefly; x-ray (12) caused complete necrosis upper sternum; death in 4 months
9. McArthur 13, 29	female 5½	round cell sarcoma	antrum of High- more, nares, nasopharynx; extensive exophthalmos; cervical gland metastasis; terminal, bed-ridden	stimulants, tonics, rectal feeding (marked weight loss); after 2 weeks' toxins cervical glands removed; 3 wks. later primary removed	VI every 48 hours for about 5 weeks; resumed after recurrence	tumors became oper- able; exophthalmos diminished; patient gained 32 lbs.; re- currence after toxins stopped; improve- ment when resumed	disease not control- led; death 2 mos. later
10. Coley 41, 73	male 45	spindle cell sarcoma	scapular region, 11" x 15" ulcer- ated, recurrent; axillary involve- ment	surgical removal primary; recur- rence untreated	VI for 6 weeks, remote from tumor	slight regression, no marked effect (com- pare with case 11 in successes)	died 2 months later
11. Coley 3, 73	female 62	myxosarcoma	abdominal wall iliac region, 5 times recurrent 9" x 9½"	5 operations (prior)	V and VI, 39 in 3 months, site?	temporary arrest	died over 12 years after onset, 20 months after toxins begun
12. Coley & Meixell 13, 16, 41, 73	female 20	spindle cell sarcoma (tendon sheath)	palm right hand, thrice recurrent, axillary node; (trauma)	2 operations	V and VI, 3 months, intramuscular (arm); resumed for brief period	complete disappear- ance; perfect func- tion; 5 mos. later axillary metastasis excised, showed very marked necrosis	later again recur- red; amputation; no further toxins; death, generaliza- tion, 5 years after onset
13. LaFetra & Coley 16, 16a, 16c	female 48	spindle cell sarcoma	thigh, groin recurrent (trauma); edema entire extremity	incomplete surgi- cal removal; large mass in groin not touch- ed; old cicatrix removed after 2nd course toxins; no evi- dence tumor	VI begun 11 weeks post-operative; given 3 mos.; resumed after further recurrence; site?	pain ceased; complete regression, edema sub- sided, leg normal; re- currence 7 mos. later; again regressed after toxins resumed	later again recur- red; no further treatment; death about 6 years after onset

Doctor References	Sex Age	Type of Tumor	Site of Tumor	Other Treatment Before or After	Type of Toxin Site, Duration	Immediate Result of Toxins	Final Result
14. Harris 16	female 31	large round cell sarcoma	ovary, recurrent after hysterectomy, size of cocoanut, obstruction; extreme distention (terminal)	pan-hysterectomy recurrence untreated	VI subcutaneously; increased to 40 minims, very little reaction; about 18 doses in 16 days	on 4th day wound opened; almost normal evacuation; in 3rd week tumor gangrenous, sloughing, fecal matter discharged	septic absorption from immense slough; death 4 weeks after 1st dose
15. Willy 29, 41, 81	female 42	mixed cell sarcoma	uterus, broad ligament, recurrent, size of cocoanut; extensive adhesions; hemorrhages	laparotomy; prognosis "few weeks"; arsenic (oral); pyoktanin (injected into tumor)	VI, later weaker Parke Davis IX given spasmodically 6 years by husband (physician); injections into accessible portions of tumor more effective than remote from tumor	prompt complete regression, in 10 days; recurred after toxins stopped, again regressed gained 22 lbs.; (larger doses, local injections in cervix area more effective than intramuscular)	disease controlled 6 years returned Switzerland; died on operating table (another attempt at removal)
16. Coley 18b	male 49	spindle cell sarcoma	thigh, recurrent 9 months after operation	extensive surgical removal 1 yr. after onset; later hip joint amputation	VI for 3 months, site?	marked regression at first; remained stationary, then increased	further recurrence; died 4 years later after onset
17. Nicholson 82a	female 46	round cell sarcoma	uterus, broad ligaments; 32 lb. weight loss; terminal	none	VI every other day for 15 days; some reaction; site?	no apparent benefit	died 15 days after first dose
18. Meriweather 75a	female 33	small round cell sarcoma	left leg, at apex Scarpa's triangle; foul discharge much pain	had left-sided pleurisy; mass lanced; thereafter it grew rapidly	VI given briefly as patient objected; injections resumed given into primary tumor	decreased 50%; after toxins stopped primary increased, metastases to glands around right jaw; latter disappeared under further toxins but primary did not; further tumor appeared on left arm, regressed under continued toxins	disease not controlled; patient emaciated; death 5 months after toxins begun

19. Coley 16d, 73	male 42	round cell sarcoma	nares, antrum recurrent, very rapid growth, frequent hemor- rhages	incomplete surgi- cal removal; after toxins ex- ternal carotid tied; curettage	VI in or near growth; good reactions 40 in 73 days; 2 more courses after recurrence	very marked regression, hemorrhages ceased; sloughing of tumor in nasal cavity; tumor re- curred when toxins stopped	slow steady increase; death from hemor- rhage at attempted removal (another hospital)
20. Coley 41, 73	male 25	round cell sarcoma (noted during influenza)	thigh, extensive 5" x 8" terminal (trauma, strain)	explored; curet- ted twice (foul pus evacuated, sinuses irrigated) permanganate of potash; fever prior to toxins; later further surgical drainage	VI begun 8 days after 2nd curettage, given 9 weeks; site?	no apparent benefit but his appetite remained remarkably good	pulmonary symp- toms, death 4 mos. after 1st injection toxins
21. Coley 17a, 17c, 31, 73	male 70	round cell sarcoma; small amount fibrous tissue, very vascular	left neck, poster- ior to scalenus anticus muscle, 5 times recurrent; size of orange with metastases femoral region, axilla, right neck	five operations; after initial tox- ins left external carotid tied; later x-ray (6 weeks) (given after tox- ins) complete re- gression tumors in neck, axilla in 4 weeks	VI, only 1 reaction; given 3 weeks; re- sumed for 11 days, intramuscularly	at first slight im- provement; later no effect; patient dis- couraged, bored at hospital life	further metastases groins; responded to further radia- tion; death cere- bral thrombosis onset, 2 years after toxins
22. Porter 29, 58	female 40	round cell sarcoma	left ovary recurrent in pelvis	?	VI for 2 mos.; toxins resumed after recur- rence again developed; site?	complete disappear- ance, well 4 years	disease no longer controlled; end- result not given, believed fatal
23. Coley 17a, 41	male 25	round cell sarcoma	parotid, twice recurrent	2 operations (prior); later external carotid tied; x-ray (5) after	VI for 3 weeks; small doses; site?	at first slight regres- sion, considerable pain relief; later no effect	death 6 mos. after onset
24. Emerson 52a	female 64 (obese)	spindle cell	tonsil (28 lbs. weight loss) also had had	(had had tumor- malignant ? on forehead destroy- ed by caustic	Parke Davis IX or Bux- ton VI in tumor or arm twice weekly, 2 months;	gained 25 lbs.; only 1 more bloody discharge from breast; general health improved; no pain	after toxins stopped metastases de- veloped, patient failed rapidly,

Doctor References	Sex Age	Type of Tumor	Site of Tumor		Type of Toxin Site, Duration	Immediate Result of Toxins	Final Result
24. cont.			5 bloody discharges from left breast	1900) electrolytic needles passed into growth, some temporary benefit; later x-ray (several)	after recurrence injections resumed in arms (poor absorption)		death 17 months after onset
25. Coley 18b, 18c, 20, 24, 41, 73	male 16	round cell sarcoma	chest wall, necrosis of 8th and 9th ribs (onset followed pleurisy with effusion)	necrotic ribs, gelatinous masses partially removed; 2 courses x-ray thrice weekly same day as toxins; 2nd curettage for recurrence (very profuse hemorrhage)	toxins (VI) 2 mos. in wound region; moderate to good reactions; 3½ mos. later toxins (IX), 13 in 40 days, no reactions; 3rd course, 97 in 6 mos.	complete regression in excellent health, gained 25 lbs.; local recurrence	disease progressed locally; death 2½ years after onset
26. Shield 29, 94a	female 44	myeloid sarcoma	breast, recurrent in cicatrix, axilla, beneath clavicle	mastectomy; none for recurrence	large doses (VIII) into vascular tumor mass, some severe reactions, given about 17 days	marked pain relief larger growth disappeared in 17 days, smaller half necrotic, mass under clavicle smaller; 19 days after dose: staph. pyemia	death from pyemia in 48 hours; autopsy: all tumors had disappeared or were necrotic (toxin found sterile)
27. Battle 1b	not given	spindle cell sarcoma	peritoneum (abdominal)	not given	VIII intramuscularly in arm; 1 dose in abdominal tumor	abdominal measurements decreased 1 inch	patient died after intraabdominal dose
28. Rigby 41	female 14	spindle cell sarcoma	aponeurosis of left knee involving periosteum; recurrent in amputation flaps at hip joint; metastases ilium	exploratory operation, biopsy; amputation; x-ray begun 5 weeks after toxins (30); 2nd course (13) given during 2nd toxins	VIII, 5 in opposite leg, rest into tumor, 47 in 120 days; good febrile reactions; toxins resumed after 3½ mos.	gradual regression; immediate cessation of pain (before radiation begun); pain increased when toxins stopped, ceased when resumed	disease not controlled, mass in right groin; death 4 yrs. after onset of pain, 12 months after toxins were begun

29. Semken 41	young male adult	mixed cell sarcoma	fascia of pec- tineus muscle over upper fe- mur involving periosteum, recurrent extensive	primary removed surgically	Parke Davis IX, later Buxton VI, 24 in 76 days in primary tu- mor usually, a few in abdominal wall, (sub- cutaneous); reactions more marked with VI	growth began to break down; patient became septic	disease not control- led; death 4 mos. after toxins begun
30. George & Warthin 54a	male 73	large spindle cell sarcoma (arm); adeno- carcinoma py- lorus, adeno- matous polyp; myomata; also had arterio- sclerosis, chronic neph- ritis, chronic bronchitis	multiple primar- ies: right fore- arm (sarcoma), axillary metastas- is; pylorus (ca); polyp on cardia, myomata on stomach wall; condition hope- less	incisional biopsy arm tumor; no other therapy	P.D. IX into tumor daily or every 2 days for 41 days	large areas necrotic at site of injection, but tumor grew peripher- ally very rapidly; in- volved whole arm; ab- scess; septic poisoning	death 3½ mos. after first injection. Au- topsy showed exten- sive necrosis in sar- coma and its metas- tases
31. Parlett 2, 41, 73	male 26	sarcoma	chest wall involv- ing pectoral re- gion to clavicle; metastases in 4th finger right hand, recurrence on right hand	incomplete re- moval twice; amputation of finger; x-ray during toxins (no effect), severe x-ray burn	toxins (IX) into tumor and shoulder, given 15 mos.; resumed 3 mos. later for about 4 mos. with further x-ray; final course	no improvement until fall 1902 when further recurrence responded to toxins in and near tumor masses; disease controlled about 8 yrs., in good condition	died pulmonary metastases 9 yrs. after onset, 6 yrs. after toxins begun
32. Underson 41	female young adult	spindle cell sarcoma	post-orbital re- gion, involving left naris, roof of mouth	biopsy, later x-ray (after toxins); ul- cerated area roof of mouth healed temporarily	toxins (IX) daily usu- ally intramuscularly in shoulder, or cheek; given about 3 mos.	cessation of growth (about 4 mos.)	disease not con- trolled, death 6 mos. after 1st dose
33. Coley 41, 73	male 56	small spindle cell sarcoma	deltoid muscle of shoulder; twice recurrent in dis- tal clavicle, scap- ular region, ribs, cervical glands (trauma)	incisional biopsy, surgical removal; prompt recur- rence; interscap- ulo-thoracic am- putation; x-ray began week after toxins, 4 a week; dissection of recurrences	P.D. IX locally daily or every 2 days, large doses, little reaction, given during x-ray for about 6 weeks	little improvement	death 6 mos. later

Doctor References	Sex Age	Type of Tumor	Site of Tumor	Other Treatment Before or After	Type of Toxin Site, Duration	Immediate Result of Toxins	Final Result
34. Bull 21a, 41	male 34	mixed cell sarcoma vascular, extensive	inner, upper thigh; recurrent; bedridden, very weak, 20 lbs. weight loss, much pain	exploratory operation large hematoma evacuated; spurting hemorrhage 3 days later; tumor removed; rapid recurrence untreated	Tracy X alternately into tumor and remote from it; toxins stopped because Bull became ill and no one else continued it	immediate response tumor broke down, rapidly drained large quantities dark fluid large mass over 5" in diameter separated, and easily lifted out leaving clean base	control lost; toxemia developed (absorption large amount necrotic tissue); death 2 mos. after 1st dose
35. Green 55, 81	male 60	small spindle cell sarcoma; (primary highly vascular; after toxins tumor in some places degenerated)	soft tissues of back, recurrent twice	2 operations prior to toxins; 3rd operation after toxins; (much less hemorrhage)	Tracy XI in arm and tumors, 12 in 4 wks.; resumed after 3rd operation twice weekly for 2½ mos. in arm and back intramuscularly	tumor less vascular, distinctly smaller; 1 month after last dose local recurrence; further treatment refused; tumor regressed slightly, seemed inactive	death at 76 sarcoma muscles cervical spine — 9 yrs. after toxins begun
36. Green 54b, 81	female 37	small round cell sarcoma	right parotid region, recurrent, involving sternomastoid	surgical removal primary	Tracy XI in arm or tumors; slight reactions; given 2 weeks	after 2nd intratumoral dose tumor softer but larger; unimproved	death 2 years after onset
37. Large 66	male 45	round cell sarcoma, very vascular	post-nasal region and nares completely filled with tumor, bilateral optic neuritis, exophthalmos	small section removal for biopsy	Tracy XI given 1 month, family then stopped them; resumed briefly	in 1 month able to breathe through both nares; improving; severe headaches when toxins stopped; pain greatly relieved when resumed	death cerebral metastases
38. Green 54b, 81	female 2	fibrosarcoma	palate, upper jaw (bleeding) child in poor condition	incision; profuse bleeding; section removed for biopsy	Tracy XI, 2 doses in tumor	severe reaction to 2nd dose (104° F.); fell to normal next day, rose to 102.6° F. that afternoon	grew rapidly worse, died 3 days after 2nd dose, fever 107.6° F. (No autopsy)
39. Mitchell 61, 86a	male 45	round and spindle cell sarcoma	thigh recurrent metastases to lungs, liver, kidneys, mesentery; terminal	exploratory operation, considerable hemorrhage, area tightly packed	post-operative infection did not prevent recurrence; toxins (XI) 21 in 42 days, reactions 100°-104.2° F.	tumor became larger, discharged large amounts necrotic tissue	disease progressed, death 5 weeks after 1st dose

40. Coley 29, 73	female 16	fibrosarcoma	ovary (trauma) large retroperi- toneal recurrence filled entire pel- vis and lower abdomen; much weight loss; cachexia	tumor weighing 6½ pounds re- moved; 2nd op- eration merely exploratory	Tracy XI given 5 wks. severe reactions; re- sumed 3 weeks later for 1 or 2 weeks; tox- ins resumed again month later, 9 in 21 days intramuscularly no reactions	complete regression in 8 weeks; toxemia from rapid absorption; dif- fuse pain over entire body especially joints lost 36 lbs., anemic; some improvement final course	disease not control- led; death 6 mos. after toxins begun
41. Large 66	male 19	round cell sarcoma	post-nasal region, naris, upper jaw, all sinuses on left, extended into cranium; exoph- thalmos; severe pain	probed growth (profuse bleed- ing); incisional biopsy; enuclea- tion eye, upper jaw resected; (removal incom- plete)	Tracy XI begun 2 wks. after operation, given about 3½ months; site?	toxins held growth in abeyance; no pain while toxins given	died 6 mos. after operation; excruciat- ing pain lasted 2 months
42. Rule 2, 41, 73	male 21	angiosarcoma	nasopharynx lymph node metastases twice recurrent	2 operations 2nd recurrence untreated	Tracy XI, minute doses intramuscularly chest, shoulder, pectorals, no reactions; about 6 mos.	improved steadily tem- porarily; gained 20 pounds	multiple metastases; death 4½ years after toxins begun, 10 yrs. after onset
43. Harmer 58, 81	male 42	fibrosarcoma	thigh, recurrent, 4" x 5" (also had osteitis deformans)	exploratory op- eration; mass size of orange removed; im- mediate recur- rence: "incision pouting with new growth"	Tracy XI every 2 or 3 days for 7 weeks; site?	growth softer, not smaller, no attempt to aspirate softened mass; patient suf- fered from absorp- tion of necrotic tissue	rapid growth when toxins stopped; death few weeks later
44. Boyer 41, 81	female adult	endothelioma	nasopharynx recurrent	surgical removal rapid recurrence x-ray (ineffec- tive)	Tracy XI daily usually for 6 weeks; at first in tumor, later intra- muscularly	growth arrested then disease spread to deep cervical nodes	died on operating table; attempted neck dissection
45. Harmer 41, 58	male 22	spindle cell	thigh, thrice recurrent, of rapid growth	3 operations (prior); 3rd recurrence untreated	Tracy XI for 5 weeks, moderate then severe reactions, small doses; site?	tumor "broke" after 5 weeks' treatment	death 7 weeks after toxins begun; sud- den severe hemor- rhages, large vessel involved in growth
46. Coley 73, 81, 108	male 50	spindle cell sarcoma	retroperitoneal 21 x 24 cm.; 20 lbs. weight loss	exploratory op- eration; biopsied; x-ray twice week- ly, 4½ mos. so- dium cacodylate (prior)	Tracy XI, 14 in 24 days; no marked re- actions; possibly con- tinued at home brief- ly; site?	disease arrested temporarily	death regarded as due to carcinoma of pancreas 4 years after onset of retro- peritoneal mass

Doctor References	Sex Age	Type of Tumor	Site of Tumor	Other Treatment Before or After	Type of Toxin Site, Duration	Immediate Result of Toxins	Final Result
47. Lilienthal 81	female 6 mos.	small round cell sarcoma	left nose, upper lip	specimen removed for biopsy	P.D. XII daily (intramuscular) later alternately in tumor and buttock; stopped during severe measles; then resumed; 6 mos. total	no benefit until some given in tumor, then slight regression; growth stationary during measles; after which nothing seemed to control it	death 11 months after onset
48. Coley 2, 24, 41	female 5	endothelioma	face, involving left upper jaw, thrice recurrent	incised; antiphlogistine; then incomplete removal K.I. given	P.D. XII into tumor then filtrates (P.D. XII F) alternately into pectorals about 6 months	tumor softer, more movable, regressed some; gained weight; each time toxins stopped, rapid increase	death 18 months after onset
49. Mertz 41, 81	male 42	sarcoma	right thigh involving groin mid-thigh, popliteal space, thrice recurrent	3 operations 3rd recurrence untreated	XII into tumor masses usually, 6 months almost daily; slight febrile reactions	regressed about 50%	severe pain after toxins stopped; death 5 yrs. after onset, 10 mos. after toxins begun
50. Lee 41, 81	male 59	sarcoma	cervical region	biopsy	P.D. XII in tumor and shoulder about 4 months	at first improved, mass much smaller, breathed better, later no benefit	death
51. Harmer 58	male 14	sarcoma sloughing	thigh invading pelvis, size of cantaloupe (trauma)	none apparently	P.D. XII 7 weeks into growth	some disintegration tumor at sites of injection; no marked effect	pulmonary hepatic metastases; death 6 mos. after onset
52. Allen 41, 81	female 42	myxosarcoma	abdomen and pelvis, extensive involvement (organs covered with growths) almost bedridden	exploratory laparotomy; some tumors removed for biopsy; 4 radium packs during toxins	P.D. XIII intramuscularly every 4-5 days, very little reaction, for 18 months	improved very much, almost complete regression; then had bad fall rapid decline in health	death 16 months after 1st toxin injection
53. Gray 81	male about 40	sarcoma	posterior mediastinum far-advanced (unable to swallow) dull pressure pain	none?	P.D. XIII in deltoid muscles about 2 weeks	pain relieved, could swallow in few days	expired suddenly due to collapse of tracheal wall from necrosis of tumor

54. Coley & Cooper 41, 73	male 49	spindle cell sarcoma	retroperitoneal very extensive metastases to liver, intestines, parietal peritoneum; 35 lbs. weight loss	exploratory operation; biopsy, radium packs (33,021 mch.) during toxin therapy	P.D. XIII, 4 a week apparently intramuscularly 4½ months; no severe reactions	diminution within 2 weeks; softer; very rapid regression, general health improved very markedly; gained 25 lbs.; sudden fatal hemorrhage from remains of primary growth (eroded vessel)	post-mortem showed all metastases above umbilicus had disappeared, also those on lower and parietal peritoneum. Main mass necrotic; died 9 months after onset
55. Coley 73, 81	female 27	mixed cell sarcoma	axilla, recurrent, 13 lbs. weight loss (trauma)	local treatment: salves, poultices; excision; 3 x-ray treatments; radium pack treatments during toxins	P.D. XIII intramuscularly, very small doses; no reactions; 8 weeks with intervals of rest	no apparent benefit	death 3½ months after toxins begun
56. Coley 2, 41	female 50	round cell sarcoma	antrum, ethmoid upper jaw; left eye closed; (whole left malar, left lateral nasal septum); right eye divergent strabismus; pain, perforation; recurrent	nasal polyps excised; tooth extracted; incision, pus drained; excision; recurrences given radium needles, diathermy, fulguration; resulting in perforation at junction hard and soft palate	P.D. XIII 20 intramuscularly, 3 intravenously in 34 days; good reactions more than half the time	almost immediate improvement; protruding fungating tumor largely disappeared, leaving opening at site of perforation	disease not controlled; death 16 mos. after toxins begun
57. Cheney 2, 41	female 45	spindle cell sarcoma	calf right leg, metastases left cervical region, many large ones in lungs	excision; deep x-ray	P.D. XIII, small doses no severe reactions; site? duration?	definite improvement; much less dyspnea, general condition excellent	disease not controlled; death 4 mos. after toxins begun
58. Pratt 2, 41	female adult	fibrosarcoma	lower internal third left thigh; recurrent	excision; 46 x-ray treatments; recurrence increased rapidly during radiation; amputation after toxins	P.D. XIII remote from tumor usually, some in mass; about one month with intervals of rest	decrease in size surrounding tissues softened, but tumor did not	mediastinal and lung metastases death year after toxins begun

Doctor References	Sex Age	Type of Tumor	Site of Tumor	Other Treatment Before or After	Type of Toxin Site, Duration	Immediate Result of Toxins	Final Result
59. Flock 2, 41	male adult	large round cell sarcoma	fascia of foot, recurrent; metastases inguinal, femoral regions causing some edema of leg	x-ray; arch supports; operation; further x-ray for recurrence and pelvic metastases; excision recurrence 5 more x-ray treatments given (absolutely no benefit)	P.D. XIII in abdominal wall, later in tumor or near it; 14 in 19 days; few more injections after 2nd course x-ray	pain, edema relieved; general condition improved markedly; lymph node metastases in left inguinal region reduced in size, 2 new ones developed in skin, grew fast	disease not controlled; death 1 year after onset, 4 months after toxins begun
60. Rilling 41, 81	male 35	spindle cell sarcoma	left leg, ulcerated; abdominal and hepatic metastases causing obstruction; terminal	numerous growths removed for biopsy	XIII, 6 doses in 6 days; one reaction	no apparent benefit	rapid increase in size of liver to crest of ilium; death about a month after toxins begun
61. Coley 73, 81	male 37	myxosarcoma	thigh, very extensive; abdominal metastases	radium (8000 mch.) and x-ray (4) during toxins; 1 more x-ray later	P.D. XIII i.m. and i.v. 30 in 2 months	gained 15 lbs. during therapy, no regression evident until later; very much improved temporarily; then mass became enormous, also huge metastatic tumor in abdomen	death 11 months after toxins begun
62. Wentz 41, 81	female 50	sarcoma	breast, extensive; recurrence involving thorax below clavicle; severe pain	2 operations; plasters applied; mastectomy; improved under collodaurum; cachexia disappeared	P.D. XIII intramuscularly, later into tumor; daily at first then every 2, 3 days; given about 7 months	complete regression, well few mos.; then became ill again	death multiple metastases
63. Coley 41, 73	female 30	malignant leiomyoma or fibrosarcoma on sheath of rectus	involved large intestine twice recurrent involving bladder; nodules in scars; patient depressed, apprehensive (husband had committed suicide due to her illness)	primary removed, also half each ovary (cysts), appendix; suspension done; recurrence in 5 mos., x-ray aggravated it, caused cessation menses; 2nd operation for recurrence; radium pack (4800 mch.)	P.D. XIII, small intramuscular doses too small to be effective; later given by Coley more aggressively in tumor; severe reactions; about 40 in 3 months	during 1st week of more aggressive technic tumor much smaller, more mobile; lost ground rapidly after radium, tumors increased	death 16 months after onset

64. Coley 41, 81	male 7	malignant juvenile nasopharyngeal polypoid angiomyo- sarcoma	orbit twice re- current involv- ing sphenoidal fissure and eth- moid; very ex- tensive, great pain	excision; radium; intensive prolong- ed x-ray for both recurrences; transfusion	following radiation scarlet fever (disease grew during it) P.D. XIII & special VI intra- muscular, good re- actions; 3½ months	pain entirely gone 2 wks. after toxins begun; marked & rapid im- provement in 4 weeks: tumor became entirely necrotic; continuous fever 103-104° F. due to absorption necrotic tumor	improvement ceased pain returned; death 1 month after toxins stopped, about 2 yrs. after onset
65. Memorial Hospital 73	male 31	probably reti- culum cell sarcoma (patient showed great natural resistance)	left thigh recurrent pulmonary metastases both lungs	attempted exci- sion; x-ray to thigh, 6500 r.; to back, hip, 6100 r.; well nearly 6 yrs.; then metastases lungs; further local recurrence intensive radia- tion to thigh & lungs, etc. (this man received a total of 34,800 r.)	P.D. XIII given con- currently with next to final course x-ray (14 in 14 days i.m.) marked reactions	temporarily good re- sponse to combined therapy	death 2½ yrs. after lung involvement, 8½ yrs. after onset
66. Wehrly 81	female 60	leiomyo- sarcoma	uterus, pulmo- nary, pancreatic & diaphragmatic metastases (ter- minal) in shock	untreated (was Christian Scien- tist)	S.K. XIV first one i.m., 3 i.v.	little reactions; no effect	death 3 days after last dose, 13 mos. after onset
67. Wehrly 81	female 46	leiomyo- sarcoma	cervix, broad liga- ments, recurrent lymph node me- tastases bilateral internal iliac and along aorta and lower left lung, severe ab- dominal pain, emesis	biopsy; panhys- terectomy; iliac lymph nodes re- moved; x-ray (3095 r. to recur- rence; 427 r. to nodes; 789 r. to lung); radium to apex of vagina (1100 mch.); no benefit	S.K. XIV, 15 in 17 days, i.v. except first	complete pain relief, ate well; all lymph nodes regressed com- pletely	hydronephrosis, uremia due to block- age of ureters from tumor tissue aptopsy showed much less tumor present than at surgery 7 mos. before

SERIES B. DETAILED HISTORIES.

The following three cases were selected from series B, inoperable failures, as being of sufficient interest to give the detailed histories. The survival period in these cases appears to have been longer than in similar cases treated by surgery or radiation without toxins.

CASE 8: *Diagnosis:* Many-times recurrent, inoperable, infiltrating spindle-cell sarcoma of the chest wall, confirmed by microscopical examination by Dr. George P. Bigg, Pathologist of the New York Hospital, September 29, 1902. The tumors, while originally pure spindle-cell, became more mixed with round cells and much more vascular with each recurrence — that is, the malignancy appeared to increase. Dr. James Ewing examined one of the recurrent tumors in June 1911 and pronounced it "myxosarcoma — infiltrating."

Previous History: Dr. J. E. S., male, aged 37, of Brooklyn, N. Y. When the patient first consulted Dr. William B. Coley, examination showed the whole anterior portion of the chest to be covered with scars of the former operations and with recurrent tumors. (The date of onset is not recorded).

Toxin Therapy: (Buxton VI) The mixed unfiltered toxins were begun by Coley November 4, 1894, and were continued with intervals of rest for $3\frac{1}{2}$ years.

Clinical Course: The patient remained free from recurrence until about August, 1902.

Further Surgery: Two or three small nodules were removed in September, 1902, which proved on microscopic examination to be still spindle-cell sarcoma.

Further Toxin Therapy: The toxins were resumed for another period in small doses, not sufficient to interfere with the patient's work. His general health continued to be good, and his weight normal.

Clinical Course: The patient remained free from further recurrence from June, 1902, to June, 1911, or nine years, when a small cicatricial nodule that had been present all along began to increase in size.

Further Surgery: Coley removed it under ether.

Further Toxin Therapy: Injections were resumed June 9, 1911, using filtrates (Tracy XI-F). They were continued with intervals of rest from June, 1911, through May, 1912, about a year. However, the dosage was not sufficient to cause any severe reactions or to interfere with the patient's practice of surgery.

Clinical Course: The patient reported in good health in July, 1913, with no evidence of any return of the disease. However, another recurrence developed that fall.

Further Toxin Therapy: Toxins were resumed in December, 1913.

Further Surgery: On March 12, 1914, a small nodule was removed from the same region; microscopical examination was again made by Ewing, who found it to be of similar structure.

Further Toxin Therapy: The toxins were again resumed in small doses after this operation and were continued through October, 1914, and possibly until February, 1915.

Radiation: There was another local recurrence in 1915, at which time twelve x-ray treatments were given by Dr. Arthur F. Holding. Endarteritis obliterans of some of the capillaries resulted, followed by complete necrosis of the upper part of the sternum, apparently caused by the radiation. The patient died four months later.

Note: This case suggests the need for more aggressive technique, and the use of a potent preparation, especially in cases in which many recurrences have developed and where several surgical procedures may have interfered with the vascular supply in the cicatricial tissue. Coley was anxious to prove to this patient (who was a doctor) that the treatment need not interfere in any way with one's normal life and he tended from the first to give too small doses. After 1911 he used the weaker filtrate. A study of over 1,000 case histories of patients receiving toxin therapy indicates that in order to produce a high percentage of favorable results it is necessary to use a potent preparation, administered sufficiently aggressively as regards site, dosage, frequency and duration of the injections. If this man had received further prolonged toxin therapy instead of the fatal overdose of x-ray he might have recovered and remained permanently well. (Compare with Case 65 in the Inoperable successes, detailed history given above.)

References: 29, 108.

CASE 31: *Diagnosis:* Recurrent inoperable sarcoma of the chest wall, involving the pectoral region to the clavicle, with metastases in the fourth finger of the right hand.

Previous History: H. S. P., unmarried male, age 26, of Baltimore, Maryland. The family history was negative. The patient had had no diseases up to his twentieth year. He had always been strong and robust. Onset, in 1895, a small mass appeared on the fourth or fifth rib under the right arm. This grew rapidly involving the right axilla and the right pectoral region up to the clavicle.

Surgery: At the end of a year it was partially removed. The remains of the tumor continued to grow and a second incomplete operation was performed 18 months after the first. This was $3\frac{1}{2}$ years prior to admission. At this time another tumor appeared on the fourth finger of the right hand. This finger was amputated (the third operation).

Clinical Course: Eighteen months after this operation another recurrent tumor appeared on the back of the right hand and steadily increased in size.

Toxin Therapy: (Parke Davis IX) Injections were begun in October, 1901, by Dr. Edgar M. Parlett of Baltimore and were given into the tumor and into the shoulder. They were continued by him until January, 1903. (The dosage and frequency were not recorded, nor the type of reaction elicited). For four or five months there was no evidence of improvement.

Radiation: X-ray therapy was also tried without result. About November, 1902, another recurrent mass appeared just below and to the medial side of the right nipple, steadily increasing in size.

Further Toxin Therapy: Injections were continued and were given into the tumor masses and into the shoulder. During this time the tumors diminished but never disappeared.

Clinical Course: No toxins were given during the first three months of 1903. The patient was admitted to Memorial Hospital on March 30, 1903.

Further Toxin Therapy Combined With X-Ray: Injections were resumed by Dr. William B. Coley on March 30, and were given daily or five or six times a week for four months in doses of 0.5 to 4.5 minims. A total of 73 injections were given in a period of 117 days. X-ray therapy was also given about four times weekly.

Clinical Course: The patient was discharged improved on August 1, 1902. After his return home apparently no injections were given for about two months.

Further Toxin Therapy Combined With Further Radiation: Injections were resumed by Parlett early in October, 1903, and were continued that autumn and winter, using both the Parke Davis IX and the Buxton VI preparations. The latter was not begun until March 28, 1904. The patient also received x-ray therapy every other day. Parlett wrote Coley: "I succeeded in reaching a maximum dose of 4½ minims on June 21, 1904, when he was severely burned by x-ray and I was obliged to reduce the dosage. Later he went to Atlantic City for several weeks and improved very much. I began again August 9 and reached a maximum of 4 minims. It took 55 injections into the tumor in the axilla before it broke down and abscessed on October 4, but only four injections into the hand before it broke down. I opened under the right nipple and found about a half cup of pus (with a most fearful odor). This relieved him very much and he has been bright as a dollar ever since." Parlett noted in his letter of November 3, 1904, that both the tumor in the axilla and the one in the hand were still discharging. He added: "There is but one complaint to make against the toxins — it excites the most depressing nausea and often vomiting also. The patient claims he was not so affected during his treatment at Memorial Hospital. The growth under the right nipple has disappeared. Generally speaking, Mr. P.'s condition is very good."

Clinical Course: Apparently the disease remained stationary for several months but was not permanently controlled. Death occurred from pulmonary metastases on July 16, 1906, 11 years after onset.

Note: Compare this case with those in series A in which little or no radiation was administered.

References: 2, 41, 73.

CASE 42: *Diagnosis:* Twice recurrent angiosarcoma of the nasopharynx, with metastases in the lymph nodes, confirmed by microscopic examination at Memorial Hospital by Dr. W. C. Clark and Dr. John McWhorter, from specimens excised from the nares and from a lymph node, September, 1911.

Previous History: J. A. M., male, age 21, of Knoxville, Tennessee. The family history was non-contributory. The patient had a large number of siblings.

He had the usual diseases of childhood but no serious illness. Onset, the fall of 1906, the right nares became stopped.

Surgery: The first operation was performed two years later, through the mouth, a small mass being removed from the nasopharynx. About a year later, 20 months prior to admission, a second operation was performed through an incision on the cheek, a growth the size of a guinea hen's egg being removed. A recurrence developed and a mass in the nares became visible about six months after this operation. This was painless although it caused bulging of the right cheek and the right side of the nose. Examination on admission to Memorial Hospital showed the patient was well nourished. There was a 2½ inch cicatrix on the cheek, and a mass protruded from the nares about ¾ inch, being about ½ inch in diameter.

Toxin Therapy: (Tracy XI) Injections were begun by Dr. William B. Coley on September 5, 1911, at Memorial Hospital, and during the next week four were given in minute doses, intramuscularly, the sites being the chest, shoulder and pectoral region. These caused no reactions. The patient was then discharged and returned home, where intramuscular injections were continued daily for about a month and then only given occasionally. Dr. A. L. Rule, the family physician, wrote Coley on February 24, 1912, that the patient had been improving steadily under toxin therapy and that he had gained 20 pounds.

Clinical Course: The improvement proved only temporary. The disease progressed and the patient died March 9, 1916, of multiple metastases. Death occurred nearly 10 years after onset, and nearly five years after toxin therapy was begun.

Comment: This case indicates the need for more aggressive initial treatment, as well as the danger of suspending treatment too soon. Note that while at Memorial Hospital only small doses were given intramuscularly without any reactions. Unfortunately, in cases where recurrence or metastases developed during or following a course of toxins, the physician seldom resumed treatment and pushed it to the limit of tolerance. However, in almost every case where the toxins were resumed promptly and given persistently the disease was controlled, and there was no further recurrence.

References: 2, 41, 73.

SERIES C: OPERABLE SUCCESSES

The following 35 cases are the only known patients with operable sarcoma of the soft tissues other than lymphosarcoma (in which the diagnoses were confirmed microscopically) who were successfully treated by Coley's toxins given before or after operation. The first 17 were primary operable, the last 18 recurrent operable. Of these cases, 3, 10, 14, 16, 17 also had a small amount of radiation, case 31 somewhat more. In case 12, concurrent pregnancy was a complication; case 16 developed three other types of neoplasm, endometrial polyps, cystic adenoma and a basal cell carcinoma of the face, 17, 19 and 27 years after onset of her sarcoma; cases 1, 23, 29 and 34 also developed other types of neoplasm, 57, 15, 27 and 22 years after onset of their sarcomas, respectively. One developed basal cell carcinoma of the face, one case developed carcinoma of the prostate, and two developed carcinoma of the stomach; cases 18, 27, 28 and 34 appear to be the only recurrent operable sarcomas of the soft tissues to receive toxin therapy alone without further surgery, that remained well. (Case 10 in the Failures, Series D, recurrent, also regressed completely, but the disease recurred again later.)

SERIES C: OPERABLE SUCCESSES

1. *Davies:* Mrs. O. C. S. D., female, aged 35, 10/1/00; fibrosarcoma abdominal wall 4" long; onset 8/00; surgical removal 9/15/00; toxins (Buxton VI) given for 6 weeks in vicinity of cicatrix; no recurrence; in good health next 57 years; basal cell carcinoma developed on cheek, excised 9/13/57; last traced at 92, 1/58. (References: 41, 81). 57½
2. *Coley:* L. I., female, aged 19, 7/23/07; sarcoma groin; date onset not recorded; surgical removal 6/20/07; toxins (Buxton VI): 18 in 32 days, no recurrence; alive and well 1915. (73, 41). 8
3. *Lunding-Smith:* Male, aged 10, 1909, extensive synovioma popliteal space involving capsule of knee joint; date onset not recorded; surgical removal, with considerable part of capsule of knee joint; prolonged course of toxins (Tracy XI) after operation; few x-ray treatments; no recurrence; alive and well 1913. (29, 42). 5
4. *Coley:* V. T., male, aged 39, myxosarcoma left scapular region; onset 9/09; surgical removal; toxins (Tracy X) in left shoulder in region of former growth for over three months, at first daily; no recurrence; in good health until late 1943; died 7/24/44, at 75, of "uremia, due to hypertrophy of prostate." (29, 41, 81). 35½
5. *Harmer:* L. A. W., male, aged 55, 12/5/10; extensive small round cell sarcoma antrum and ethmoid infiltrating in all directions whole nasos- antral wall destroyed; onset 7/10; two operations, 10/14/10 and 11/28/10; toxins (Tracy XI); 49 injections in 5½ months; reactions often severe; no recurrence; in good health 12/12/11; not traced after 1915 (no record of death in Massachusetts next 35 years). (71a, 58, 59). 5
6. *Coley & Fisher:* B. C. C., male, aged 7, 12/29/10; fibrosarcoma nerve sheaths involving pectineal muscle and glands of groin, of rapid growth; onset 11/10; surgical removal 12/4/10; possibly recurrent in inguinal region; toxins (Tracy XI and XII) for 3 months; gained weight during treatment; no recurrence; alive and well 1958. (29, 81, 108). 48
7. *Haines:* Mrs. R., female, aged 26, 1911; round cell sarcoma breast; onset 1/11; surgical removal breast, pectoral muscles and gland-bearing fat in axilla; toxins (Tracy XI) for 1 year; gained 50 pounds; no recurrence; well when last seen 1929; died unknown causes about 1933. (41). 22
8. *Reilly:* H. C. S., male, aged 34, 1915; small cell sarcoma head of colon; onset 1915; 18 inches ileum and cecum removed at operation; toxins (Tracy XI); duration not recorded; no recurrence; died coronary embolism at 70, 4/1/50. (2, 41). 35
9. *Calkins:* Mrs. O. L., female, aged 28, 1/1/15; extensive sarcoma nearly filling pelvis, involving upper portion of vagina; onset 5/15, 11 months after abdominal hysterectomy for "large rapidly growing uterine fibroid"; complete surgical removal via vagina and lower median incision; toxins (Tracy XI) for 9 months; alive and well 1933. (42). 19
10. *Coley:* J. R., male, aged 35, 6/24/21; fibrosarcoma thigh, size of grape-

SERIES C: OPERABLE SUCCESSES

- fruit; onset 5/20; hip-joint amputation advised by Mayos, Deaver, Murphy, Bloodgood; Coley advised exploration, removal found possible 6/21; toxins (Tracy XI) for 6 months; 5 x-ray treatments; gained 66 pounds; no recurrence; alive and well 1958. (41, 71a, 73, 81). 38
11. *Ward*: W. W., male, aged 42, 9/29/10; mixed cell sarcoma calf of leg; onset 10/09; surgical removal 9/4/10; toxins (Parke Davis XII); 65 injections in 8 months with an interval of six weeks' rest; no recurrence; remained healthy until death acute cardiac failure, aged 80, 2/14/49. (2, 81, 109b). 39
12. *Coley & Levine*: Mrs. B. K., female, aged 34, 6/19/20; neurogenic sarcoma deltoid region right arm, size small orange; onset 12/18; first operation 6/20; toxins (Parke Davis XIII); 75 in 90 days, all in pectoral region except 3 in outer limits of tumor area; recurrence; 2nd operation 2/21; patient 3 months' pregnant; 2nd recurrence (grew faster after confinement; pain in both axillae; toxins, radium (7900 mch. inserted into tumor) continued 1 year; another slight recurrence; toxins resumed, given more aggressively, caused marked reactions; total duration 3½ years; no further recurrence; fractured that arm at site of former growth 11/20/48; in excellent health 1958. (41, 73, 81). 38
13. *Coley*: Mrs. J. M., female, aged 34, 11/22; fibrosarcoma size of small egg in right groin; onset, 4/22; radium was administered (no details given); toxins for several weeks (Parke Davis XIII); complete recovery; no recurrence; alive 1958, at 80 years. (41, 81). 36
14. *Lilienthal*: L. F. B., male, aged 44, 6/10/24; spindle cell sarcoma lower chest wall; (date of onset not recorded); 1 large x-ray treatment (erythema dose); surgical removal; toxins (XIII) for six weeks; no recurrence; developed lipoma 1936, excised, recurred two years later; died suddenly heart attack 3/20/51. (81). 27
15. *Crawford*: J. P. C., male, aged 60, 1/6/27; myxosarcoma posterior to tibia, anterior to muscles and calf of leg, size of hen's egg; onset 11/26; surgical removal; toxins (XIII); 19 intramuscular injections in 34 days; no recurrence; alive and well 1945; died cerebral hemorrhage 2/9/51. (81). 24
16. *McCreery*: M. A. J., female, aged 30, 10/1/27; mixed spindle and giant cell sarcoma thigh; onset 5/27; biopsy 6/20/27; surgical removal 6/27/27; severe staphylococcus infection for 9 days; 1 radium pack treatment; severe skin reaction; toxins (XIII); 16 intramuscular injections in 60 days; recurrence 11/27; wide excision; further toxins (intravenous) for 6 weeks; no further recurrence; radiation menopause 1944 for menorrhagia due to endometrial polyps; 1946, thyroidectomy for cystic adenoma; 1954 small basal cell carcinoma excised from forehead; in excellent health 6/20/58. (81). 31
17. *Coley*: O. C., female, aged 10½, 11/24/33; neurogenic sarcoma fascia lata; onset 10/33; surgical removal 11/11/33; 2 radium pack treatments (10,000 mch.); further toxins for nearly two years; no recurrence; married 1949, had two children; in good health 1/20/56. (41, 81). 22½

SERIES C: OPERABLE SUCCESSES

18. *Coley*: Mrs. D. L., female, aged 40; 3/99; thrice-recurrent sarcoma cheek; onset 6/97; excision; prompt recurrence; 2nd operation; 2nd recurrence; 3rd operation; again recurred; toxins (Buxton VI) given into 3rd recurrence; complete regression; no further recurrence; alive and well fall 1917. (16e, 29, 73, 81). 18

19. *Coley*: Male, aged 6, 1899; thrice recurrent spindle-cell sarcoma palm of hand, with axillary metastasis; onset 1898; excision, then amputation of ring and little fingers, and metacarpals; recurrence quickly followed each operation; fall 1899 axillary metastasis appeared and was removed; toxins (Buxton VI) for three months; no further recurrence or metastases. (16f). 3

20. *Matagne*: (Sex not stated), age 36; 1907; (date of onset not given) primary sarcoma left breast excised; rapid recurrence; toxins given for recurrence (locally); 2nd operation; no further recurrence; well and free from disease 1913. (71g). 6

21. *Coley*: Miss K., female, aged 22, 7/06; four times recurrent sarcoma breast; date of onset not recorded; 4 operations by Kammerer had been followed each time by rapidly growing recurrences; toxins (Tracy X) given for 4th recurrence; 2 small masses then excised; a final small recurrence was removed; toxins continued by family physician; no further recurrence; well 1931. (29, 42). 25

22. *Coley*: E. M. A., male, aged 46; 12/10/07; recurrent mixed cell sarcoma triceps muscle; onset 9/07; excision 10/07; prompt recurrence; removed 11/07; toxins (Tracy XI) for three weeks, did not prevent second recurrence; larger doses, some into tumor, caused marked regression, softening; necrotic tumor evacuated; toxins resumed for 3 weeks; another recurrence developed; not controlled; shoulder joint amputation; no further recurrence; died chronic nephritis and uremia 6/21/13. (2, 41, 42, 73, 110b). 6

23. *Green*: J. McG., male, aged 31, 7/21/08; recurrent ulcerated myxosarcoma of the dorsal right wrist, involving ulna; onset 1/07; enucleation 12/15/07; prompt recurrence, ulcerated; toxins (XI) daily into tumor for one week; no effect; amputation at elbow 2/1/08; further toxins for four months; no further recurrence of the sarcoma; developed carcinoma of stomach, causing death 5/26/23. (2, 54a, 71a). 17

24. *Lutman*: J. S. K., male, aged 17, 2/08; six times recurrent sarcoma nasopharynx; onset 1906; six operations; removal difficult each time and rapid recurrence followed each operation; toxins given three months for sixth recurrence (Tracy XI); tumor then removed surgically with little difficulty (had become necrotic from toxins); no further recurrences; in excellent health 1/9/58. (29, 41, 81). 51

SERIES C: OPERABLE SUCCESSES

25. *Oliver*: Female adult, 4/29/09; twice recurrent spindle-cell sarcoma left axilla, supraclavicular metastases; onset date not given; three operations, 2/07, 1/09 and 4/09; 30 doses toxins (Tracy XI) in three months; metastatic masses reappeared after third operation and were present when toxins begun, but disappeared four weeks after toxins stopped; no further recurrences; alive 10/11. (84a). 5
26. *Barnes*: B. M., female, aged 12; 3/20/10; recurrent small spindle cell sarcoma of muscle and fibrous tissue over upper end of humerus; onset 9/08; excision 1/30/09; recurrence; 2nd excision 2/6/10; toxins begun six weeks later (Tracy XI); developed typhoid fever; 2nd recurrence developed, of less rapid growth; excised 11/17/10; toxins resumed; further small recurrence of less rapid growth; fifth excision 7/3/11; toxins continued with intervals of rest through part of 1912, or about two years; no further recurrence until 2/16; excision; further toxins; patient married, had 1 child; later developed pulmonary tuberculosis, also severe pneumonia; death 3/19, apparently due to tuberculosis; no further recurrence of sarcoma. 10 1/2
27. *Coley*: Mrs. H. W., female, aged 25, 3/4/12; extensive recurrent fibrosarcoma right arm, apparently of fascial origin, beginning to involve periosteum of humerus; onset 4/09; removed surgically 11/10; rapid recurrence 7" long involving 3/4 of circumference of arm, considerable limitation of motion at elbow; toxins (Tracy XI) into tumor and both arms and both pectoral regions; continued by family physician; total duration about 20 months; growth regressed; no further recurrence; alive and well 1918. (29, 73). 9
28. *Coley & Murray*: Mrs. O. S., female, aged 43, 3/11; recurrent spindle-cell sarcoma of the parotid; onset spring 1909; excision 6/09; x-ray therapy given July, August, 1909; recurrence supraclavicular and cervical lymphadenopathy; toxins (Tracy XI and XIF) given 8 or 9 months with intervals of rest; complete recovery; no further recurrence. Alive and well next 47 years; died acute auricular fibrillation 3/22/56, at 90 years of age, 48 years after onset. (29, 41, 81). 47
29. *Buteau*: W. K. S., male, aged 47, 10/3/13; recurrent large round cell sarcoma popliteal region; onset 9/15/12; incision, drainage 10/31/12; amputation 1/18/13; recurrence in stump; debridement; toxins (Tracy XI) for nine months with intervals of rest; stump broke down again early in 1918 and was incised; toxins resumed 4/18; given another year; no further recurrence; died 5/24/35 of chronic myocarditis. (2, 81). 23 1/2
30. *Coley*: R. N. G., male, aged 28, 1/10/18; recurrent myxosarcoma (neurogenic) calf of leg; onset early 1916; excision, recurrence two years later; removed with great difficulty when 3" by 5" in size; extensive wound fulgurated; toxins (Tracy XI) started on third post-operative day; given intramuscularly for nine months, marked febrile reactions, chills; no further recurrence; married, had three children; well next 27 years. Died carcinoma of prostate 9/5/45. (2, 73, 81). 29

SERIES C: OPERABLE SUCCESSES

31. *Coley:* J. St. A., male, aged 57, 10/18/19; thrice recurrent neurogenic sarcoma flexor surface left forearm; onset fall 1916; primary excised; recurred locally in nine months; again excised; 2nd recurrence in 9 months; was also size of walnut when removed; third recurrence; 20 x-ray treatments Jan. to Oct., 1919; exploratory operation; toxins (Tracy XI): 23 in 34 days; radium pack treatment (8,250 mch.): bare tubes radium inserted; some slight improvement; amputation at upper third humerus; post-operative infection, drainage for five weeks; further toxins for two months; no further recurrence; died myocarditis, chronic nephritis, influenza, 2/10/29. (41, 73). 13
32. *Ochsner:* Male, aged 10, 1917; recurrent sarcoma antrum; date of onset not given; primary tumor removed surgically in Seattle; recurrence; prognosis practically hopeless; second operation; toxins (Parke Davis XII) few months; no further recurrence; in good health 1932. (81). 15
33. *Ochsner:* E. H., male, aged 18, 1/13/18; small round cell sarcoma left breast; recurrent in upper angle of scar over pectoralis major; onset 4/15; primary removed 7/15; recurred two years later; 2nd operation 11/23/17; toxins (Parke Davis XIII) intramuscularly above left breast and in left arm; no further recurrence; in good health 1955. (81). 40
34. *Coley:* E. R., male, aged 44; recurrent round cell sarcoma left thumb; onset 6/21; primary growth size cherry stone removed surgically 10/17/21; amputation proximal phalanx 10/24/21; recurrence in posterior and metacarpal bone; toxins (XIII) for six months; recurrent tumor regressed completely; no further recurrence; 1942 or 1943 developed carcinoma stomach; operation 8/21/43 in Massachusetts; died post-operative shock. (2, 41, 81). 22
35. *Grey Turner:* M. I. N., female, aged 13; recurrent alveolar sarcoma vastus externus muscle right thigh; onset about 10/1/20; size of large orange when first widely excised; toxins after operation (only 2 doses: $\frac{1}{4}$ and $\frac{1}{2}$ minim); rapidly growing local recurrence 11/22; extensive removal tumor 5" x 8" in diameter, 12/19/22; toxins (Parke Davis XIII), 15 doses in 7 weeks; excellent recovery; no further recurrence; alive and well 8/56. (81). 36

SERIES C. DETAILED HISTORIES OPERABLE SUCCESSES.

CASE 13: *Diagnosis:* Fibrosarcoma in the right inguinal region, confirmed by microscopic examination by Dr. Timothy Leary of Tufts Medical School, Boston, Mass., who reported: "Interlacing bundles of elongated cells whose cytoplasm stains faintly, cell nuclei are long, oval and vesicular. A few mitotic figures were found."

Previous History: Mrs. J. M., female, age 44, of Bellows Falls, Vermont. One sister died of diabetes. The family history was otherwise non-contributory. The patient had measles as a child, but remembered no other early illness. Menses began at 13, a regular 21-day cycle. The patient suffered from gastric ulcers during her early twenties. She married and had two children, born when she was 37 and 40 years of age. She had influenza and pneumonia in March 1922. Onset, shortly thereafter she noted enlarged glands in the right groin.

Surgery: These increased slowly in size, the mass being the size of a small egg when removed at operation on October 3, 1922, by Dr. O'Brien of Bellows Falls, Vermont. The patient was referred to Dr. William B. Coley in November, 1922. Examination revealed a recent cicatrix in the right inguinal region and no palpable adenopathy. The patient was admitted to Memorial Hospital.

Radiation: Radium treatments were then given. The details are not available but a sufficient amount was administered so that the patient did not menstruate thereafter.

Toxin Therapy: (Parke Davis XIII) Injections were begun at Memorial Hospital in November, 1922, and were given daily until her discharge home a week later. They were given intramuscularly and did not produce any particular reaction except slight fever. After her return home they were continued twice weekly by the family physician for several weeks, producing painful indurations in both gluteal regions. The final injection caused a severe reaction and chill, with a fever of 103° F. (The patient's normal temperature was 97° F).

Clinical Course: The patient made a complete recovery. She remained well until January, 1928, when x-rays showed a filling defect in the stomach. She had attacks of severe pain at night, consistent with possible gastric ulcer and also severe pain in the elbows and from the knees down, apparently rheumatoid arthritis. Between 1928 and 1953 the patient also suffered from hypertension and indigestion, and she stated she had had an operation for sinus trouble which was successful. On April 1, 1955, the patient fell, breaking her right wrist. On May 5, 1955, she had a slight cerebral hemorrhage from which she recovered. At this time the normal weight was 120 pounds, the height 5 feet 2 inches. In October, 1957, she had a heart attack and within a few months another one. Her mind became confused, and she was placed in a nursing home. She was last traced on June 24, 1958, with no evidence of recurrence, at the age of 70 years. This was 36 years after onset of the sarcoma.

References: 41, 81.

CASE 16: *Diagnosis:* Mixed spindle-cell and giant cell sarcoma of the thigh, confirmed by microscopic examinations by Drs. Douglas Symmers, James McWhorter, William C. Clarke, James Ewing, and A. F. Stout, who reported it to be a "highly polymorphic connective tissue tumor."

Previous History: M. A. J., female, aged 30, of New York City. The patient's mother died of carcinoma of the breast, a maternal aunt of carcinoma of the colon, a paternal aunt of carcinoma of the endometrium of the uterus, prior to 1927. The patient's only sister developed adenocarcinoma of the breast in 1957. There was no known history of tuberculosis, diabetes or allergy in the family. The patient's father, grandmother and aunt died of coronary occlusion, and a brother later also had a coronary occlusion. The patient had measles and pertussis as a child. Her tonsils and adenoids were removed at the age of seven, and again at 26 because of "many sore throats." The patient first menstruated at the age of ten, a regular 28-day cycle, the periods lasting six or seven days. She contracted mumps at the age of 23 years. She studied medicine and was taking her internship in 1927. In May, 1927, she was injured while surf bathing. She was thrown upon the beach by a wave and received a slight injury to the posterior surface of the thigh, mid-way between the hip and the knee. Onset, following this injury a swelling developed which was thought to be a hematoma.

Surgery: On June 20, 1927, a biopsy was performed at the Bellevue Hospital. A week later the soft friable mass was excised.

Concurrent Infection: The following day, a severe staphylococcus infection developed in the operative wound. The patient ran a temperature up to 104° F. for nine days. Following this infection the wound healed very slowly.

Radiation: One radium pack treatment was then given at Memorial Hospital at the suggestion of Ewing and Duffy. This caused a severe skin reaction but no permanent skin changes. (However, in 1946 the irradiated skin was excised.)

Toxin Therapy: (Parke Davis XIII) Injections were begun by Dr. J. A. McCreery about October 1, 1927, and a total of 16 were given intramuscularly in the next 60 days. The maximum dose was 10 minims, the maximum febrile reaction was 101° F., and chills occurred on six occasions.

Clinical Course: A recurrence developed in November, 1927, while the toxins were being administered. On November 22, 1927, this recurrent mass was widely excised.

Further Toxin Therapy: Injections were resumed in January, 1928, and this course was given by the intravenous route twice weekly for about six weeks, the initial dose being 1/20 minim. Each produced a good febrile reaction (usually 103° F.) and a chill. After 12 injections were given they were stopped as the patient found it difficult to keep up her work as an obstetrical resident while continuing treatment.

Clinical Course: There was no further recurrence. The patient remained in very good health except for the following conditions during the next 25 years: she developed chicken pox in 1932 at the age of 35; she became overweight in 1939 — her weight being 175 pounds, her height 5 feet 5½ inches. During the next two years she reduced in weight to 120 by dieting. By 1947 she weighed 138 which was maintained for five years. In 1944 a dilatation and curettage was performed and a radiation menopause was induced for menorrhagia due to

endometrial polyps. In 1946 a thyroidectomy was performed for a cystic adenoma. In 1953 and 1954 she had two very complete checkups, including skeletal and chest x-rays, and "none of these showed any pathology aside from what one must expect with increasing years." During August, 1954, a small basal cell carcinoma was removed from her forehead. The patient was last seen in excellent health on June 25, 1958, 31 years after onset of the sarcoma.

Reference: 81.

SERIES D: OPERABLE FAILURES

The following 14 cases are the only known patients with operable sarcoma of the soft tissues that were unsuccessfully treated by Coley's toxins given before or after operation. The first 7 were primary, the last seven recurrent when the toxins were begun. Nine of these cases also had considerable radiation. (Bibliography reference numbers follow each case abstract.)

*Period of
Survival*

1. *Green:* T. J. G., male, aged 24, 2/10/08; round cell sarcoma left arm above elbow; onset 6/07; excision 2/8/08; amputation refused; toxins (Tracy XI): small doses intramuscularly thrice weekly for 7 weeks; slight febrile reactions; recurrence in elbow joint; shoulder joint amputation advised, finally performed; death 2/1/09; listed as due to "phthisis, post-operative condition for sarcoma." (2, 54, 71a). 20 mos.
2. *Calkins:* N. O., male, aged 20, 9/10/11; large polyhedral cell sarcoma thigh; football injury 9/10; onset thereafter; more rapid growth 6/1/11; osteopathy ("massaged and kneaded it thoroughly"); exploratory incision 9/11; hip-joint amputation 8/28/11; toxins (Tracy XI) almost steadily for 12 months, then at monthly intervals for another 6 months; only mild reactions produced; resumed work; lived on restricted vegetarian diet; subacute pleurisy right lung 2/1/13; death 10/7/13, apparently due to pulmonary metastases. (41). 3
3. *Coley:* D S., male, aged 27, 11/11/20; round cell sarcoma soft tissues over tibia; onset 3/20; biopsy 11/20; toxins (Tracy XI) combined with radium pack (10,000 mch.); 17 injections in 45 days; some febrile reactions to 103° F. to 104° F.; several sinuses drained; complete regression; toxins continued twice weekly another month; gained weight, symptom free 1/19/21; pulmonary metastases, death 6/2/21. (41, 73, 81). 1 1/4
4. *Coley:* M. B., male, aged 19, 12/21/20; fibrosarcoma or neurogenic sarcoma soft tissues over radius, eroding bone; onset 9/20; toxins, 3 1/2 months (Tracy XI and Parke Davis XIII) intramuscularly; circumference of tumor decreased 1 1/4 inches in first 2 weeks; exploratory incision 1/5/21; 3 radium packs (31,400 mch.); disease controlled temporarily; later given further radium by Bloodgood without effect; axillary metastases 4/22; pulmonary metastases; death 5/1/23. (29, 35, 73). 2 3/4
5. *Armstrong:* J M. T., male, aged 80, 9/27/20; fibrosarcoma muscles forearm; date of onset not given; preliminary x-ray therapy; toxins (Parke Davis XIII); given with further x-ray and radium; 38 injections

- in 65 days; little or no reaction except when given into central vascular part of tumor; tumor increased steadily in size; considerable pain; amputation 6/29/20 (growth breaking down); 14 more injections, only 1 marked reaction; pulmonary metastases 12/20; death 2/21. (41, 81). 1
6. *Coley*: M. S., male, aged 77, 11/19/21; diffuse round cell sarcoma, possibly lymphosarcoma or liposarcoma chest wall, involving 9th, 10th ribs and pleura; onset 3/21; exploratory operation 11/11/21; tumor size of half an orange found; capsule tore, free hemorrhage, pneumothorax; 1 radium pack (8,159 mch.); toxins (XIII), 7 doses in about 3 weeks; complete clinical regression, in excellent health 7/7/22; another radium pack given (3,073 mch.); developed metastases chest, abdomen and brain; death 9/18/23. (73, 81). 21½
7. *Mayo Clinic*: J. F. M., male, aged 17; reticulum cell sarcoma (Grade IV) involving planter fascia and muscles right foot in longitudinal arch region, without bone involvement; incisional biopsy, amputation; Toxins (XIV) intravenously; 10 in about 12 days, reactions to 104° F.; metastases in right groin and left scapula apparent 1 month after last dose; 6 more intravenous injections given, severe reactions; x-ray to groin, scapular region, mediastinum, pelvis, left shoulder, to metastatic lesions; 29 treatments in all; generalized metastases thereafter; further extensive x-ray, blood transfusions; death 1 year after onset. (72). 1
8. *Coley*: A. G., male, aged 43, 5/30/96; twice recurrent spindle cell sarcoma right gluteal region, metastases inguinal glands; onset, 5/94; growth size of fist removed at operation 7/8/95; recurrence; 2nd operation; again recurred; mass 6 x 4 inches; considerable edema entire limb; at 3rd operation 5/27/96 entire mass removed, inguinal metastases also removed; toxins (Buxton VI); 17 injections in 38 days; no marked reactions; considerable diminution in swelling of limb, pain decreased; able to walk; recurrence 4/97; toxins resumed for 3 weeks; old cicatrix then excised; no evidence of disease; again recurrence, death. (73). 4
9. *Ansbach*: Mrs. L., female, aged 35, 2/20/20; 4 times recurrent spindle cell sarcoma muscles and fascia over sacroiliac joint; onset prior to 6/18; excision 6/6/18; recurrence removed 9/11/18; thorough course x-ray; again local recurrence; 3rd operation 8/12/19; radium and further x-ray; 4th operation 12/9/20 left gaping wound; toxins (Tracy XI) intramuscularly intermittently for 8-10 weeks. No marked reactions, no effect; death 7/20. (41, 81). 2
10. *Stewart*: R. G., male, aged 27, 2/25/09; recurrent round cell sarcoma psoas muscle involving 3 inch area of inner table of ilium; onset 4/09; surgical removal 8/15/08; recurrence; x-ray therapy every second day; developed erysipelas 11/08, causing arrest of growth; toxins (Parke Davis XII); subcutaneous injections; no reactions; toxins (Tracy XI): only 1 decided reaction; total duration 4 weeks; complete regression in 3 months; gained 40 pounds; well 7 months, further rapid recurrence; death 1910. (41, 102). 2

11. *Harmer*: G. P. C., male, aged 34, 2/21/11; thrice recurrent fibrosarcoma parotid; onset summer 1910; excision 10/10; recurrence in 2 months; 2nd operation; 3 doses toxins thereafter (Parke Davis XII); no reactions; 2nd recurrence 6 mos. later; paralysis right side face, right eyelids; 3rd operation; further toxins advised; not given as patient felt he must return to work at once; 3rd recurrence; toxins for 2 mos. in O. P. D.; good reactions; mass almost completely disappeared in 6 weeks; again recurred; no further treatment; death 5/15/12. (58, 71a). 22 mos.
12. *Coley*: I. A., male, aged 37, 2/10/20; four times recurrent neurogenic sarcoma leg; onset late 1914; primary removed in two operations; recurrence; 3rd operation; 23 x-ray treatments in 1919; no regression, caused deep radiation ulcer $2\frac{1}{2}$ " x 3" wide, marked skin damage; fourth operation (biopsy only); toxins (Tracy XI): 31 intramuscular injections in 49 days, no marked reactions; radium pack treatments totalling 23,687 mch., 2/14/20 to 4/20; biopsy 2/24/20 showed extensive fibrosis, some necrosis; disease involved tibia by 4/5/20; amputation 4/28/20; post-operative toxins; total duration about 8 months; free from further recurrence, in excellent health, gained a lot of weight; dieted, lost 10 pounds; then developed pulmonary symptoms; hemoptysis; pulmonary metastases?; death 10/5/33. (73, 81). 19
13. *Coley*: F. R., male, aged 24, 8/22/24; twice recurrent neurogenic sarcoma right forearm (brachio-plexus muscle); onset 8/23; 2 operations followed by prompt recurrences; 2nd recurrence untreated; wound gaping; toxins (Parke Davis XIII) only 7 intratumoral injections in 16 days; tumor softened and decreased one inch after 1st dose; became more circumscribed; amputation 9/10/24; no further toxins; diffuse pulmonary metastases; death 1/31/27. (73). 41½
14. *Coley & Crandall*: Mrs. F. K., female, aged 40, 5/1/29; recurrent extensive neurogenic sarcoma left thigh; onset 12/26; during her 2nd pregnancy 1928, tumor increased much more rapidly; primary removed surgically when size of grapefruit; recurred (22 cm. in length); x-ray therapy; toxins (Parke Davis XIII) intravenously, 5 doses; definite regression; radium packs (28,000 mch.); further toxins, 8 intravenously; 50% regression evident in four weeks; radium packs (45,000 mch.); toxins intramuscularly and a few intravenously; radiation ulcer 6 x 3 cm. posterior left thigh; another radium pack; further x-ray therapy; some slight improvement; inguinal, abdominal and apparently lung metastases; death 3/30/30. (41, 73). 3¾

SERIES D. DETAILED HISTORY

CASE 12: *Diagnosis:* Twice recurrent neurogenic sarcoma of the right forearm (brachio-plexus muscle), confirmed by microscopic and x-ray examination at Memorial Hospital, before and after amputation (see below).

Previous History: F. R., male, aged 24, carpenter. The family history was negative for malignancy, tuberculosis or syphilis. The father had died of asthma complicated by an accident. In the summer of 1922, the patient strained his arm throwing a baseball. Onset, in August 1923, a year after this injury, the arm began to swell but there was no pain except when the arm was "struck." The swelling was very hard.

Surgery: Examination on admission to Memorial Hospital in August, 1924, showed an incision on the radial border of the right arm with packing. The wound was gaping and felt very hard, especially above and below the central part; the muscle felt tough and infiltrated. The clinical diagnosis of Dr. William B. Coley was "sarcoma of the soft parts, no connection with bone," and this was confirmed by x-ray examination.

Toxin Therapy: (Parke Davis XIII) Injections were begun by Coley on August 22, 1924, the initial dose being $\frac{1}{3}$ minim, which produced an immediate febrile reaction of 105.8° F., similar to that which occurs with an intravenous injection, and 48 hours later the circumference of the arm had decreased one inch and the tumor was softer and more circumscribed. He was given a total of seven intratumoral injections in a period of 16 days, and the reactions were as follows: 105.8° , 102° , 102.8° , 101° , 100.3° , 103.6° , 99.4° F. The dose ranged from $\frac{1}{8}$ to $\frac{1}{2}$ minim. Apparently, Coley did not consider that the improvement warranted further conservative treatment.

Surgery: Amputation was therefore performed on September 10, 1924. "On section the brachio-radialis muscle was found to be the seat of a tumor mass consisting of four nodules each 2 x 2 cms. in diameter, soft on section, pearly gray, and apparently continuous with muscle fibers . . . , peculiar in circumscription of the tumor masses and in the highly cellular structure."

Clinical Course: The patient remained well for about two years and then developed diffuse pulmonary metastases. No further toxins were administered. Death occurred January 31, 1927, $4\frac{1}{2}$ years after onset.

Comment: Note that the pathologist observed a "peculiar circumscription of the tumor masses." This may have been a result of the preliminary brief course of seven intratumoral injections. Such cases should receive injections after surgery as well as before it, in order to produce permanent results.

SUMMARY AND CONCLUSIONS

An analysis of the factors involved in the treatment of inoperable and operable sarcoma of the soft tissues, excluding lymphosarcoma, with toxin therapy (Coley toxins) has been made.

The factors that may influence prognosis in cases treated with toxin therapy have been discussed. The most important factor seem to be the type of toxin that was used. In some cases, only a weak preparation was available at the time the patient was treated. A factor of almost equal importance is the duration of the treatment with the toxins, especially in the inoperable cases. There were a few successes with a weak toxin, if this was administered persistently. The majority of the successful patients had injections every 24 to 48 hours during the early part of the treatment.

A great deal of x-ray or radium therapy was found to have been administered, usually prior to toxin therapy, in many of the patients considered as failures.

The highest percentage of successful results occurred in patients that had a brisk reaction, chills and high fever, 102° - 105° F., following a toxin injection. Results were often satisfactory if injections were given in or near the growth. At the present time, we believe that intravenous injections, alone or combined with a few given in or near the growth when accessible, are the most effective.

APPENDIX

INOPERABLE SARCOMA OF THE SOFT TISSUES

ANALYSIS OF THE 70 SUCCESSFUL CASES; SERIES A.

(Case abstracts will be found on pp. 12-26)

Stage of the Disease when Toxins were begun:

Primary inoperable: 31 cases (#1, 3, 4, 8, 11, 14, 15, 18, 20, 25, 27, 28, 30, 36, 37, 45, 46, 47, 48, 51, 52, 53, 54, 55, 56, 60, 61, 62, 63, 66, 67).

Recurrent inoperable: 32 cases

six times: 1 case (#47)

thrice: 5 cases (#6, 9, 22, 33, 34)

twice: 5 cases (#2, 10, 16, 23, 44)

once: 21 cases (#1, 7, 12, 13, 17, 19, 21, 23, 29, 31, 35, 38, 39, 41, 42, 57, 58, 59, 69)

Metastases Present: 8 cases (#16, 20, 40, 44, 60, 64, 65, 70)

Cachexia Present, or General Condition Poor: 20 cases (#1, 3, 4, 5, 7, 13, 23, 34, 39, 40, 41, 44, 48, 50, 52, 53, 54, 57, 63, 67)

(Two were terminal: #50, 67)

Concurrent Pregnancy: 1 case, (#12 went on to normal confinement)

Concurrent Bright's Disease: 1 case (#30, patient recovered)

Other Treatment Given Prior to Toxins:

Radiation: 7 cases

#33: several courses x-ray; died x-ray cancer 50 years later

42: brief course x-ray caused severe dermatitis

65: 1 x-ray treatment

67: radium, x-ray (a large amount, didn't control it)

68: x-ray (8500 r., caused complete regression)

69: x-ray (did not prevent or control recurrence)

70: x-ray (no apparent benefit)

Surgery: Biopsy and/or exploration: 32 cases (#1, 3, 4, 5, 8, 11, 14, 15, 17, 18, 20, 25, 27, 28, 30, 32, 36, 37, 43, 44, 49, 50, 51, 52, 53, 54, 56, 61, 63, 66, 68, 70)

Incomplete removal: 12 cases (#6, 19, 23, 24, 26, 33, 40, 45, 46, 47, 60, 62)

More than one operation: 17 cases (#2, 5, 6, 7, 9, 10, 16, 19, 22, 23, 24, 32, 33, 34, 35, 47, 69)

Untreated:

Primary inoperable: 1 case (#48)

Recurrent or metastatic (primary removed): 22 cases (#7, 12, 13, 16, 21, 22, 23, 26, 31, 34, 35, 38, 39, 41, 42, 55, 57, 58, 59, 64, 65)

Treatment Given During Toxin Therapy:

Radiation: 2 cases (#32: few x-ray treatments; #33: x-ray, mostly given prior to toxins)

Evacuation Necrotic Tumor Tissue: 7 cases (# 8, 15, 17, 30, 46, 48, 57)

Treatment Given After Toxin Therapy:

Radiation: 2 cases (#28: 136 x-ray treatments in 28 months finally controlled disease; developed x-ray carcinoma some years later, not fatal, alive 57 years after onset sarcoma; #67: x-ray, caused some regression, although both x-ray & radium given prior to toxins caused no benefit.

Surgery: Remains of growth excised: 1 case (#34)

Scar tissue or fibrous stroma excised: 3 cases (#10, 13, 22)

Amputation: 1 case: (#6)

Plastic operation: 1 case (#9)

Recurrence or Metastases Developed During or Shortly After Toxin Therapy With Complete Regression Following Further Toxins: 10 cases: (#6, 14, 23, 39, 41, 56, 57, 65, 66, 67)

Tumor Continued to Regress After Toxins Were Stopped: 7 cases (#1, 3, 5, 7, 56, 63, 64)

Malignancy Destroyed, Fibrous Stroma Remained: 2 cases (#7, 54)

End Results:

Complete Regression Apparently Due to Toxins, Traced 5-62 yrs.: 65 cases.

Complete Regression Apparently Due to Toxins, Traced 4 years: 3 cases (#8, 30, 45)

Control of Disease Due More to Radiation than Toxins: 2 cases (#28, 68)

Other forms of cancer developing 5 to 50 years later: 10 cases

#27: carcinoma of liver, 24 yrs. after onset of sarcoma.

#33: x-ray carcinoma, 20 years after onset sarcoma; repeated surgery, finally shoulder disarticulation; also bronchiogenic carcinoma (heavy smoker); death 50 yrs. after onset sarcoma.

#40: carcinoma in lumbar region at site former sarcoma, 37 years after onset.

#49: carcinoma of stomach 20 years after onset of sarcoma, caused death general carcinomatosis in about 1 year.

#55: epithelioma of hard palate 5 yrs. after onset sarcoma of naris, superior maxilla; not controlled by radium, death 9 yrs. after onset sarcoma.

Note: The above 5 patients died of their second neoplasm, the following 5 did not:

2: epithelioma neck, 59 years after onset sarcoma

#15: basal cell epithelioma nose, 45 years later

#28: carcinoma abdominal wall, multiple, about 8 yrs. after onset sarcoma; excisions. Alive, fairly well 57 yrs. after onset sarcoma.

#50: multiple uterine fibroids 15 years after onset sarcoma of kidney, panhysterectomy; alive 46 years after onset sarcoma.

#70: malignant melanoma 11 yrs. after onset of hemangioendotheliomata; excisional biopsy

In none of the above patients was toxin therapy administered for the second form of neoplasm.

Death Due to Conditions Other Than Cancer: 19 cases

- #51: pneumonia, influenza.
- #15: broncho-pneumonia. also had arteriosclerosis.
- #29: pulmonary tuberculosis.
- #26: herpes, involving Gasserian ganglion.
- #24 and 25: hemorrhage due to gastric or duodenal ulcer.
- #23: "unrelated causes"
- #1, 2, 3, 7, 15, 31, 39, 41, 46, 47, 49, 56: cardiovascular diseases (12 cases)

Alive, Not Too Well: 3 cases

- #50: senile debility, 46 years later
- #54: hypertension, 43 years later
- #57: ulcerative colitis, 45 years later

Alive and in Good Health when last traced 4 to 62 years after onset: 43 cases

- 4, 5, 6, 8, 9, 10, 11, 12, 13, 14, 17, 18, 19, 20, 21, 22, 25, 26, 30, 32, 36, 37, 38, 42, 43, 44, 45, 48, 52, 53, 58, 59, 60, 61, 62, 63, 64, 65, 66, 67, 68, 69, 70.

INOPERABLE SARCOMA OF THE SOFT TISSUES

ANALYSIS OF SERIES B, 67 FAILURES

(See Table 1, p. 38)

Stage of the Disease when Toxins were begun:

Primary inoperable: 15 cases (#3, 6, 17, 18, 19, 24, 27, 37, 38, 41, 46, 47, 51, 53, 56)

Recurrent: 31 cases

- 1 seven times (#7)
- 3 five times (#1, 11, 21)
- 5 thrice (#4, 12, 45, 48, 49)
- 19 once (#5, 10, 13, 14, 15, 16, 22, 26, 34, 36, 37, 41, 43, 44, 55, 59, 62, 65, 67)

Multiple Primary: 1 case (#30)

Metastases Present: 21 cases (#1, 2, 3, 9, 10, 12, 13, 21, 28, 30, 33, 37, 42, 52, 54, 57, 59, 60, 61, 65, 66, 67)

Terminal: 14 cases (#6, 9, 10, 14, 17, 20, 37, 40, 60, 63, 64, 65, 66, 67)

Cachexia Present or General Condition Poor: 11 cases (#15, 24, 25, 30, 34, 46, 52, 54, 55, 62, 63)

Other Treatment Given Prior to Toxins:

Radiation: 10 cases

- #40: x-ray — ineffective
- #46: x-ray (twice weekly 4½ months; tumor doubled in size)
- #59: x-ray (absolutely no benefit)
- #56: radium (gold needles); diathermy, fulgurations (temporary benefit)
- #57: x-ray following excision did not prevent recurrence
- #58: x-ray (46); recurrence increased rapidly during treatment

- #61: radium pack (8000 mch.), x-ray (4) given 12 days after toxins — no decrease in size during this radiation
- #63: x-ray, radium — seemed to aggravate the condition
- #64: x-ray (many courses), also radium (5) over 15 month period: did not prevent recurrence, destroyed eye, lashes, brow.
- #65: x-ray (many courses to various metastatic areas totalling 32,024 r.), patient's natural resistance to his neoplasm was remarkably high (died 8½ years after onset), an unusual case.
- #66: x-ray (4311 r.), radium (1100 mch.), disease not controlled

Surgery:

- #7: six operations
- #1, 11, 21: five operations
- #8, 20: "great many," "several operations"
 - 7 three operations (#20, 31, 33, 35, 45, 49, 56)
 - 10 two operations (#4, 23, 25, 35, 40, 42, 59, 62, 63, 67)
- 11 primary removed usually completely, recurrence or metastases untreated or irradiated: (#2, 10, 26, 29, 34, 36, 40 — recurrence explored, 43, 44, 55, 57, 64)
- 7 incomplete removal of primary: (#5, 13, 19, 31, 41, 48, 65)
- 11 explorative and/or biopsy: (#6, 28, 30, 34, 37, 38, 46, 47, 50, 52, 54)
- 3 amputation (#28, 31, 33)
- 1 electrolytic needles (#24)

Other Treatment Given During or After Toxin Therapy:

Radiation: 10 cases

- #21: x-ray for 6 weeks after 2 courses toxins, complete regression
- #23: x-ray (5) about 2 weeks after toxins begun caused very rapid increase in growth
- #25: x-ray thrice weekly during, often same day as toxins, very rapid improvement
- #28: x-ray (30), 5 weeks after toxins
- #31: 32 x-ray after ulcer healed, during toxins
- #33: x-ray, 5 weekly (began 1 week after toxins given); little improvement
- #54: radium packs (5) between 1st and second course toxins, marked improvement before and after radiation; then sudden death due to hemorrhage
- #55: x-ray (3) before; radium packs (2) during toxins
- #63: (x-ray before); radium pack after (48,000 mch.), lost ground rapidly, much radiation sickness.

Surgery:

- 3 external carotids tied (#19, 21, 23)
- 1 drainage established surgically (#20)
- 1 surgical removal (3rd operation, tumor much less vascular than before: #35)
- 2 incomplete removal (#1, 9)
- 1 metastases, primary removed at 2 operations 2 weeks after toxins (#9)
- 1 cicatrix removed after 2nd course of toxins (no evidence of tumor: #13)
- 1 neck dissection, after toxins (#44, died on the table)

Effects of Toxin Therapy:

Complete Regression: 9 cases

- #7: potent toxins 4 weeks, too rapid absorption necrotic tumor caused persistent nausea.
- #8: potent toxins 3½ years intermittently.
- #12: potent toxins 3 months, resumed briefly later.
- #13: potent toxins 3 months, resumed after further recurrence, again regressed.
- #22: potent toxins 2 months, resumed after recurrence.
- #25: potent toxins 3 courses, with x-ray; later weak toxins; total 1 year.
- #40: potent toxins 3 courses, at first marked reactions, later no reactions (intramuscular).
- #62: weaker product given daily at first intramuscular and intratumoral; total 7 months.

Incomplete Regression: 28 cases

- #1, 2, 3, 4 (marked), 6, 16, 18, 19, 26, 28, 30, 31, 33, 35, 37, 47, 48, 49, 52, 53, 54, 56, 57, 58, 59, 61, 63, 64, 67.

Temporary Arrest of Growth: 9 cases

- #11, 21, 31, 32, 41, 43, 44, 46, 65

Marked Pain Relief: 12 cases

- #13, 15, 23, 24, 26, 28, 37, 41, 53, 59, 64, 67

Cessation of Hemorrhages: 1 case (#19)

Necrosis or Sloughing of Tumor: 9 cases

- #6, 12, 14, 15, 18, 19, 29, 30, 34

Little or No Apparent Benefit: 12 cases

- #5: had only 5 doses
- #10: recurrence 11 by 15 inches, axillary involvement, given intramuscularly remote from tumor.
- #12: terminal, only 7 doses in the 15 days before she died.
- #20: probable lung involvement, primary 5" x 8", only 9 weeks (appetite remained excellent)
- #27: only 2 doses, died after 2nd dose given intra-abdominally.
- #30: terminal, multiple primaries, metastases, arteriosclerosis, chronic nephritis, only 21 doses weak product into tumors.
- #33: weak product given six weeks, during x-ray
- #37: 21 in 42 days in a terminal case
- #38: only 2 doses (child, aged 2) died 3 days after 2nd dose.
- #55: weak product, very small doses intermittently after radium x-ray
- #60: weak product in terminal case, 6 small doses
- #66: terminal uterine, multiple metastases (in shock); 4 doses, little reaction, died 3 days after last dose.

Complications:

Deaths during or soon after toxins:

- 1 typhoid: #4
- 5 became septic: #5, 14, 26, 29, 30 (all prior to 1901)
- 1 necrosis, collapse of tracheal wall: #53
- 2 necrosis, hemorrhage: #45, 54
- 2 collapse (due to toxins?): #27, 38
- 1 radiation necrosis: #8
- 1 uremia due to blocked ureters: #67

Toxemia due to absorption large amounts necrotic tumor: 7 cases

#5, 6, 14, 34, 40, 43, 64. These cases suggest the need for establishing drainage surgically or for incomplete removal of some of the tumor in such cases to avoid this problem.

Late Survivals: 9 cases

In a certain number of cases it would appear that the toxins prolonged the patient's life beyond the expected survival period.

myxosarcoma #8: about 21 years after toxins begun (22 yrs. after onset)

tendon sheath #12: about 4 years after toxins begun (5 yrs. after onset)

thigh, groin #13: about 2 years after toxins begun (4 yrs. after onset)

uterus, broad ligament #15: about 6 years after toxins begun (6½ yrs. after onset)

thigh #16: about 2 years after toxins begun (21 yrs. after onset)

neck, metastases #21: about 2½ years after toxins begun (15 years after onset)

sarcoma ovary #22: 4 years after toxins begun (? yrs. after onset)

sarcoma chest wall #31: 6 years after toxins begun (9 yrs. after onset)

angiosarcoma nasopharynx #42: 5 yrs. after toxins begun (10 yrs. after onset)

BIBLIOGRAPHY

1. ANDREWS, E.: A study of a few suggestive cases. *Chicago Med. Rec.*, 8: 1-8. 1895. (Case 4)
- 1a. BALFOUR, D. C.: The treatment by heat of advanced cancer of the cervix (Percy Method). *Journal-Lancet*, St. Paul, Minn., 35: 347-350. 1915.
- 1b. BATTIE, W. H.: A case illustrating the advantage of Coley's fluid in the treatment of inoperable tumours. *Trans. Med. Soc. London*, 21: 362-364. 1897-1898.
- 1c. BEEBE, S. P. & TRACY, M.: The treatment of experimental tumors with bacterial toxins. *J.A.M.A.*, 49: 1493-1498. 1907.
2. BUREAU OF VITAL STATISTICS DEATH RECORDS: California, Connecticut, Massachusetts, New Jersey, New York, Tennessee. also several cities.
3. BURROWS, H.: Some factors in the localization of disease in the body. London: Bailliere, Tindall & Cox. 1932.
4. BYRNE, J.: Vaginal hysterectomy by galvano-cautery. Remarks on the scope and limitations of the operation. *Amer. J. Obst.*, 32: 556-567. 1895.
5. CALKINS AND FARMER CLINIC: Office Records.
6. CHRISTIAN, S. L. & PALMER, L. A.: An apparent recovery from multiple sarcoma with involvement of both bone and soft parts treated by toxin of erysipelas and bacillus prodigiosus (Coley). *Amer. J. Surg.*, 4: 188-197. 1928. See also: Apparent recovery from multiple sarcomata. *Military Surg.*, 61: 42-47. 1927. (Patient alive 1959)
7. CLUFF, L. E. & BENNETT, J. L.: Acquired resistance to the Shwartzman phenomenon. *Proc. Soc. Exp. Biol. & Med.*, 77: 461-464. 1951.
8. COLEY, W. B.: Contribution to the knowledge of sarcoma. *Ann. Surg.*, 14: 199-220. 1891.
9. COLEY, W. B.: A preliminary note on the treatment of inoperable sarcoma by the toxic products of erysipelas. *Post-graduate*, 8: 287-286. 1893.
10. COLEY, W. B.: The treatment of malignant tumors by repeated inoculations of erysipelas, with a report of original cases. *Am. J. Med. Sc.*, 105: 487-511. 1893.
11. COLEY, W. B.: Treatment of inoperable malignant tumors with the toxins of erysipelas and bacillus prodigiosus. *Trans. Amer. Surg. Assn.*, 12: 183-212. 1894.
12. COLEY, W. B.: The treatment of inoperable malignant tumors with the toxins of erysipelas and bacillus prodigiosus. *Med. Rec.*, 47: 65-70. 1895.
- 12a. COLEY, W. B.: Spindle-celled sarcoma of the abdominal wall successfully treated by the mixed toxins of erysipelas and bacillus prodigiosus. *Ann. Surg.*, 26: 232-234. 1897.
13. COLEY, W. B.: The therapeutic value of the mixed toxins of erysipelas and bacillus prodigiosus in the treatment of inoperable malignant tumors. *Am. J. M. Sc.*, 112: 251-281. 1896.
14. COLEY, W. B.: Further observations upon the treatment of malignant tumors with the mixed toxins of erysipelas and bacillus prodigiosus, with a report of 160 cases. *Bull. Johns Hopkins Hosp.*, 65: 157-162. 1896.
- 14a. COLEY, W. B.: The indications for the non-operative local treatment of

- tumors. The value of toxins. Concord, New Hampshire. Republican Press Assn., 1896. (Case 3, pp. 9-10)
- 14b. COLEY, W. B.: Recurrent round celled sarcoma of the lip treated with the mixed toxins. *Post-Graduate*, 12: 346-348. 1897.
 15. COLEY, W. B.: Inoperable sarcoma cured by mixed toxins of erysipelas. *Ann. Surg.*, 25: 174-177. 1897.
 - 15a. COLEY, W. B.: A case of recurrent inoperable spindle-celled sarcoma of the parotid successfully treated with the mixed toxins of erysipelas and bacillus prodigiosus. *Ann. Surg.*, 28: 244-246. 1898.
 16. COLEY, W. B.: The treatment of inoperable sarcoma with the mixed toxins of erysipelas and bacillus prodigiosus: immediate and final results in one hundred and forty cases. *J.A.M.A.*, 31: 389-395; 456-465. 1898. (See also *Med. Rec.* 54: 294-295. 1898)
 - 16a. COLEY, W. B.: The influence of injury upon the development of sarcoma. *Ann. Surg.*, 27: 259-284. 1898.
 - 16b. COLEY, W. B.: Mixed toxins of erysipelas and bacillus prodigiosus in treatment of sarcoma. *J.A.M.A.*, 34: 906-908. 1900.
 - 16c. COLEY, W. B.: Late results of the treatment of inoperable sarcoma with the mixed toxins of erysipelas and bacillus prodigiosus. *Phila. Med. Journ.*, 7: 1013-1017. 1901.
 - 16d. COLEY, W. B.: The treatment of inoperable cancer. *St. Paul Med. J.*, 2: 365-374. 1900.
 - 16e. COLEY, W. B.: Acute Traumatic Malignancy. *Med. News*, 78: 575-578; 614-618. 1901.
 - 16f. COLEY, W. B.: Late results of the treatment of inoperable sarcoma with the mixed toxins of erysipelas and bacillus prodigiosus. *Trans. Amer. Surg. Assn.*, 19: 27-42. 1901.
 17. COLEY, W. B.: The influence of the roentgen ray upon the different varieties of sarcoma. *Trans. Amer. Surg. Assn.*, 20: 308-334. 1902.
 - 17a. COLEY, W. B.: Small round cell sarcoma of the parotid successfully treated by the mixed toxins of erysipelas and bacillus prodigiosus. *Ann. Surg.*, 35: 421-425. 1902.
 - 17b. COLEY, W. B.: See *Twentieth Century Practice of Medicine. Supplement, Vol. 21. (Case VII, p. 767)* 1902.
 18. COLEY, W. B.: Observations upon the symptomatology and treatment of sarcoma. *Trans. Lehigh Valley Med. Assn.*, 1: 55-78. 1903.
 - 18a. COLEY, W. B.: Final results in the x-ray treatment of cancer. *Ann. Surg.*, 42: 161-184. 1905.
 - 18b. COLEY, W. B.: Amputation of the hip-joint for sarcoma, with a report of seven cases without mortality. *Trans. South. Surg. Assn.* 16: 77-96. 1903.
 19. COLEY, W. B.: Treatment operative and by the mixed toxins. *Brooklyn M. J.*, 20: 313-317. 1906.
 - 19a. COLEY, W. B.: Late results of the x-ray treatment of sarcoma. *Arch. Physiol. Therap.*, 3-4: 161-169. 1906. (p. 166)
 20. COLEY, W. B.: Late results of the treatment of inoperable sarcoma by the mixed toxins of erysipelas and bacillus prodigiosus. *Am. J. Med. Sc.*, 131: 375-430. 1906.
 21. COLEY, W. B.: Inoperable sarcoma: A further report of cases successfully treated with the mixed toxins of erysipelas and bacillus prodigiosus. *Med. Rec.*, 72: 129-137. 1907.
 - 21a. COLEY, W. B.: Sarcoma of the long bones: the diagnosis, treatment and prognosis with a report of sixty-nine cases. *Ann. Surg.*, 45: 321-368. 1907.

22. COLEY, W. B.: Inoperable round cell sarcoma of the back; with metastatic tumor involving a large portion of the lower jaw; entire disappearance under 2½ months' treatment with the mixed toxins. *Ann. Surg.*, 48: 465-468. 1908.
23. COLEY, W. B.: The treatment of sarcoma with mixed toxins of erysipelas and bacillus prodigiosus. *Boston M. & S. J.*, 158: 175-182. 1908.
24. COLEY, W. B.: The treatment of inoperable sarcoma by bacterial toxins. *Proc. Royal Soc. Med., Surg. Sect.*, 3: 1-48. 1909-1910.
25. COLEY, W. B.: The treatment of inoperable sarcoma with the mixed toxins of erysipelas and bacillus prodigiosus. *Trans. New Hampshire M. Soc.*, 225-268. 1910.
26. COLEY, W. B.: A report of recent cases of inoperable sarcoma successfully treated with mixed toxins of erysipelas and bacillus prodigiosus. *Surg. Gyn. & Obst.*, 13: 174-190. 1911.
27. COLEY, W. B.: Disappearance of a recurrent carcinoma after injections of mixed toxins. *Ann. Surg.*, 55: 897-898. 1912.
28. COLEY, W. B.: Inoperable adenocarcinoma of the soft palate, rendered operable by the use of the mixed toxins. *Ann. Surg.*, 58: 559-561. 1913.
29. COLEY, W. B.: The treatment of malignant inoperable tumors with the mixed toxins of erysipelas and bacillus prodigiosus with a brief report of 80 cases successfully treated with the toxins from 1893-1914. *Brussels: M. Weissenbruch.* 1914.
- 29a. COLEY, W. B.: Inoperable recurrent sarcoma of the upper jaw successfully treated with the mixed toxins of erysipelas and bacillus prodigiosus. *Ann. Surg.*, 62: 353. 1915.
30. COLEY, W. B.: Inoperable recurrent tumor of nasopharynx, involving ethmoid, sphenoid, frontal and superior maxillae bones (carcinoma); disappearance under six weeks' treatment with the mixed toxins. *Ann. Surg.*, 62: 353-358. 1915.
- 30a. COLEY, W. B.: Inoperable spindle-celled sarcoma of the superior maxilla; disappearance under 2½ months' treatment with the mixed toxins of erysipelas and bacillus prodigiosus. *Ann. Surg.*, 62: 504-506. 1915.
31. COLEY, W. B.: Primary neoplasms of the lymphatic glands, including Hodgkin's disease. *Trans. Amer. S. Assn.*, 33: 499-644. 1915. (See also *Ann. Surg.*, 63: 35-70. 1916.)
32. COLEY, W. B. & HOGUET, J. P.: Melanotic Cancer; with a report of 90 cases. *Trans. Amer. Surg. Assn.*, 34: 319-383. 1916.
33. COLEY, W. B.: Further observations on the conservative treatment of sarcoma of the long bones. *Ann. Surg.*, 70: 633-660. 1919. (See also *Trans. Am. S. Assn.*, 37: 273-336. 1919.)
34. COLEY, W. B. & COLEY, B. L.: End results in 169 operable cases of periosteal osteogenic sarcoma and endothelioma, including a small group of malignant central sarcoma. *Trans. Amer. Surg. Assn.*, 43: 857-949. 1925.
35. COLEY, W. B. & COLEY, B. L.: Primary malignant tumors of the long bones; end results in one hundred and seventy operable cases. *Arch. Surg.*, 13: 779-836. 1926; 14: 63-141. 1927.
- 35a. COLEY, W. B. & BLUM, D. M.: Large malignant tumor (sarcoma) of the uterus with multiple bone metastases (femur, pelvic bones and skull); Case successfully treated by hysterectomy and Coley's toxins (erysipelas and bacillus prodigiosus). *Am. J. Surg.*, 23: 47-53. 1934.
36. COLEY, W. B.: Sarcoma of the long bones. Clinical lecture on end results.

- Exhibition of patients illustrating end results of treatment. *Surg. Clin. North Amer.*, 9: 583-618. 1929.
- 36a. COLEY, W. B.: Treatment of Bone Sarcoma. *Cancer Review*, 4: 426-436. 1929.
 37. COLEY, W. B.: Endothelial myeloma of tibia; long-standing cure by toxin treatment. *Ann. Surg.*, 93²: 447-452. 1931.
 38. COLEY, W. B.: The treatment of sarcoma of the long bones. *Trans. Amer. Surg. Assn.*, 50: 383-417. 1932.
 39. COLEY, W. B.: Unpublished paper read before the American Association for Cancer Research, November 19, 1934.
 40. COLEY, W. B.: Wilm's Tumor. *Amer. J. Surg.*, 29: 463-464. 1935.
 41. COLEY, W. B.: Office Records. 1892-1936. Now the property of the New York Cancer Research Institute.
 42. COLEY, W. B.: Manuscript for an unfinished monograph on toxin therapy, 1930-1936.
 43. COLEY, W. B.: Diagnosis and treatment of bone sarcoma. *Glasgow M. J.*, 126: 49-86; 128-164. 1936.
 44. COLEY, W. B.: Unpublished paper read before the International Surgical Society, 1/18/35.
 45. COUNCIL ON PHARMACY AND CHEMISTRY, American Medical Association, *J.A.M.A.*, 103: 1067. 1934.
 - 45a. CUSHING, H. & WOLBACH, S. G.: The transformation of a malignant paravertebral sympathicoblastoma into a benign ganglioneuroma. *Amer. J. Path.*, 3: 203-216. 1927.
 - 45b. DA COSTA, J. C.: *Modern Surgery*. Tenth edition. Philadelphia: W. B. Saunders Co. 1931.
 46. DE COURCY, J. L.: The spontaneous regression of cancer. *Journ. Med.*, 14: 141-146. 1933.
 47. DELARIO, A. J.: Methods of enhancing Roentgen-ray action. *Radiology*, 25: 617-627. 1935.
 48. DONNELLY, A. J., HAVAS, H. F. & GROESBECK, M. E.: Mixed Bacterial Toxins in the Treatment of Tumors. II. Gross and Microscopic Changes Produced in Sarcoma 37 and in Mouse Tissues. *Cancer Research*, 18: 149-154. 1958.
 49. DOUB, H. P.: Artificial fever as a therapeutic agent. 25: 360-361. 1935.
 50. DOUB, H. P.: Osteogenic sarcoma of the clavicle treated with radiation and fever therapy. *Radiology*, 25: 355-356. 1935.
 51. DURAN REYNALS, F.: Reactions of spontaneous mouse carcinomas to blood carried bacterial toxins. *Proc. Soc. Exper. Biol. & Med.*, 32: 1517-1521. 1935.
 52. EDITORIAL on Coley's Toxins, *J.A.M.A.*, 103: 1071. 1934.
 - 52a. EMERSON, F. P.: Sarcoma of the tonsil treated with Coley's Toxins. *Laryngoscope*, St. Louis, 17: 212-214. 1907.
 - 52b. EVERSON, T. C. & COLE, W. H.: Spontaneous regression of cancer: preliminary report. *Ann. Surg.*, 144: 366-383. 1956.
 53. EWING, J.: *Cancer Problems*. See Second Report of the Huntington Cancer Research Fund. New York. 1907.
 - 53a. FERRY, N. S. & FISHER, L. W.: Immunizing properties of bacterial antigens prepared after various methods. *British J. Exp. Path.*, 5: 185-198; 205-212. 1924.
 54. FOGG, L. C.: Effect of certain bacterial products upon the growth of mouse tumor. *Public Health Report*, 51: 56-64. 1936.

- 54a. GEORGE, C., Jr.: The treatment of inoperable tumors. *Phila. Med. J.*, 9: 64-69. 1902.
- 54b. GREEN, R. M.: The use of Coley toxins in the treatment of sarcoma. *Boston M. & S. J.*, 165: 1-6. 1911.
55. GREEN, W. E.: The Coley treatment of inoperable sarcoma by the mixed toxins of erysipelas and bacillus prodigiosus. *N. Amer. H. Homeop.*, N. Y., 22: 685-687. 1907.
56. GREENWOOD, H. H.: Note on a case of melanotic sarcoma treated by Coley's fluid. *Lancet*, 2: 881-882. 1912. (Also 1: 25. 1912.)
57. GREGORY, P.: Bacillus subtilis as an antibiotic in the treatment of cancer. *Southern M. J.*, 43: 397-403. 1950.
58. HARMER, T. W.: A study of the efficiency of mixed toxins (Coley) in inoperable sarcoma. A critical analysis of 134 microscopically proven cases. *Boston M. & S. J.*, 172: 331-338; 373-377; 411-416; 440-448. 1915.
59. HARMER, T. W.: Remarks upon the effects observed in the use of the mixed toxins (Coley) in certain cases of sarcoma. *Boston M. & S. J.*, 171: 253-261. 1914.
- 59a. HAVAS, H. F., GROESBECK, M. E., and DONNELLY, A. J.: Mixed Bacterial Toxins in the Treatment of Tumors. I. Methods of Preparation and Effects on Normal and Sarcoma 37-bearing Mice. *Cancer Research*, 18: 141-148. 1958.
- 59b. HERBUT, P. A. & KRAEMER, W. H.: The possible role of the properdin system in transplantable cancer. *Cancer Res.* 16: 1048-1052. 1956.
60. HODENPYL, E.: The treatment of carcinoma with the body fluids of a recovered case. *Med. Rec.*, 77: 359-360. 1910.
61. JACOBI, M.: The effect of Shwartzman reaction with bacterial filtrate in transplantable tumors in animals. *Amer. J. Cancer*, 26: 770-774. 1936.
62. JACOBSEN, C.: Der Chronische Reis des reticuloendothelialen Systems—eine Krebshemmung. (Chronic irritation of the reticuloendothelial system, a hindrance to cancer.) *Arch. F. Dermat. u. Syph.*, 169: 562-576. 1934.
- 62a. JANCOS, M.: Histamine as a physiological activator of the reticuloendothelial system. *Nature*, 160: 227-228. 1947.
63. JARES, J. J. & WARREN, S. L.: The combined effects of Roentgen radiation and fever upon malignant tissue — preliminary summary. *Occasional Publications of the American Association for the Advancement of Science*, 4: 225-226. 1937.
- 63a. JOHNSON, W. B.: A case of sarcoma of the palate successfully treated with the toxins of erysipelas. *Med. Rec.*, 46: 616-617. 1894.
64. LAGUEUX, P.: Le sérum de Coley dans les cas de sarcome ou carcinome ou dans les cas de récurrence après opération. *Bull. Méd. de Québec*, 10: 469-470. 1908.
65. LAMBERT, R. A.: Demonstration of the greater susceptibility to heat of sarcoma cells as compared with actively proliferating connective tissue cells. *J.A.M.A.*, 59: 2147-2148. 1912.
- 65a. LANDY, M. & PILLEMER, L.: Elevation of the properdin levels in mice following administration of bacterial lipopolysaccharides. *J. Exp. Med.*, 103: 823-833. 1956.
66. LARGE, S. H.: Four cases of sarcoma of the nose and throat treated with Coley's toxins. *Cleveland Med. J.*, 10: 318. 1911.
67. LILIENTHAL, H.: Mediastinal sarcoma — treated with Coley's fluid. *Ann. Surg.*, 85: 615-625. 1927.

68. LOHMAN, R.S. *Krebstoffwechsel und Entzündung*. Klin. Woch., 10: 1799-1802. 1931.
69. LONSEN, W. & LIEBERT, E.: Studies on a new pyrogen fever treatment. Illinois M. J., 96: 186-190. 1949.
70. MACKAY, C. G.: A case that seems to suggest a clue to the possible solution of the cancer problem. Brit. M. J., 2: 138-140. 1907.
71. MAGNANT, E.: Cancroïde de la lèvre inférieure guéri par deux injections de lymphé humaine. Revue Med. de l'Est (Nancy), 24: 404-405. 1892.
- 71a. MASSACHUSETTS GENERAL HOSPITAL RECORDS.
- 71b. MATAGNE, J. H. J.: Premiers essais de traitement des tumeurs malignes inopérables par les toxines de Coley: Un cas de cancer guéri. Gaz. Méd. Liège, 8: 401-402. 1896.
- 71c. MATAGNE, J. H. J.: Traitement des tumeurs malignes inopérables par l'érysipèle et les toxines de Coley. Gaz. Méd. Belge; 12: 375-377. 1899-1900.
- 71d. MATAGNE, J. H. J.: Les toxines de Coley employées dans le but de prévenir la récurrence du cancer. Presse Méd. Belge, 54: 1-3. 1902.
- 71e. MATAGNE, J. H. J.: Présentation de cancéreux guéris par les toxines de Coley, employées conjointement avec intervention chirurgicale. Presse Méd. Belge, 57: 173-179. 1905.
- 71f. MATAGNE, J. H. J.: Vers la guérison du cancer. Le Scalpel, 104: 540-544. 1951.
- 71g. MATAGNE, J. H. J.: La guérison du cancer. Scalpel, 106: 1387-1395. 1953.
72. MAYO CLINIC RECORDS.
73. MEMORIAL HOSPITAL RECORDS.
74. MENKIN, V.: Dynamics of Inflammation. An inquiry into the mechanism of infectious processes. New York: Macmillan Company. 1940.
75. MENKIN, V.: Newer concepts of inflammation. Springfield, Illinois: Charles C. Thomas. 1950.
- 75a. MERIWEATHER, F. T.: Some remarks upon Coley's treatment of malignant growths. Louisville Monthly J. M. & S., 6: 173-177. 1900. (Case 1)
76. MEYER, W.: Cancer. New York: Paul B. Hoeber. 1931.
- 76a. MOULLIN, H. M.: The treatment of sarcoma and carcinoma by injections of mixed toxins. London: John Bale Sons & Danielsson. 1898.
- 76b. MYNTER, H.: Sarcoma of the abdominal cavity cured by the toxins of erysipelas. Med. Rec., 47: 167-168. 1895.
77. NAUTS, H. C., SWIFT, W. E., & COLEY, B. L.: Treatment of malignant tumors by bacterial toxins as developed by the late William B. Coley, M.D., reviewed in the light of modern research. Cancer Research, 6: 205-216. 1946.
78. NAUTS, H. C. & COLEY, B. L.: A review of the treatment of malignant tumors by Coley bacterial toxins. See: Approaches to Tumor Chemotherapy, A.A.A.S. Publications, 1947. (pp. 217-235)
79. NAUTS, H. C. & FOWLER, G. A.: Studies of the effects of Bacterial Products or of Acute Bacterial Infections on Malignant Disease; Bibliography on the effects of acute bacterial infections, inflammation, fever or heat, whether occurring spontaneously or induced artificially. (496 references, with brief foreword.) Lakeville, Conn., Lakeville Journal, 1952.
80. NAUTS, H. C., FOWLER, G. A. & BOGATKO, F. H.: A review of the Influence of Bacterial Infection and of Bacterial Products (Coley's Toxins) on Malignant Tumors in Man. Acta Medica Scandinavica, Vol. 145, Suppl. 276. Stockholm, 1953.

81. NEW YORK CANCER RESEARCH INSTITUTE RECORDS: Communications from the patients, their physicians or their relatives.
82. NEW YORK HOSPITAL RECORDS.
- 82a. NICHOLSON, C. M.: Report of four cases of sarcoma treated by injection of erysipelas and prodigiosus toxins. *Amer. J. Surg. & Gyn., (St. Louis), 13*: 10-11. 1899.
83. NOON, L.: The influence of site of inoculation on the immunity produced. *Lancet*, 2: 396. 1909.
- 83a. ODIER, R.: Traitement des affections sarcomateuses par les toxins de M. Coley. *Rev. Méd. de la Suisse Rom. (Geneva)*, 28: 649-654. 1908.
84. OKUNEEF, N.: Studien uber parenterals Resorption V. Mitteilung: Uber die Resorption des Farbstoffs Trypambau aus dem subkutanen Bindegewebe. *Biochem. Zeitschr.* 226: 147-156. 1930.
- 84a. OLIVER, J. C.: Results obtained from the use of Coley's toxins in the treatment of sarcoma. *Ohio M. J. (Columbus)*, 7: 483-489. 1911.
85. OVERGAARD, K. & OKKELS, H.: Action of dry heat on Wood's Sarcoma. *Acta Radiologica*, 21: 577-582. 1940.
- 85a. OWEN, J. E.: The use of toxins in Sarcoma, *Chicago Med. Recorder*, 8: 119-122. 1895. (See also *Trans. Illinois Med. Soc. (Chicago)*, 218-227. 1897. (Case 2))
86. PALMER, C. W.: Treatment of Sarcoma with the mixed toxins of erysipelas and bacillus prodigiosus. *J. Ophthal. Otol. and Laryng.*, 12: 214-220. 1900.
- 86a. PENNSYLVANIA HOSPITAL RECORDS. Philadelphia Pa.
87. PERCY, J. F.: Heat in the treatment of carcinoma of the uterus. *Surg. Gyn. & Obst.*, 22: 77-79. 1916.
- 87a. PILLEMER, L., BLUM, L., LEPOW, I. H., ROSS, E. A., TODD, E. W. & WARDLAW, A. C.: The properdin system and immunity. I. Demonstration and isolation of a new serum protein, properdin, and its role in immune phenomena. *Science*, 120: 279-285. 1954.
- 87b. PILLEMER, L., LANDY, M. and SHEAR, M.: The properdin system and immunity. VII. Alterations in properdin levels and resistance to infection in mice following the administration of tissue polysaccharides. *J. Exp. Med.*, 106: 99-110. 1957.
- 87c. PORTER, C. A.: The surgical treatment of x-ray carcinoma and other severe x-ray lesions, based on an analysis of 47 cases. *J. Med. Res.*, 21: 357-413. 1909. (Case VIII)
88. REPIN, C.: La toxithérapie des tumeurs malignes. *Rev. de Chir.*, 15: 465-493. 1895. (Paris)
89. RICHARDSON, M. H.: A case of apparently hopeless infiltration of left axilla and scapula by round cell sarcoma; extirpation attempted and abandoned; extensive and severe wound infection, followed by disappearance of the tumor. *Trans. Amer. Surg. Assn.*, 16: 309-313. 1898. (See also *Ann. Surg.*, 28: 741-746. 1898)
- 89a. ROGER, H.: Contribution à l'étude expérimentale du streptocoque de l'érysipèle. *Rev. de Méd.*, 12: 929-956. 1892.
90. ROHDENBURG, G. L. & PRIME, F.: The effect of combined radiation and heat on neoplasms. *Arch. Surg.*, 2: 116-129. 1921.
91. SHEAR, M. J.: Studies on the chemical treatment of tumors. II. The effect of disturbances in fluid exchange on transplanted mouse tumors. *Amer. J. Cancer*, 25: 66-88. 1935.
92. SHEAR, M. J.: Effect of a concentrate from *Bacillus prodigiosus* filtrate on

- subcutaneous primary induced mouse tumors. *Cancer Research*, 1: 731-732. 1941.
93. SHEAR, M. J.: Chemical treatment of tumors; reactions of mice with primary subcutaneous tumors to injection of hemorrhage-producing bacterial polysaccharide. *J. Nat. Cancer Inst.*, 4: 461-476. 1944.
 94. SHEAR, M. J.: See discussion of paper by REINHARD, E. J., GOOD, J. T. & MARTIN, E.: Chemotherapy of malignant neoplastic diseases. *J.A.M.A.*, 142: 383-390. 1950 (p. 390)
 - 94a. SHEILD, A. M.: Remarks on a case of recurrent sarcoma of the mammary gland treated with Coley's fluid with a fatal result. *Brit. M. J.*, 1: 193-194. 1897.
 - 84b. SHIELDS, E. H.: Coley's toxins in sarcoma. *Lancet-Clinic, Cincinnati*, 111: 701. 1914.
 95. SHOULDERS, H. S.: Observations on the results of combined fever and x-ray therapy in the treatment of malignancy. *Southern M. J.* 35: 966-970. 1942.
 96. SHOULDERS, H. S., TURNER, E. L., SCOTT, L. D. & QUINN, W. P.: Preliminary report on the effect of combined fever and deep x-ray therapy in the treatment of far-advanced malignant cases. *J. Tennessee State M. Assn.*, 34: 9-15. 1941.
 97. SHWARTZMAN, G.: Reactivity of malignant neoplasms to bacterial filtrates. I. The effect of spontaneous or induced infections on the growth of mouse sarcoma 180. *Arch. Path.*, 21: 284-297. 1936.
 98. SOUTHAM, C. M. & PILLEMER, L.: Serum properdin levels and cancer cell homografts in man. *Proc. Soc. Exp. Biol. & Med.*, 96: 596-601. 1957.
 99. SPENCER, C. G.: A case of sarcoma treated with Coley's fluid. *J. Royal Army M. Corps.*, 12: 449-451. 1909. (See also *Lancet*, 2: 1127. 1912.)
 100. SPENCER, C. G.: A case of sarcoma treated by Coley's fluid. *Proc. Royal Soc. Med., Clin. Sect.*, 2: 152-154. 1908-1909.
 101. SPRONCK, C. H. H.: Tumeurs malignes et maladies infectieuses. *Ann. Inst. Pasteur*, 6: 683-707. 1892.
 102. STEWART, F. T.: Sarcoma of psoas muscle treated by Coley's fluid. *Ann. Surg.*, 51: 285-288. 1910.
 103. STONE, H. B., CURTIS, R. M. & BREWER, J. H.: Can Resistance to Cancer be Induced? *Ann. Surg.*, 134: 519-527. 1951.
 104. TANCHOU, S.: Recherches sur le traitement médical des tumeurs cancéreuses du sein. Ouvrage pratique basé sur trois cents observations (extraits d'un grand nombre d'auteurs). Paris: Germer Baillière. 1844.
 105. TENNANT, C. E.: The use of heat in the control of inoperable cancer. *Colorado Med.*, Denver, 13: 176-182. 1916.
 106. TEUTSCHLANDER: Tuberculose und Krebs. *Zentralb. f. Bakt.*, 122: 57-62. 1931.
 107. TILLET, W. S., SHERRY, S., CHRISTENSEN, L. R., JOHNSON, A. J. & HAZELHURST, G.: Streptococcal enzymatic debridement. *Ann. Surg.*, 131: 12-22. 1950.
 - 107a. TOOLAN, H. W.: Successful subcutaneous growth and transplantation of human tumors in x-irradiated laboratory animals. *Proc. Soc. Exp. Biol. & Med.*, 77: 572-578. 1951.
 - 107b. TOSIER, F. L.: Non-operative sarcoma: a treatment. *Vermont M. Monthly*, 15: 217-218. 1909.
 108. TRACY, M.: Office Records.

- 108a. TUPPER, P. V.: The treatment of inoperable sarcoma with Coley's mixed toxins: report of cases. *Med. Rev.*, 39: 425. 1899.
109. TUFFIER, T.: *Le traitement du cancer inopérable*. Paris: Masson et Cie. 1910.
- 109a. VIDAL, E.: Cancer et Traumatisme. See: Association française de Chirurgie. *Comptes rendus du congrès français de chirurgie*. Paris: Alcan. 1907. (p. 902)
- 109b. WARD, G. S.: Mixed cell sarcoma treated by local excision and Coley's fluid. No recurrence after three years. *Brit. M. J.*, 2: 1484. 1913.
110. WARREN, S. L.: Preliminary study of the effect of artificial fever upon hopeless tumor patients. *Amer. J. Roentgen. & Radium Therapy*, 33: 75-87. 1935.
- 110a. WARTHIN, A. S.: Multiple primary neoplasms in one individual (spindle cell sarcoma of forearm, adenocarcinoma of pylorus, myomata of stomach wall); treatment with Coley's mixture. *Phila. M. J.*, 8: 701-703. 1901.
- 110b. WEIL, R.: The hemolytic reactions of the blood in dogs affected with transplantable lymphosarcoma. *Arch. Int. Med.*, 1: 23-27. 1908.
111. WESTERMARK, F.: Über die Behandlung ulcerirender Cervix carcinoma mittels konstanter Wärme. *Centralb. f. Gyn.*, 222: 1335-1339. 1898.
112. WINBERG, O. K.: Inoperable round celled sarcoma of the upper jaw with metastases, successfully treated with the mixed toxins of erysipelas and bacillus prodigiosus. *Med. Rec.*, 41: 681-684. 1902.
113. WINDLE, W. F., CHAMBERS, W. W., RICKER, W., GINGER, L. G. & KOENIG, H.: Reaction of tissues to administration of pyrogenic preparation from a pseudomonas species. *Am. J. M. Sc.*, 219: 422-426. 1950.
- 113a. WYETH, J. A.: Sarcoma cured by acute inflammation. *Med. Rec.*, 57: 125-126. 1900.
114. ZAHL, P. A., HUTNER, S. H., SPITZ, S., SUGUIRA, K., & COOPER, F. S.: Action of bacterial toxins on tumors. I. Relationship of tumor-hemorrhagic agent to endotoxin antigens of gram-negative bacteria. *Amer. J. Hyg.*, 36: 224-242. 1942.

