

BENEFICIAL EFFECTS OF IMMUNOTHERAPY (BACTERIAL TOXINS)
ON SARCOMA OF THE SOFT TISSUES, OTHER THAN LYMPHOSARCOMA



*End Results in 186 Determinate Cases
with Microscopic Confirmation of Diagnosis
49 Operable, 137 Inoperable*



Helen C. Nauts

MONOGRAPH #16

CANCER RESEARCH INSTITUTE INC.

1225 PARK AVENUE

NEW YORK, N.Y. 10028

1975

TABLE OF CONTENTS

INTRODUCTION	3
FIGURES 1, 2, 3, 4, 5, 6	20
SERIES A. INOPERABLE SUCCESSES: 70 cases	
Brief Abstracts	26
Analysis	44
Detailed Histories	48
Discussion of variability of toxins and techniques	141
SERIES B. OPERABLE SUCCESSES: 35 cases	
Brief Abstracts	169
SERIES C. INOPERABLE FAILURES: 67 cases	
Analysis	179
Table 1	184
SERIES D. OPERABLE FAILURES: 14 cases	
Brief Abstracts	197
SUMMARY AND CONCLUSIONS	201
BIBLIOGRAPHY (203 references)	205

INTRODUCTION

Much has been said of the phenomenon of "spontaneous" regression of cancer. It has a different meaning for different authors. Everson and Cole have defined a spontaneous regression of cancer as the partial or complete disappearance of a malignant tumor in the absence of all treatment, or in the presence of therapy which is considered inadequate to exert a significant influence on neoplastic disease. (84)

If such regressions were truly spontaneous, one could learn nothing from them. They would simply be noted as esoteric phenomena and would evoke no further discussion. It happens, however, that the regressions reported in the literature are not truly spontaneous, but are almost always associated with certain unusual circumstances such as acute concurrent infection, inflammation, fever or bacterial toxin therapy. (142) If a common denominator could be found in these cases, a first step in the solution of a giant riddle might be made.

The purpose of this review is to analyze the effect of bacterial toxin therapy on patients with sarcoma of the soft tissues. The data relating to the effect of infections on all types of neoplasia appear in another report. (142) It is hoped that the analysis of factors influencing success and failure in the following 186 cases will lead to more effective use of the method and to greater knowledge regarding this form of therapy and its effects, not only on sarcoma.

Before the remarkable discoveries of Pasteur and Koch, medical research centered upon the effects of "constitution" and "disposition" in pathological processes. With the advent of bacteriology, the reaction of the host was hardly considered in the development of a disease. However, with the development of the science of immunology, the pendulum once more is swinging in the direction of "resistance of the host", even in the field of neoplastic diseases. (88-91; 133; 136-153; 159; 160; 165-171)

The treatment of malignant tumors by injections of bacterial products is based on approximately 400 recorded cases of so-called "spontaneous regressions", the great majority of which occurred in patients who concurrently developed an acute infection, principally streptococcal or staphylococcal. (142)

INTRODUCTION

Most of these were cases of carcinoma or epithelioma. However, about 20 *inoperable sarcomas of the soft tissues* (other than lymphosarcoma) were found that disappeared completely under the influence of acute infections. Of the five recorded cases of *untreated operable* neoplasms in which infections developed and the tumors disappeared completely, only one was a sarcoma, in an 18-month old child, whose parents had refused amputation for an extensive tumor of the thigh. A severe pyocyanous infection developed in the biopsy wound. The tumor then disappeared and the patient remained free from further evidence of disease when last traced 23 years later. (142) Of the 47 *operable* cases in which infection developed spontaneously before or after surgical removal, four were sarcoma of the soft tissues. These four patients remained free from further evidence of disease when last traced 8 to 21 years after onset. (142)

The present report consists of all the microscopically proven cases of operable and inoperable sarcoma of the soft tissues, other than lymphosarcoma, in which toxin therapy (Coley toxins) was administered. The cases have been grouped according to the stage of the disease when toxins were begun, and the type of toxin used. Even if the administration of Coley toxins was associated with the regression of only one cancer, it would be worthwhile to find the possible explanation for this phenomenon.

The case histories were taken from the published reports of the indicated authors, relevant correspondence between those authors and Dr. William B. Coley, Coley's office records, and his published material. A few of the cases had not yet been published. These histories were obtained from the attending physicians or hospital records. In addition, because a number of the patients are still alive, the state of their health was determined by personal interview, or correspondence with the patients or their present physicians.

As to how acute infection, acute inflammation, fever or bacterial toxin therapy may exert their apparently beneficial effects on patients with cancer, it is known that neoplastic cells are more sensitive to heat than normal cells. (151) In addition to this, it appears that infections or their toxins may activate or mobilize various cells, tissues or systems in the body which affect tumor immunity, and which may not be functioning normally in cancer patients. (88-91; 133; 136-153; 159; 167)

The lymphocyte was first suggested as playing a role in resistance to neoplastic diseases by Murphy and his co-workers who, as early as 1914, were able to break down the resistance of animals to heterologous tumor transplants by destroying lymphocytes with irradiation or benzol. (cited by Nauts, 138) More recent investigators, such as Toolan, using the irradiation technic of Murphy, succeeded for the first time in propagating malignant human neoplasms in laboratory animals. (192) Thus, while it is apparent that lymphocytes are concerned in maintaining

INTRODUCTION

resistance against heterologous tumors, and that radiation destroys both the lymphocyte and the resistance, the precise mechanism of action is only now becoming more clearly apparent. Old and his colleagues were among the first to recognize the possible role of the reticuloendothelial system (RES) in resistance to neoplastic disease, as its function in various physiological processes became more clearly defined. (160) The RES is composed of cells scattered throughout the body which are actively phagocytic toward particulate matter, or can be stimulated to assume that function. Such elements are ranged anatomically in two ways: fixed reticuloendothelial cells which are attached to and form an integral part of sinusoidal walls, and free reticuloendothelial cells which wander through the tissue spaces. Fixed phagocytes and potentially phagocytic elements line the sinusoids of the liver, spleen, lymph nodes, suprarenal glands and the bone marrow. Free reticuloendothelial cells multiply rapidly during periods of greater need and become phagocytic whenever particulate matter comes into direct contact with their cell membranes under conditions which make phagocytosis possible. It is possible that the RES plays a role in disposing of carcinogens circulating in the blood, before they can exert their deleterious effects.

The acute inflammatory reaction is another important factor in the host's resistance to neoplastic diseases. (116; 144) The implantation of cancer cells into normal volunteers elicits a marked local inflammatory reaction and rapid rejection of the transplant. In patients with advanced cancer the initial inflammatory reaction is minimal and growth of the implanted cells occurs at almost all sites. (182)

It may be significant that the histamine liberated by acute inflammation appears to be a physiological activator of the reticuloendothelial system. (108) It is well to remember that an erysipelas infection, in addition to the fever it invokes and the toxins it produces, is accompanied by the most acute inflammatory reaction of any type of infection. The largest number of dramatic regressions of inoperable cancer occurred in the patients who developed erysipelas. Was this due to the fact that these patients were still able to elicit a profound inflammatory reaction to their infections, or merely to the fact that they were lucky enough to contract this type of infection with its attendant enzymatic debridement? (142)

The following factors influencing prognosis in cases treated by toxin therapy (Coley toxins) seem of importance.

1. *The stage of the disease when toxin therapy is begun* (see Fig. 2): A high percentage of permanent results (67 percent) was obtained in primary inoperable patients who had not developed metastases. Of the recurrent inoperable cases, 50 percent were successfully treated, but only 28 percent when metastases were present. Metastases appear to affect prognosis much more than cachexia or "poor

INTRODUCTION

general condition". Every patient in the operable group *receiving adequate toxin therapy* remained free from recurrence five years or more.

2. *Other treatment given prior to toxins*: Cases in which three or more surgical operations had been performed, or in which heavy prolonged radiation had been administered prior to the toxins, did not respond nearly as well to subsequent toxins, regardless of whether they were operable or inoperable when the toxins were begun.

3. *Age and sex of patient*: The highest percentage of successes occurred in females between 10 and 20, and 50 and 60 years of age, the lowest in males between 40 and 50 years of age.

4. *The type of toxins used* (See Fig. 1): It is now apparent that Buxton's V and VI and Tracy's X and XI were the most potent and least variable preparations available during the period covered by this study, 1893-1959. (137-153). It is not surprising, therefore, to find that the highest percentage of results were obtained in patients treated with these preparations. (A considerable number of letters and reports relating to the comparative weakness of the commercial preparations and the greater potency of the Buxton and Tracy products are cited below.)

5. *Duration of toxin therapy* (See Fig. 3): This factor appears to be of *great significance* in treating the inoperable cases, or when using a less potent preparation. Occasionally a permanent result was obtained with the weaker products if they were given persistently, in adequate dosage to produce the desired reaction, and begun before metastases were present. Among the operable cases the majority of successful results were obtained in cases treated six weeks to nine months. In the inoperable cases the optimum duration appeared to be from six to twelve months. It is important to note that if the recurrence or metastases developed following a brief period of toxin therapy, a permanent result was finally obtained if the toxins were promptly resumed and given persistently. For example, see cases 14, 23, 39, 41, 56, 57, 66 and 67 in the inoperable successes, and cases 12, 16, 21, 22 and 26 in the operable successes.

6. *Type of reaction elicited and site of injection* (See Fig. 4): Reactions were more marked, less prolonged and better tolerated by the patients when injections were given in or near the tumors or intravenously in sufficient doses to produce marked reactions with chills and temperatures of 101° to 104° F. or more. The highest percentage of successful results in the inoperable cases occurred in cases that had this type of reaction. In the operable series the results varied only slightly as regards the cases receiving injections in or near the cicatrix or tumor, intramuscularly remote from the tumor, or a combination of these two routes.

INTRODUCTION

Several surgeons who described the technique they used advised injections in the vicinity of the growth and gradually into the tumor itself; these include Coley, Matagne, Odier and Wyeth (who also used living cultures of streptococcus injected into the wound following surgical removal of sarcomas). If tumors were inaccessible, that is, in the abdominal cavity or pelvis, they advised injections in the gluteal region or in the abdominal wall in the immediate vicinity of the neoplasm.

7. *Frequency of the injections:* The majority of the successful results had injections every 24 to 48 hours during the first part of the treatment.*

Effects of Toxin Therapy on Normal Tissues or Organs:

A careful analysis of all the cases of sarcoma of the soft tissues and of about 800 cases of other types of neoplasms in which the toxins were used indicates that Coley toxins produced no deleterious effects on normal tissues or on the kidneys, heart, liver or other organs. One patient with chronic Bright's disease responded satisfactorily to the toxins without any ill effects on her diseased kidneys (Case 30, inoperable successes).

Stimulus to wound healing and regeneration of bone:

Many surgeons noted remarkably rapid wound healing in patients who were receiving toxin therapy. Others noted that large areas of bone which had been destroyed by the neoplasm regenerated completely. (147) Most of the latter occurred in the bone sarcoma cases (See Case 63, inoperable successes, for an example of the soft tissue group. This patient had had parts of two ribs resected at the time of the exploratory operation.)

Pain Relief:

A great many surgeons noted that there was marked relief of pain occurring almost immediately after the injections were begun. In a few cases pain returned as soon as the toxins were stopped temporarily, and again disappeared when they were resumed. Patients requiring large doses of narcotics were able to stop taking them. Pain relief occurred even in patients who were too far advanced to respond markedly to toxin therapy, and who were not ultimately cured. This suggests that toxin therapy may be of value as a palliative in such cases.

Cessation of Hemorrhages:

A few physicians noted that patients in whom hemorrhages had occurred prior to toxins, ceased hemorrhaging when the toxins were administered. However, in

* See Coley's comments on the importance of technique of administration below, p. 104; also those of Richardson, pp. 53-54 and Wyeth, p. 83.

INTRODUCTION

two far-advanced cases, rapid necrosis of the tumor following toxins caused fatal hemorrhage from a large vessel in the growth.

Stimulation of Hematopoietic Tissues:

There are a few histories which suggest that the toxins may stimulate the hematopoietic tissues (for example, See Case 63, inoperable successes). This effect is sometimes masked by the fact that absorption of large quantities of necrotic tumor tissue may produce temporary anemia.

Effects on Concurrent Pregnancy and Fetus:

Only three pregnant women are known to have received Coley toxins during their pregnancy. The first was Case 12, inoperable successes, who was given intramuscular injections during the second trimester, followed by complete regression of the sarcoma. A normal child was born at full term. A second patient with very far-advanced malignant melanoma also received the toxins intramuscularly during the latter half of her pregnancy, with marked palliation as regards pain relief, improved sleep, etc., and some evidence of temporary arrest of the extensive growths. Her child was also born at about full term (labor was induced), and was entirely normal. The third case, a reticulum cell sarcoma of the humerus, was given a fairly large initial dose intravenously in the sixth month of her pregnancy. This caused a very marked reaction: the temperature reached 105.4°F. within two hours, preceded by a severe chill which began immediately after the injection. An abortion occurred a few hours later. The toxins were resumed nine days after abortion and were given concurrently with x-ray therapy (2,000 r), followed by complete regression of the tumor. This patient is alive and free from disease in 1976, 40 years later.

Dangers of Toxin Therapy:

The available evidence suggests that Coley toxins, are without harmful or dangerous effects to patients or animals suffering from various types of neoplasms, provided these toxins are administered properly as to dosage, site and the usual aseptic precautions. They should not be given to patients with severe hepatic insufficiency due to metastatic disease or other pathology, nor to patients who have had severe heart conditions, nor to patients who are almost moribund, because such patients do not respond. It is not even possible to elicit the desired febrile reactions.

Current Research on Toxin Therapy:

During the past 23 years Cancer Research Institute* has been investigating various factors which appear to stimulate the natural resistance of patients or animals

* Founded in 1953 as New York Cancer Research Institute; name changed in 1973.

INTRODUCTION

to neoplastic diseases. In this connection, the apparently beneficial effects of bacterial products, including Coley toxins, are being evaluated. One of the objectives of the Institute has been to act as a center of information regarding the possibilities and limitations of microbial products. Thus we have stimulated and helped other investigators to begin serious evaluations of this method by supplying them with formulae, data, etc. The first of such studies to be reported was that of Havas and Donnelly (12; 77; 88-91; 101; 133).

The analysis of the inoperable successes and failures may be helpful in evaluating some of the points just discussed and will be found in the Appendix. For a more graphic picture of most of these factors, see Figures 1-6 immediately following this introduction.

Brief abstracts of the 186 cases are presented in four groups. The decision as to whether a case was operable or inoperable in these cases was made by the attending surgeon at the time the toxins were begun. It is recognized that such a distinction is occasionally difficult to make.

Series A:	70 inoperable successes.
Series B:	35 operable successes
Series C:	67 inoperable failures
Series D:	14 operable failures.

Potency of the Preparations Used:

The importance of using a potent preparation of Coley toxins or any other microbial product is now much more clearly recognized. Unfortunately, during Coley's lifetime he was not aware for many years that some preparations being used were quite weak or ineffective. For example, the Coley toxins were prepared at the Lister Institute of Preventive Medicine in England, beginning about 1895 and continuing until about 1944. We have designated this preparation Lister Institute VIII. Coley is believed to have first discussed the matter while he was in London in 1895, and some correspondence has been found dating from 1897 from one of the doctors in charge of the Institute to Coley indicating that the toxins were made by them prior to that date. No data were found in Coley's files as to which formula they used prior to 1908, but it was probably Buxton's mixed unfiltered toxins of *Streptococcus pyogenes* and *Serratia marcescens* (then known as *Bacillus prodigiosus*).

It is known that in 1908 and thereafter the formula used was apparently sent over by Tracy (her Type XI, unfiltered). The records indicate that these toxins evidently were made from chromogenic cultures of *prodigiosus* at least part of the

INTRODUCTION

time after December 1908. Apparently the Lister Institute product was weaker than Tracy's preparations, available from 1908 to 1921, as indicated by the letters describing the experience of the English surgeons (67):

August 10, 1909: Professor G. Grey Turner (later President of the Association of Surgeons of Great Britain and Ireland): "Since hearing your address in Leeds on the treatment of sarcoma by the mixed toxins, I have started one or two cases. I am anxious to give the method a very thorough trial, because I am perfectly convinced that it is the only thing likely to do good in a great many cases. I find it difficult to get a reaction with the small doses of the preparation sent out by the Lister Institute and Parke Davis. I am sure the addresses which you gave in this country will greatly stimulate the profession to an appreciation of the valuable work you have done along this line and I am anxious to arouse in this city as much interest as possible in the subject—but I want to be quite sure that I am using a reliable preparation for the work." (Grey Turner was then living in Newcastle-on-Tyne; in 1935 he was appointed Director of the Postgraduate Hospital and Medical School in London.)

July 22, 1909: Dr. D. C. Choyce, 30 Harley Street, London, a prominent London doctor, writes: "Where can I procure the toxins prepared according to your methods? I think I am right in saying that up to the present the fluid has not always been prepared quite accurately in this country, and I should like, if I have the opportunity, to give a fair trial to Coley's fluid, not to somebody else's idea of what that fluid should be." (67)

August 31, 1909: Dr. Robert Bell, of Stoneleigh, Surrey: "I have tried both Parke Davis and the Lister Institute toxins but neither seems to act satisfactorily." He then asked if he could have some of Tracy's preparation sent over.

December 27, 1909: Dr. Lawrie McGavin, Cavendish Square, London: "I wish you could tell me why it is that the vaccine which bears your name is, as obtained in London, so often apparently inert. I am, I may say, a firm disciple of your method of treating inoperable sarcoma, but here in London it seems almost impossible to obtain *active* toxins." He further stated that he had used the Lister Institute preparation recently in two cases, but even a dose of seven minims produced no reaction whatever.

In March 1910 Dr. Peter H. LeRass of Dublin, Ireland, writes: "I am treating a sarcoma of the femur with the bacterial toxins . . . but have altogether failed to get the reactions as described in your paper before the Royal Society in July last. Perhaps the fault may be with the preparation I am using." He then asked if Coley could send him some of his own preparations.

INTRODUCTION

In May 1910 Dr. Eric Gardner, of Fellside, Weybridge, Surrey, wrote for advice in regard to treating a sarcoma of the testis with metastasis in the groin after operation. "What I am doubtful about is the quality of 'Coley's Fluid' obtainable in England. We have not had much result over here, which may be due to the inefficiency of our mixed toxins. I believe you have had some correspondence with the Lister Institute on the matter, and I am wondering if you pass their preparation as correct, or whether you advise me to import some direct from you . . . I may say that a series of cases have been treated with the Lister Institute toxins at the London Hospital, with little if any benefit, and that is why I doubt the Institute's preparation."

January 20, 1912: Dr. Charles E. Iredell, of Portland Place, London, writes: "Your lecture in the Gazette (Guy's Hospital) has had a wide circulation and I have received several requests for toxins. (Tracy XI) . . . You can therefore see how much trouble people are taking to get your latest fluid. It is certainly quite different from any I have hitherto used, in that it is almost the rule to get a reaction (slight) with $m\frac{1}{4}$ on a woman and $m\frac{1}{2}$ on a man. *Within the last week patients have said to me that they have been without pain for the first time in six months and three months respectively. I cannot see how people can neglect a remedy which produced such results . . .*" He wrote again on February 27, 1912: "I am interested to hear of the new success of the Danish surgeon. I do think such cases are of greatest importance not only as a cure, but also because they encourage surgeons to use the toxins before the growths have reached a large size and also to use them prophylactically." March 27 (still using Tracy XI, a further supply sent by Coley): "The dosage is now so accurate that I scarcely ever fail to get a reaction at the first injection and have never any alarming symptoms."

February 1, 1912: Dr. Rolf Creasy, of Surrey, writes on Sir Alfred Fripp's advice for directions on toxins: "I am deeply interested in your lecture at Guy's and wish to use the right fluid."

April 22, 1913: The senior surgeon of the West London Hospital, Hammersmith, writes: "Perhaps it is due to the preparation of the fluid here in England that the administration of the fluid is not meeting with success."

November 191 : In concluding a paper on myeloid sarcoma of the tibia, Sir Frederic Eve, Senior Surgeon to the London Hospital, stated that he had been asked to make some remarks on the use of Coley's fluid in these cases. He quoted a recent report of Coley and his statistics, (41 cases of inoperable sarcoma traced well 3 to 17 years) saying: "It is impossible to gainsay such statistics. Yet it is astonishing that, as far as I have been able to ascertain, anything at all comparable to these successes has not been met with elsewhere."

INTRODUCTION

He goes on to say that one of the surgical registrars of the London Hospital carefully looked up the cases in which Coley's toxins had been used in that hospital. He stated that "the treatment has been started in many cases, but has been discontinued for various reasons." All cases are excluded unless ten or more injections were given, and this left only ten cases. In seven of these there was absolutely no result. Eve added: "One, a sarcoma of the front of the thigh, nearly disappeared and I removed it; but the man came back in less than a year with metastasis in the orbit. In two cases of recurrent sarcoma of the muscles of the thigh and of the nose respectively, both got smaller, but the latter subsequently died." (Note: apparently five of these ten cases were osteogenic sarcomas and one a chondrosarcoma. It would appear that in order to produce permanent results in the less sensitive types of bone tumors it may be necessary to combine surgical removal with toxin therapy and to use potent preparations effectively administered as regards site, dosage, frequency and especially duration of the injections, i.e., for at least three or four months.) (153) In only two of the cases treated at the London Hospital was the Tracy XI preparation used, the rest being treated by the weaker Lister Institute preparation (Type VIII). It should be emphasized that no one in the London Hospital appears to have understood the importance of the technique of administration. (The Lister Institute never enclosed any directions or indications with their preparations. (10) Under these circumstances it is not surprising that results were disappointing in this series.)

In conclusion Eve stated: "It is undeniable that a certain number of sarcomata disappeared under, or are profoundly influenced by the toxins, but we have no means of determining what proportion this is to the total number treated. I suspect it is only a small amount. Although I may be forming an opinion on insufficient evidence, yet my present attitude is that I would not recommend Coley's fluid in any case of operable sarcoma, nor would I recommend its use as a prophylactic against recurrence." (83)

It is regrettable that a physician should arrive at any definite conclusion in regard to toxin therapy without a thorough study of the technique or the factors involved in producing an effective preparation, or after observing only ten cases. Naturally, the condemnation of a qualified senior surgeon, whose opinion carried weight, did not tend to stimulate further research in London. It is interesting to note that in the same volume of *Lancet* two other English surgeons, Greenwood (97) and Spencer (183), reported successful results with the method. The importance of technique was appreciated by these men and the former, Greenwood, made some of the most detailed and helpful observations found in the literature. (For detailed abstracts of these cases see 139, Cases 8 and 17, pp. 36 and 53.)

INTRODUCTION

The First American Commercial Preparation of Coley's Toxins: (Parke Davis IX):

A considerable number of letters were found in Coley's files which clearly indicate the comparative weakness and variability of the toxins prepared by Parke Davis & Co. from December 1899 to early 1907, now known as Parke Davis IX. (67) A factor contributing to this lack of standard potency was that both the streptococcus and the prodigiosus* cultures grew with variable luxuriance and no method had been devised to standardize the concentrations of the suspensions, or to be sure that original bacterial strains did not change their characteristics. Although Parke Davis used the same formula as that of Buxton VI the latter appeared to be consistently more potent. Among the letters found bearing on this subject are the following:

A letter from Mr. M. Lujan, of San José, Costa Rica, on May 11, 1901, describes the effects of Coley's toxins on his daughter who had a far-advanced inoperable malignant tumor of the nasopharynx:

After removing one of the tumors, the toxins were begun. At first they used the Parke Davis IX preparation, but although the injections were given in large doses, no visible results were obtained and the tumors continued growing so that the swelling extended over all the face. A fresh bottle of Buxton VI was received on May 8, 1901 and an injection of 10 drops was made, although on the previous day a larger dose of the other preparation had been given. This injection was made about 11 A.M. and Mr. Lujan stated: "Immediately all the tumors took on a high colored purple hue." (The phenomenon of local tissue reactivity.) The fever rose to 105°F. and the pulse was not perceptible. Necrotic tumor tissue had to be extracted with forceps in order to prevent asphyxia. The condition was such as to require eight injections of stimulants (caffeine, digitalis, champagne and cognac).

Mr. Lujan continued: "At last the temperature was reduced, the pulse recovered its natural state. Nevertheless, the doctors thought during the night that she had only a few hours to live. Unexpectedly, about 3 A.M., it was noticed with perfect wonder that the swelling had disappeared from the face and that both of the tumors were reduced to about half . . . which reduction has continued in such degree that today (three days later) one is only the size of a nut and of the other which had grown to be the size of an orange with such rapidity, there is nothing left."

Unfortunately the end-result is not known in this case. It is cited as an example of the comparative effects of two different preparations of Coley's toxins in the

* now known as *Serratia marcescens*

INTRODUCTION

same individual, and of the striking changes which may occur from an injection of a potent product in an advanced case.

Dr. G. Harlan Wells of Philadelphia writes on March 3, 1904 in regard to a case of sarcoma of the abdominal wall which he had been treating for two weeks:

"I have used Parke Davis and Co.'s preparation and have been unable to obtain the least reaction from their use. I have obtained two different bottles directly from their head office in Philadelphia, and have given over 20 minims at a dose. No fever or other evidence of a reaction. This I feel is due to the toxins being inactive. Before giving up the treatment I should like very much to get an active preparation and give it a thorough trial."

Dr. Benjamin Austin Cheney, of New Haven, Connecticut, wrote on March 29, 1904 for advice in treating a case of round cell sarcoma of the breast. He had worked up to 15 minims of the Parke Davis serum without getting any fever or reaction other than local heat, tenderness, swelling and redness, which lasted 24 to 48 hours. He asks: "Do you wish to send me the stronger solution of Buxton and have me go on with that." (This indicates that Coley and a few other physicians in that period recognized that Buxton's preparation was more potent.)

Dr. Clarence King of Machias, New York, wrote on November 1, 1904: "The second bottle of toxin did not look like the first bottle, being of a reddish color, while the first was clear. Both were Parke Davis' and used within the time limit. Could there have been anything wrong with the preparation?" (The "reddish color" usually indicated that more chromogenic cultures of *Serratia marcescens* were used.)

On January 18, 1907, Dr. E. M. Lambert of Ottawa wrote in regard to his brother's case: "The injections of only $\frac{1}{2}$ to 1 minim of the new serum (Tracy XI) produced as good and active reactions as 3 or 4 minims of the first. These reactions always appeared to produce good results, such as reducing the intensity of the pain and also in retarding the growth of the tumor."

On March 6, 1907, Dr. A. T. Bristow of Brooklyn, New York, wrote asking for some of Coley's own toxins and adds: "I have never been able to depend on Parke Davis and Co.'s toxins, having given as high as 20 minims without reaction." In another letter on November 26, 1907 he adds: "Is the Parke Davis preparation good for anything? I have tried it some years ago and found it quite inert."

On July 31, 1907, Dr. J. Augustus Bacon of the Garretson Hospital, Philadelphia, Pennsylvania, writes: "About July 1st we purchased direct from Parke Davis and Co., Detroit, some of Coley's fluid for a round celled sarcoma, upper jaw, starting

INTRODUCTION

with a quarter of a minim. We raised it to 12 minims without any reaction. Can you offer an explanation for this? Could the toxin be deteriorated?—still, the date says good until September.”

On November 14, 1907, Dr. Horace Packard of 470 Commonwealth Avenue, Boston, wrote: “I am very glad to know that I shall be able to get toxin from a more reliable source. I had practically given up using it because that which I received from Parke Davis seemed totally without action.”

Evidently both preparations were used in a number of cases. This point was brought out by letters from a number of physicians in different parts of the country. Although in these cases the Buxton VI was clearly more effective, no one appeared to consider that continued use of the weaker commercial product might immunize the patient to the effect of the toxins before the disease was controlled and thus inhibit the effectiveness of subsequent use of the Buxton preparation.

A group of Ohio physicians discussed their experiences with Coley toxins from 1900 to 1911, following a report by Oliver in October 1911. (161) Up to that time Oliver had treated 11 cases. In three of these, good results were obtained—one exhibited very marked improvement, even to the almost total disappearance of the tumors, but they subsequently recurred and the patient died of the disease. X-ray therapy was combined with the toxins in this case. The second case was “a very brilliant success”—an osteosarcoma of the cervical vertebrae. This case received 52 doses in three months, recovering completely from quadriplegia with loss of urinary and fecal control. X-ray examination showed the reparative changes produced under treatment.

Oliver then gave brief histories of the other cases he had observed and treated. Unfortunately he did not mention the technique of administration used in any of these other cases, as regards site, dosage, frequency (and usually duration), nor the type of reaction elicited. With one exception, the cases treated were all inoperable. Many of the patients had had two to four operations with repeated recurrences or metastases, and the results obtained were negative except for the second and third cases.

Oliver concluded that the remedy was not a specific in sarcoma, and that “one was not justified in assuming that it ever would influence a large proportion of the cases of sarcoma favorably.” He admitted, however, that it did cure a small number of cases. He asked: “How can we account for its apparent value in some cases and its lack of power in others?” He answered this as follows: “In view of the fact that we have an uncertain composition with which to deal, it is possible that the discrepancy may be due to the use of solutions in one set of cases which may be inert, while in others an active preparation may give rise to most gratifying

INTRODUCTION

results. The lack of a definite, tangible standard must always constitute a bar to a scientific estimation of the value of a given sample."

"I have never, but once, had the opportunity of using the contents of one bottle on two patients during the same period of time. One patient was affected favorably while the other received no benefit whatever. This experience tends to confirm one's belief that the difference in results cannot be attributed solely to the difference in the preparations used."

"There seems to be but one other explanation available, i.e., that the contradictory results must be due to differences in the neoplasms, or to differences in the individual patients. Either hypothesis seems tenable and each involves an understanding of conditions which are incomprehensible in the present state of our knowledge. My prophecy is that future research will demonstrate that there are many important differences in the tumors which are now classed as sarcomata—differences of causation, nature, life history and significance. We must therefore attribute our failures . . . to our lack of understanding of the fundamental questions involved.

"I feel that no essay on this subject would be complete without referring to the honesty, persistency and incalculably valuable research of Dr. W. B. Coley. In the face of some active opposition and much disheartening apathy he has steadily held to his belief and has made every endeavor to prove the correctness of his position in regard to the use of this remedy. Everybody wishes him success in his most humane labor and hopes for the coming of the time when Q.E.D. may be written at the end of his research instead of, as we are compelled to do at present, the words "not proven". (161)

Dr. G. M. Todd of Toledo, Ohio, then gave a brief review of his experience with Coley toxins between 1905 and 1911. (161, discussion) He stated that he had treated 13 inoperable and three operable cases in those six years. He described the effects in one far-advanced sarcoma of the hip, in which the tumor mass diminished gradually and then six weeks after the first injection, separated from the body with a profuse hemorrhage, leaving a very extensive, oozing surface. It was considered necessary to ligate the iliac vessel by the transabdominal route. Death occurred six days later.

Todd's other cases were: five sarcomas of the knee, in two of which amputations were performed, followed by prophylactic toxin therapy. Both remained free from recurrence. The three inoperable cases were not seemingly benefited, the disease progressing rapidly, causing death a few months later. In two cases involving the inferior maxillae, one was treated over a period of nine months, and the toxin seemingly had an inhibitory effect, but the patient died of the disease. The

INTRODUCTION

second was only given a few injections, the reactions being so severe that further treatment was refused. A case of a 13-year old boy with lymphosarcoma (axillary) which had been operated upon, was treated with the toxins for four months without result. Todd treated three cases involving the shoulder, two of which were treated for a short period, refusing further treatment because of the severe reactions. The third shoulder case was in a maiden lady aged 64, who had dislocated her shoulder six months previously. The shoulder was enormous when injections were begun, with edema of the arm. During six weeks' toxin therapy, no diminution in size occurred either in the shoulder or in the edema. The wrist was the size of a stove pipe prior to death. A case of sarcoma of the testis was given post-operative toxins two weeks at a time for six months, but metastasis developed in the kidney on the same side, causing death. In October 1911 a spindle cell sarcoma of the clavicle was receiving prophylactic toxin therapy to prevent recurrence following operation.

Todd considered his most interesting case to be a far-advanced inoperable small round cell sarcoma of the sternum, the size of a fetal head with metastasis to the clavicle the size of a fist in which prolonged aggressive toxin therapy, combined with some radiation, caused complete destruction of the entire growths (largely by sloughing of large portions the size of a man's fist). The resulting wound healed, leaving an extensive scar. This patient developed a mediastinal recurrence a year later which caused death from involvement of the spine.

In concluding this brief review of his experience with the method, Todd stated: "With this rather unfavorable report of a series of very unfavorable cases I cannot help but feel that the toxins have value. After a careful search of the literature of this subject, I believe that from 4 to 10 per cent of the cases of inoperable sarcoma are cured, that many cases are inhibited, that Coley's toxins are worthy of a trial and hold out some hope to an otherwise hopeless class of patients." (161)

Dr. W. D. Haines of Cincinnati, Ohio, stated: "As long ago as 1900 I began using Coley's serum, and used it very persistently in a number of cases after operating. The result was not good; I can't recall a single instance in which benefit was derived. I met Dr. Coley in 1896 at Atlanta, Georgia, at the Meeting of the Surgical Section of the American Medical Association. He was reading a paper upon this subject at that time, and has been patiently and persistently going along this line ever since. And while I believe very much in Dr. Coley's sincerity and honesty, his product, as I obtained it, gave no benefit to my patients and I discarded it."

Haines then described two cases successfully treated in 1910 and 1911 (see below, Series A, Case 46, for the complete history of the first of these two cases

INTRODUCTION

which involved the aponeurosis of the right rectus and external oblique muscle. The second was a case of osteosarcoma of the tibia.) Both patients remained free from recurrence when last traced in 1933, 22 and 23 years later. (161)

As to the reasons for the contradictory results which had been reported, Haines agreed that Oliver's suggestion of the varying degree of malignancy in different types of sarcoma could not be denied. He added: "But I think my success in the two cases has been due rather to obtaining the real serum. I obtained the commercial serum in my early work eleven years ago, and we had absolutely no reaction follow, although my assistant in one instance gave an entire syringe barrel-full. . . . Today we start with a quarter of a drop, and . . . we very promptly obtain a very marked reaction, a chill lasting 20, 30 or 40 minutes, a temperature of 103° or 104°—and that is the result we obtain following the use of the serum as we obtain it from Dr. Coley himself, or rather from his ex-assistant, Dr. Martha Tracy" This was the Tracy XI preparation. He then cited a case of inoperable round cell sarcoma reported by Wild (1904) in which the prognosis was hopeless and the patient developed a severe erysipelas infection, with complete and permanent regression, traced 15 years.

He added: "Now Coley, in one of his reports which he has sent to me, records 32 successes in sarcomata of the long bones, out of 50 cases, that are alive and well from three to seventeen years after the use of the Coley serum. I feel that this is a success that operative surgery does not offer. Dr. Coley, himself a surgeon, no longer, I take it, amputates these legs, but subjects all of them, irrespective of the degree of malignancy, to the use of the serum . . . We are using it as Dr. Coley has advised, in inoperable epithelioma, (including a case involving the rectum)." (Note: Coley continued to amputate most of his cases of osteogenic sarcoma, but saved the limb in cases of giant cell tumors, Ewing's sarcoma or reticulum cell sarcoma of bone. (133; 147; 153)

In concluding the discussion, Oliver stated: "I feel in regard to . . . Coley's toxins that it fills a very important part in our armamentarium; from a practical standpoint Coley's toxin has been a godsend. Instead of having to say to patients 'you are doomed', to be able to say, 'Now there is another remedy that can be used', which helps . . . a good deal." He added, however, that he was convinced that only about 10 per cent of the inoperable cases were permanently cured. (161)

In considering these observations of a group of Ohio surgeons reporting their experience with toxin therapy from 1896 to 1911, it is important to recognize that, in addition to the fact that until 1908 few physicians outside of New York or its vicinity used any toxins other than the weaker commercial product (Parke Davis IX), the majority did not understand the importance of aggressive treatment or the fact that very far-advanced or moribund cases could rarely be cured.

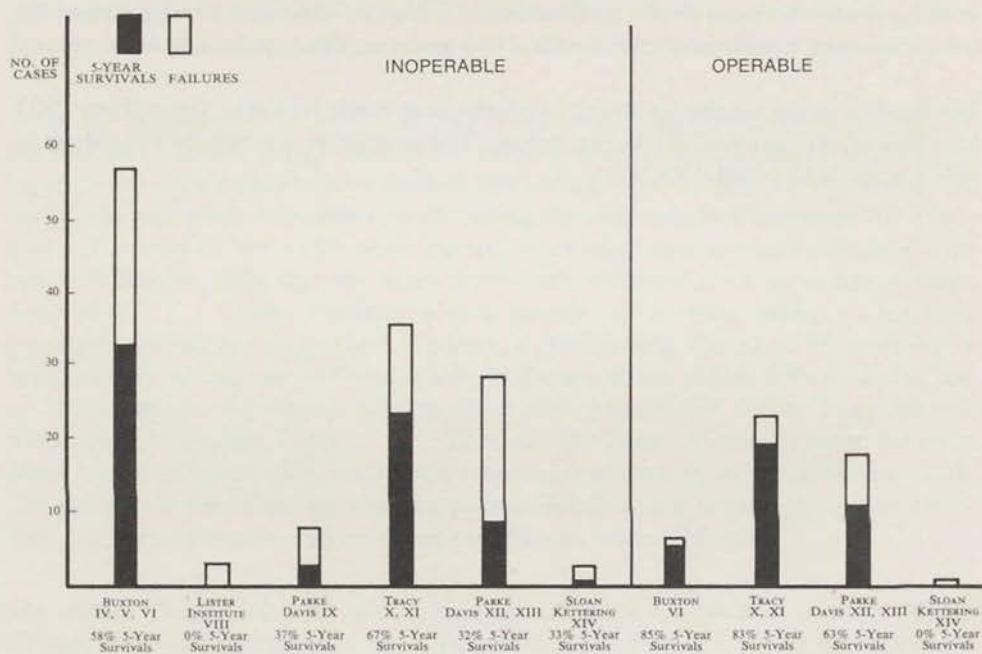
INTRODUCTION

Under such unfavorable conditions it is not surprising that they became discouraged and did not use the method widely. Haines' clear-cut description of his own experience with both the commercial and the Tracy products is of value.

For further detail on the commercial products as made by Parke Davis from 1907 to 1950 (P. D. XII and XIII) see below. The formulae are briefly described in references #137 and 139.

INTRODUCTION

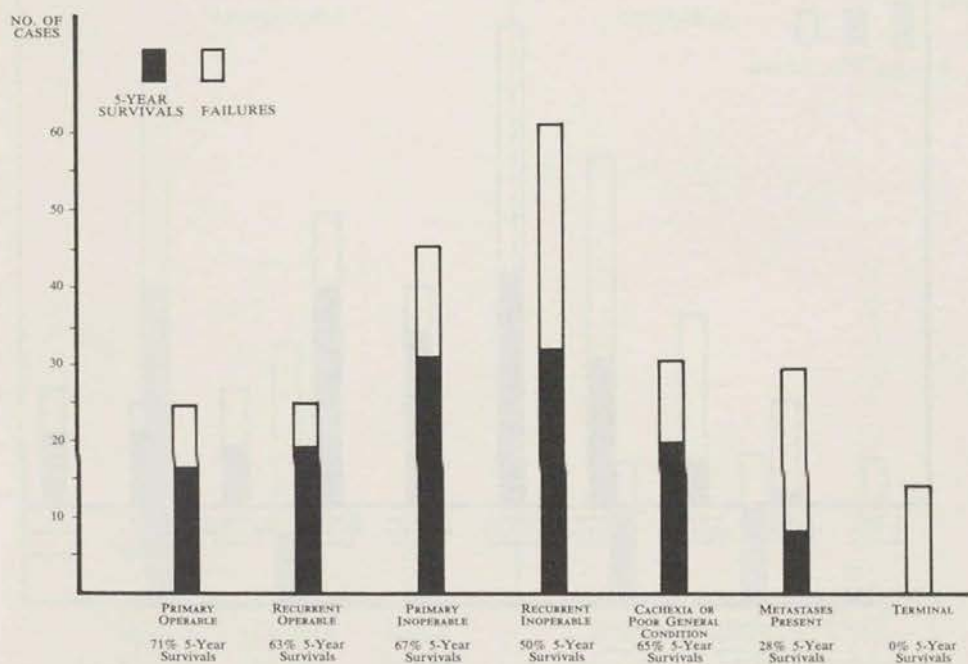
FIG. 1. END RESULTS ACCORDING TO TYPE OF TOXIN



Note: See below for letters from physicians here and abroad concerning the comparative weakness of the commercial preparations.

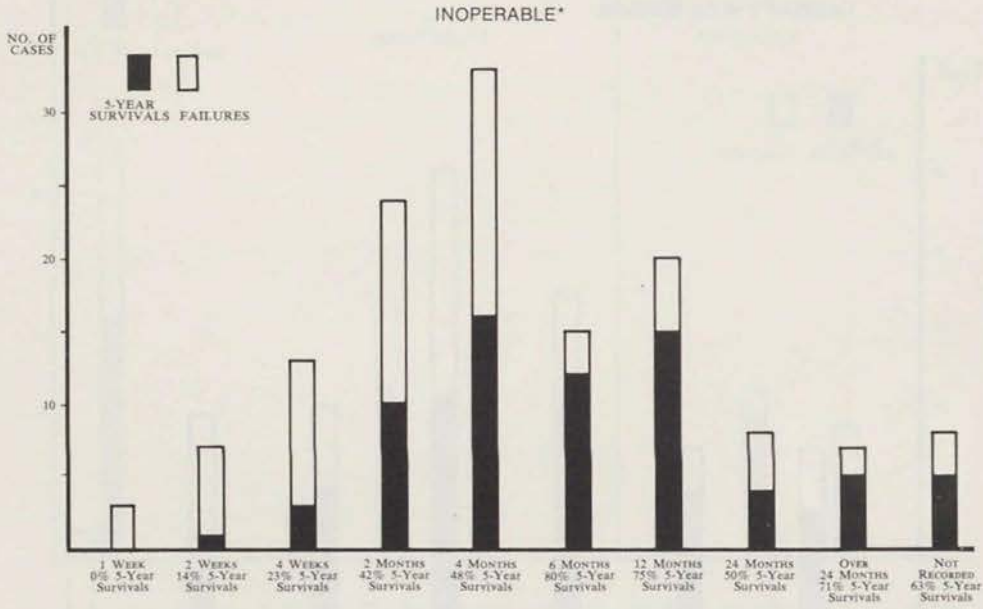
INTRODUCTION

FIG. 2. END RESULTS ACCORDING TO STAGE OF DISEASE WHEN TOXIN THERAPY WAS BEGUN



INTRODUCTION

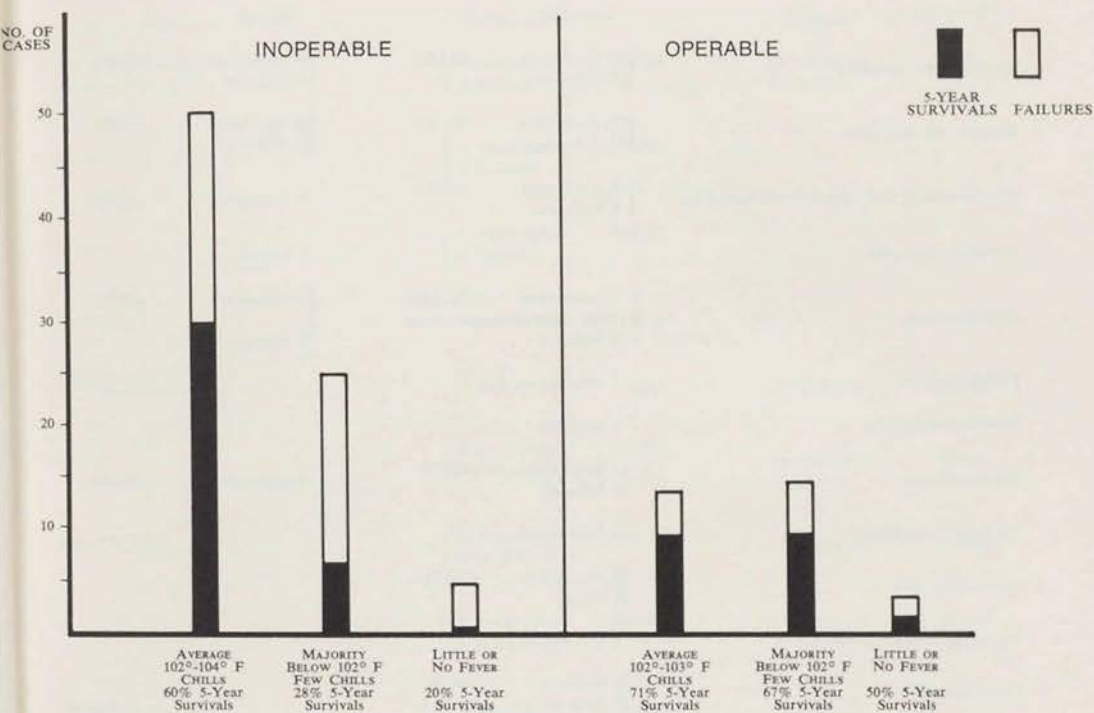
FIG. 3. END RESULTS ACCORDING TO DURATION OF TOXIN THERAPY



*THE MAJORITY OF THE OPERABLE 5-YEAR SURVIVALS RECEIVED TOXIN THERAPY FOR FROM 6 WEEKS TO 9 MONTHS.

INTRODUCTION

FIG. 4. END RESULTS ACCORDING TO REACTION ELICITED



INTRODUCTION

FIGURE 5 **END-RESULTS AS REGARDS TYPE OF TUMOR**

<i>Type of Tumor</i>	<i>Inoperable</i>	<i>Operable</i>
Spindle cell sarcoma	20 successes (54%) 17 failures	5 successes (70%) 2 failures
Round cell sarcoma	18 successes (51%) 17 failures	6 successes (60%) 4 failures
Mixed round and spindle cell sarcoma	5 successes (42%) 6 failures	3 successes (100%)
Alveolar sarcoma		1 success
Fibrosarcoma	7 successes (58.3%) (1 was neurofibrosarcoma) 5 failures	5 successes (63%) 3 failures
Fibroangioma	1 success	
Fibromyosarcoma	1 success	
Myxosarcoma	1 success (20%) 4 failures	4 successes (100%)
Angiomyxosarcoma	1 failure	
Angiosarcoma	4 successes (80%) 1 failure	
Hemangioendothelioma	1 success	
Endothelioma	1 success (33%) 2 failures	
Reticulum cell sarcoma	1 success (50%) 1 failure	1 failure
Synovioma		1 success
Myeloid sarcoma	1 failure	
Leiomyosarcoma and malignant myoma	2 successes (50%) 2 failures	
Neurogenic sarcoma		4 successes (66%) 2 failures
Polyhedral cell sarcoma		1 failure
Desmoid sarcoma	1 success	
Sarcoma, unclassified	8 successes (100%)	8 successes (100%)

INTRODUCTION

FIGURE 6 **END-RESULTS ACCORDING TO SITE OF TUMOR**

Type of Tumor	Inoperable		Operable	
Intra-abdominal	20 successes 6 failures	(77%)	4 successes 1 failure	(80%)
Abdominal wall				
Uterus	5 successes 4 failures	(56%)		
Ovary				
Kidney	4 successes 4 failures	(50%)		
Colon, intestines	2 successes	(100%)		
Breast	1 failure	(0%)	1 success	(100%)
Head & Neck	2 successes 3 failures	(40%)	4 successes	(100%)
Parotid				
Mediastinum	15 successes 16 failures	(48.4%)	5 successes	(100%)
Muscles, tendons, fascia	3 successes 2 failures	(60%)	1 success 1 failure	(50%)
Extremities or Trunk				
Synovial membrane	1 success	(100%)		
Primary site unknown (metastases generalized over entire body, hemangioendotheliomata)	17 successes 30 failures	(36%)	20 successes 11 failures	(65%)
			1 success	(100%)

INOPERABLE SARCOMA OF SOFT TISSUES OTHER THAN LYMPHOSARCOMA TREATED BY TOXIN THERAPY: SERIES A, BRIEF ABSTRACTS

SUCCESSFUL SERIES: 70 cases with microscopic confirmation of diagnosis, traced 4 to 78 years after onset.

Toxins, Type IV or V (10 cases)

These were filtered preparations. For a brief description of the various formulae used in making Coley toxins see references 137 and 139.

	Years Traced After Onset
1. (COLEY): J.F.F., male, aged 16; inoperable spindle cell sarcoma (13 cm. by 15 cm.) entire thickness of abdominal wall, attached to pelvis and involving bladder wall. General condition poor, micturition involuntary, confined to bed most of time. Onset October 1892; exploratory laparotomy, January 24, 1893. Toxins injected into tumor for 6 months; <i>steady decrease in size, which continued after toxins were stopped; complete regression</i> ; no recurrence; patient in perfect health. Sudden death February 28, 1919, chronic myocarditis, 26 years after onset of sarcoma. First case of any type of cancer to receive Coley's <i>mixed</i> toxins. (7; 10; 14; 16; 17, p. 70; 41; 42; 51; 139)	26
2. (COLEY): W.S.G., male, aged 15; twice recurrent inoperable angiosarcoma nasal septum and nasopharynx, onset July 1891; tumor removed by Abbe, but promptly recurred; Abbe operated again, taking away most of left superior maxilla; prompt recurrence of considerable size; 2 electrolytic treatments (unsuccessful), June 1893, toxins injected in region of tumor; marked reactions, <i>uninterrupted improvement; tumor completely disappeared</i> . No further recurrence; patient remained in good health, married and had 5 children. A small epithelioma on back of neck excised 1950. Died from severe heart attack January 15, 1951, aged 75. (10; 67)	59½
3. (COLEY): Mrs. E.J.L., aged 29; extensive inoperable fibrosarcoma abdominal wall filling lower left quadrant; patient cachectic; onset April 1893; exploratory operation; no attempt at removal (small piece excised for biopsy); prognosis grave. October 1893, toxins injected directly into tumor daily, causing inflammation; large doses, febrile reactions 101° – 102°F.; <i>improvement evident in two weeks; complete regression in 4 months</i> ; no recurrence; well thereafter. Died heart failure 1918. (17; 19; 20; 41; 67; 139; 173)	25
4. (JOHNSON): T.C., male, aged 16; inoperable spindle cell sarcoma involv-	

SERIES A, INOPERABLE SUCCESSES

Years Traced
After Onset

ing tonsils, palate, roof of mouth, nasopharynx, pillars of fauces, part of pharyngeal wall, whole base of tongue, epiglottis and upper larynx; uvula entirely destroyed; cervical nodes enlarged; lost much weight and strength; deglutition difficult; nasal breathing impossible; prognosis hopeless. Onset early 1893; untreated. October 31, 1893 toxins given for 8 months intramuscularly (legs, arms); febrile reactions, 99° to 103°F.; *steady slow improvement, deglutition easy in two weeks; extensive growth completely disappeared, partly by absorption, partly by necrosis*; gained 22 pounds, stronger; no recurrence, alive in very good health June 1915; not traced thereafter. (17; 45; 55; 67)

22

5. (COLEY): Miss M.L., aged 35; inoperable retroperitoneal round cell sarcoma, recurrent after hysterectomy for primary in uterus, pain in back and abdomen. Onset 1889; 2nd operation attempted but abandoned. January 12, 1894 toxins for 8 weeks in thigh; *considerable regression*; upon exploratory celiotomy, tumor was still the size of a goose egg and inoperable. Toxins resumed, given every 48 hours; *tumor did not disappear until several months after toxins were stopped*. No further recurrence, well when last traced 1917. (51; 47; 128)

28

6. (COLEY): F.K., Female, aged 16; extensive infiltrating inoperable fibrosarcoma tendon sheath over metatarsal bone, recurrent in stump, leg, thigh, gluteal regions. Onset and excision 1889; recurrence 3 years later; Syme's amputation; further recurrence in stump, popliteal space; also inguinal lymphadenopathy. At 3rd operation, popliteal recurrence not entirely removed; stump recurrence untouched. In March 1894 treated with toxins; *complete regression*; gained 17 pounds. Further recurrence in gluteal region October 1895; toxins caused *diminution*; later mid-thigh amputation; toxins resumed, given with intervals of rest for 3 years; *no further recurrence*; in excellent health 1936. (17; 19; 21; 25; 51; 58; 68, case 128)

47

7. (COLEY): Mrs. M.S., aged 29; very large recurrent inoperable fibrosarcoma of the gluteal region and thigh. Onset about 1886; surgical excision October 1891, when the lesion measured 10 × 15 cm.; recurrence in 3 months; tumor very extensive, caused much pain; prognosis hopeless. April 7, 1894, toxins locally for 3 months; dosage increased to produce marked reactions; *pain ceased but improvement very slow; growth continued to decrease after injections stopped*. April 29, 1899, fibrous remains excised; no microscopic evidence of malignancy; no further recurrence; in very good health. Death February 2, 1941, coronary heart disease. (10; 16; 40; 51; 67; 128)

53

SERIES A, INOPERABLE SUCCESSES

Years Traced
After Onset

8. (MYNTER): C.P., female, aged 12; inoperable spindle cell sarcoma involving parietal peritoneum, mesentery, pelvic organs and cecum; abdomen enormously distended, micturition involuntary. Onset about March 1894. At laparotomy, 2 quarts of chocolate-colored fluid escaped; specimen from soft vascular growth removed; profuse hemorrhage checked by packing; patient moribund. July 26, 1894 toxins started 4 days after operation; given daily into upper thigh; no marked reactions; *immediate, steady, complete regression*; (necrotic pieces of tumor sloughed and were evacuated through drainage tube). In good health without recurrence in June 1898; not traced subsequently. No record of death found in period 1898-1954. (7; 50; 58; 137; 138)

4

9. (COLEY): T.J., male, aged 32, thrice recurrent inoperable fibroangioma upper lip. Onset 1891; first operation 1892; recurrence; 2nd operation; extensive recurrence of very rapid growth followed 3rd operation. November 19, 1895, toxins (Type V) injected into the tumor; *immediate decrease; almost entire disappearance in 3 weeks*; plastic operation later to restore lip. No further recurrence; alive and well in 1903. (19; 25; 67; 134)

12

10. (COLEY): M.S., female, aged 5; twice recurrent inoperable small round cell sarcoma of lower lip. Onset July 1896, following trauma. Two operations; recurrence of rapidly growing tumor extending from mucous membrane of lip downwards for 4 cm. February 10, 1897, toxins injected into tissues near tumor; slight reactions; *complete disappearance*; scar tissue then excised; no evidence of tumor remained; toxins given 14 months; no further recurrence. Married, had 2 children; alive and very well in 1975. (10; 21; 40; 51; 65)

78

Buxton's unfiltered toxins, type VI (23 cases)

11. (COLEY): S.C., female, aged 16; inoperable spindle cell sarcoma (32 cm. in diameter) left scapular region; extensive involvement entire left chest wall from clavicle to costal margin. Onset March 1894. Incisional biopsy June 23, 1894; then toxins injected into tumor; fairly marked febrile reactions; *immediate and rapid improvement; complete regression in 9½ months*, entirely by absorption; as a precaution toxins given for 10 months; no recurrence; alive and well in December 1913. (17; 19; 20; 35; 51; 128; 139)

19½

12. (MCARTHUR): Mrs. D. P., aged 40; recurrent inoperable fibrosarcoma

SERIES A, INOPERABLE SUCCESSES

- | | Years Traced
After Onset |
|--|-----------------------------|
| <p>originating in sheath of tibial muscles of calf. Onset 1891. Very radical excision of primary growth, March 30, 1894; recurrence size of walnut; patient 3½ months pregnant when toxins were begun September 28, 1894; <i>progressive improvement; no marked reactions; no unfavorable effects on pregnancy; normal child born at full term; complete regression of sarcoma; no further recurrence; alive and well November 1912.</i> (25; 169)</p> | 21 |
| <p>13. (PACKARD): Female, aged 39; recurrent inoperable spindle cell sarcoma of parotid; date of onset not stated; primary growth removed in 1894; recurrence within a year. August 1895, toxins injected daily for several months into growth or surrounding tissues; <i>marked rapid regression; growth "shrank away to an unoffending node";</i> further injections failed to dissipate this fibrous stroma, which was dissected out; <i>excellent healing; no further recurrence. In excellent condition in 1898.</i> (40; 51, p. 152; 67)</p> | 4½ |
| <p>14. (COLEY AND COBB): Mrs. M.D., aged 40; spindle cell sarcoma of iliac fossa, size of coconut, involving the ilium and abdominal wall. Onset May 1895. Exploratory laparotomy; specimen removed. Beginning November 1, 1895 toxins were given by Cobb for 6 weeks; <i>complete regression;</i> a few months later extensive recurrence filled right lower quadrant; toxins resumed for 2 months by Coley, causing regression to 1/5 former size; injections not given during hot weather; again, recurrence; toxins resumed and continued for 7 months; <i>immediate decrease in size; complete regression;</i> no further recurrence; alive and well in 1907. (10; 38; 40; 46; 65; 128)</p> | 12 |
| <p>15. (STORRS AND GRISWOLD): E.E.F., female, aged 42; inoperable rapidly growing spindle cell sarcoma of pectoral region and breast; rapid loss of weight and strength. Onset October 1895; tumor size of orange in 2 months; biopsy. December 16, 1895, toxins into tumor; incision and drainage to evacuate necrotic tumor tissue; <i>complete regression</i> after 3½ months' treatment; no recurrence, in good health, married. 45 years later basal cell epithelioma developed on nose; death from bronchopneumonia and arteriosclerosis May 2, 1943, at age of 89. (7; 10; 23; 25; 32; 46; 51; 67; 138; 139)</p> | 47½ |
| <p>16. (NICHOLSON): Mrs. J.R.C., aged 47; inoperable twice recurrent spindle cell sarcoma of thigh with extensive involvement of inguinal lymph nodes; entire limb edematous. Date of onset not stated. Primary and first recurrent tumor removed surgically; further extensive recurrence; surgery not possible. January 1896, toxins given every 48 hours for 2½ months; febrile reactions, 101.5° to 103°F.; <i>complete regression of recurrent</i></p> | |

SERIES A, INOPERABLE SUCCESSES

Years Traced
After Onset

- tumor, inguinal involvement and edema; alive and well in July 1899. (155) over 4*
17. (WILLIAMS): Mrs. E.Z., aged 37; recurrent inoperable spindle cell sarcoma of uterus; large growth projected about 10 cm. above surface of abdomen. Onset 1895; exploratory laparotomy March 24, 1896; portion removed for biopsy. April 4, 1896, toxins injected directly into tumor; very severe reactions (high dosage for intratumoral route); poultices also applied; necrotic tumor tissue drained through sinus 5-7 cm. deep in center of tumor; *steady rapid regression; complete disappearance of extensive hard tumor; no further recurrence; alive and well in 1914. (40; 51, p. 151; 67)* 19
 18. (PACKARD): E.P., female, aged 15; inoperable round cell endothelial sarcoma of pelvis. Date of onset not stated. Exploratory laparotomy, biopsy May 1896; toxins: *rapid local and general improvement; complete regression; no further recurrence; alive and well in 1906. (51, p. 152; 67; 170)* 10
 19. (PACKARD): Female, aged 55; extensive recurrent inoperable sarcoma inseparably adherent to the abdominal viscera. Date of onset not stated. Primary tumor had been removed previously; fragments of recurrent growth removed at 2nd laparotomy; prognosis hopeless. In May 1896, treated with toxins; *rapid local and general improvement; complete regression; no further recurrence; alive and well 1906. (40; 44, p. 182; 51, p. 152; 67; 170)* 10
 20. (ROBERTS): Female, aged 18; round cell endothelial sarcoma of left ovary, with many metastatic nodes in adjacent viscera, ascites. Date of onset not stated; exploratory laparotomy May 4, 1896; toxins begun soon after; given subcutaneously in abdominal wall steadily for several weeks; *all growths disappeared; no recurrence or further metastases. Patient later married; alive and well 1908. (31; 38; 44; 51, p. 152; 170)* 12
 21. (ZABRISKIE): Female, aged 43; recurrent extensive inoperable intra-abdominal sarcoma. Onset late in 1895. Primary growth was "size of child's head" when removed; large recurrent tumor in 4 months; rapid growth. November 1896, toxins given thrice weekly for 3 months; *marked decrease in size of tumor, remained stationary for a time, then regressed completely with continued injections (given for 12 months); no further recurrence; alive and well 1908. (25; 51, p. 155)* 13
 22. (COLEY): Mrs. B., aged 34; inoperable thrice recurrent mixed round cell and spindle cell sarcoma of parotid. Date of onset not stated. Primary growth and 1st 2 recurrences removed surgically; further operation inad-

SERIES A, INOPERABLE SUCCESSES

Years Traced
After Onset

- visible. January 1897, toxins in small doses; *marked decrease in size; increase in mobility; most of remaining tissue easily excised under ether; found to be fibrous stroma of former growth*; toxins given another 3 months (total 7 months); no further recurrence; well when last seen 1907. (32; 33; 40; 51; p. 60) 10
23. (GRINDON): Mrs. R.B., aged 50; recurrent inoperable spindle cell sarcoma in supraclavicular region, involving thoracic wall behind 1st and 2nd ribs. Onset early 1897; incomplete operation performed a few days after mass above left clavicle first noted; prompt recurrence; mass soon exceeded its former size; general condition very poor, bed-ridden. Toxins begun April 15, 1897; 58 injections into tumor and vicinity in 6 months; marked reactions from beginning of treatment; *complete regression* in 4 months; regained health; 3 months after last injection recurrent nodules appeared in neck, breast and axilla; toxins resumed without effect (only 6 doses in 8 weeks); several nodules excised in April 1898; toxins then given more aggressively; *remaining growths sloughed and healed*; no further recurrence; died unrelated causes 1905. (10; 55; 67; 194) 8
24. (COLEY AND WRIGHT): A.W.L., male, aged 40; twice recurrent inoperable spindle cell sarcoma of parotid, involving the submaxillary lymph nodes. Onset early 1897; 1st operation March 1897; rapid recurrence; 2 more operations, 3rd incomplete; very rapid growth thereafter. July 20, 1897, toxins begun, given by Wright for 3 weeks; little effect except some softening and sloughing of central ulcerated portions; toxins then given aggressively by Coley (daily large doses); *complete disappearance* of tumor in 2 months; no further recurrence; in perfect health until death November 22, 1903, following severe hemorrhage from gastric ulcer. (7; 24; 25; 26; 32, 51, p. 98) 6
25. (ROBERTS): Adult (sex not stated); inoperable intra-abdominal sarcoma. Date of onset not stated; exploratory laparotomy, specimen removed, 1899; toxins; *complete regression*; well and free from recurrence October 1905. (Roberts had at least 2 other successes in similar cases) (51, Case 47 in table.) 5
26. (COLEY): Mr. E.S., aged 55; recurrent inoperable small round cell sarcoma of parotid, highly malignant histologically. Onset November 1899; incomplete operation April 5, 1900; prompt recurrence. October 5, 1900 toxins started; injections into tumor 4 or 5 times weekly in small doses; moderate reactions; no pronounced change except slight decrease in size of tumor, increase in mobility during 1st month's treatment; in another 2 months' treatment improvement more marked; *growth disap-*

SERIES A, INOPERABLE SUCCESSES

Years Traced
After Onset

- peared after 8 months' treatment; no further recurrence; died 1907 severe herpes involving Gasserian ganglion; no evidence of recurrence at time of death. (34; 35; 40; 41, p. 92)* 8
27. (COLEY AND MEAD): Mrs. H.G.L., aged 40; inoperable fibrosarcoma of abdominal wall, involving bladder. Onset early 1900; exploratory laparotomy December 19, 1900; several nodules removed for biopsy; toxins begun 5 days later in daily increasing dosage; given for 5 months; *complete regression*; no recurrence; 23 years later primary carcinoma of liver developed, causing death October 17, 1924 (no toxins given for this neoplasm). (7; 10; 46; 128) 24
28. (COLEY): M.J.H., female, aged 34; extensive inoperable fibrosarcoma of anterior abdominal wall 15 × 17 cm. in diameter, filling entire right iliac fossa. Panhysterectomy for "fibroadenoma" of uterus in August 1898; onset of fibrosarcoma 2 years later; pain; mass in region of cicatrix. Exploratory incision April 19, 1901: portion excised for biopsy; 2 days later toxins: 20 in 1st 60 days, some into tumor; 12 caused adequate febrile reactions; *growth softened and decreased to less than half its size in 8 weeks; after discontinuing toxins growth increased to former size and became harder*. Toxins resumed October 3, 1901 for 6½ weeks; *at first marked diminution; then no further effect*; cachexia; condition hopeless. Partial removal of tumor on December 27, 1901; 46 x-ray treatments January to June 1902; tumor increased to 20 cm. in diameter; patient had *several attacks of fever and toxemia lasting few days; general health then improved considerably*. Total of 136 x-ray treatments in 849 days; complete regression by May 1904; gained 19 pounds; considerable skin damage and ulceration from x-rays; skin-grafts required; later, x-ray cancers developed and were excised. Patient alive and quite well at 90; during 1959-1960, increasing ulceration of anterior abdomen; carcinomatous degeneration surmised but never proven; increasing debility, death bronchopneumonia April 2, 1959. (10; 34; 36; 39; 67; 128; 172; 200) 58
29. (DAVIES): A.G.W., male adult; recurrent inoperable mixed cell sarcoma of neck, involving anterior border sternocleidomastoid muscle and deeper structures. Onset July 1900; primary growth excised February 2, 1901; prompt recurrence. May 4, 1901 toxins begun, given for about 3½ months with 4 weeks' rest between 1st and 2nd courses; *complete regression* during treatment; no further recurrence; in good health for many years; died November 1912 of what appeared to be pulmonary tuberculosis. (51; 55; 67) 12

SERIES A, INOPERABLE SUCCESSES

Years Traced
After Onset

30. (CHAPIN): Mrs. B., adult; inoperable round cell sarcoma of thoracic cavity beneath sternum; biopsy. January 1902 toxins: at first every 48 hours; *skin and subcutaneous tissue in upper part of tumor necrosed with profuse discharge of necrotic tissue; during 5th month dosage was 30 minims once weekly; complete regression* by May 15, 1902; no harmful effects on kidneys, although she had chronic Bright's disease; no recurrence; in better health than at any time prior to treatment; alive and well 1906. (51; 67) 4
31. (COLEY AND BOYNTON): H.B.M., male, aged 56; recurrent inoperable spindle cell sarcoma of triceps muscle, deltoid region. Onset summer of 1902; September 1902 tumor excised along with some of deltoid muscle; recurrence February 1903. Toxins begun by Coley February 12, 1903, continued at home by Boynton; *regression*; no further recurrence; well until death December 25, 1928, at age of 81, from auricular fibrillation and cerebral embolus. (7; 51; 67) 26
32. (COLEY): F.Q., male, aged 63; recurrent inoperable large spindle cell sarcoma of cheek. Onset January 1904; excision week later; prompt recurrence; 2nd attempt at removal abandoned. March 16, 1904, toxins (Buxton VI and Parke Davis IX): given for 3 months, also a few x-ray treatments: *complete regression; cheek regained normal appearance*; no further recurrence; last seen in 1910, aged 69, in good health. (51, p. 95; 128) 6
33. (COLEY): W.J., male, aged 10; inoperable thrice recurrent round cell sarcoma of scapular region. Onset January 1902; incomplete removal; x-ray therapy; regression; recurrence; further radiation ineffective; 3rd operation; further x-ray therapy; 3rd recurrence June 1904. Toxins begun July 1, 1904; given for a year in vicinity of scars; also x-ray therapy for a time; *slow, complete regression*; no further recurrence; 20 years later x-ray carcinoma of left shoulder; repeated excisions, skin grafts, shoulder-joint disarticulation failed to control it. Death on February 4, 1952, 50 years after onset; autopsy showed presence also of bilateral bronchial carcinoma. (10; 32; 36; 39; 40; 43; 48; 67; 128) 50

Buxton VII: Erysipelas and Bacillus prodigiosus Serum (1 case).

This preparation was made for only a short time and appeared to be less effective than the unfiltered toxins Type VI.

34. (COLEY): Mrs. A.C., aged 59; inoperable thrice recurrent angiosarcoma of the breast. Date of onset not stated; 2 excisions of large ulcerated nodular growth; foul discharge; general condition very poor. February 1,

SERIES A, INOPERABLE SUCCESSES

Years Traced
After Onset

1895 serum given, 51 injections in several months; also 7 doses of Buxton V (filtrate), later seemed less effective than serum; *slow decrease in size, increase in mobility, improvement in general health*; remains of growth excised August 18, 1895; no further recurrence. Patient well until death 1903 from injuries incurred in fall downstairs; no evidence of sarcoma at that time. (19; 25; 46; 51, p. 88; 128)

8

Parke Davis IX, a commercial preparation of Coley toxins available from 1900 to 1907 (3 cases)

35. (HUNDLEY): Mrs. A.C., aged 38; inoperable recurrent round and spindle cell sarcoma of the uterus. Onset fall 1903; growth size of full term fetal head removed by supravaginal hysterectomy December 1903; attempt to remove cervix January 15, 1904 abandoned because of weak heart; recurrence in right lateral fornix, springing from broad ligament, pelvic bone and fascia. January 22, 1904: toxins; 33 doses directly into fornix and cervix; *immediate decrease in size, complete regression*; no further recurrence; in good health until sudden death from severe duodenal ulcer July 1932. (40; 51, p. 155; 67)

28

36. (SPENCER): C.W.L., male, aged 33; inoperable spindle cell sarcoma entire lower abdomen, infiltrating peritoneum, involving rectus muscles, firmly attached to symphysis pubis; frequent micturition, progressive weight loss. Onset October 1905; exploratory laparotomy, biopsy; 6 days later attempt at removal abandoned because of extensive involvement. September 22, 1906, toxins injected into tumor; sharp local and general reactions; 3 courses totalling 43 doses in 6 months; *complete regression*; no recurrence; alive and well 1912. (41; 51; 67; 139; 140)

6½

37. (GREEN): J.P., male, aged 20; extensive inoperable small round cell sarcoma of abdominal wall in region of umbilicus, apparently originating in urachus; extremely adherent to omentum. Onset early November 1906; very large calculus (9 cm. in diameter) removed from prostatic urethra in March 1906, followed by purulent cystitis; exploratory operation. January 1, 1907, toxins; 60 doses injected into tumor in 5 months, *causing intense local inflammation* and evident systemic reactions; *complete regression*; gained 40 pounds, alive and well 1911. (51; 67; 96)

5

Tracy X and XI, unfiltered (23 cases)

38. (MUDD): Miss C.N.J., aged 30; inoperable sarcoma primary in left ovary recurrent in abdominal wall. Onset prior to fall of 1906; curettage

SERIES A, INOPERABLE SUCCESSES

Years Traced
After Onset

November 13, 1906; oophorectomy July 19, 1907; tumor 18 cm. wide, almost gangrenous; rapid inoperable recurrence in abdominal wall. August 1, 1907, toxins (Tracy X); duration not recorded; *complete regression*; no further recurrence; alive and well 1919. (57; 67; 193)

12½

39. (COLEY): Miss M.L.W., aged 42; leiomyosarcoma uterus recurrent following hysterectomy, filling lower pelvis, involving bladder wall; frequent painful micturition, general health bad. October 1, 1907, toxins (Tracy X, XI, XI F, Parke Davis XII & XIIF); *improvement noted in 2 to 3 weeks; marked cessation of pain, softening; decrease in size, general health improved*. Toxins not given for 8 weeks during hot weather; immediate return of symptoms, increase in size of tumor. Toxins resumed in low dosage with intervals of rest for nearly 2½ years, causing mild reactions; *complete regression*; no further recurrence. Patient well during next 35 years; death March 29, 1944, aged 80, from cerebral hemorrhage and hypertension. (7; 10; 48; 128; 193)

37

40. (COLEY): C.B.C., male, aged 27; inoperable metastatic round cell sarcoma, primary in muscles of lower lumbar region; metastases involving entire thickness lower jaw. Onset September 1907; primary tumor 18 cm. in diameter in few weeks; excision; unhealed wound 15 × 20 cm.; patient generally emaciated, unable to walk unaided. November 19, 1907, toxins (Tracy X) injected into gluteal muscles; also 5 doses of filtrate (Tracy X F) into tumor of jaw; *slow decrease in size; marked increase in mobility; general health improved; gain in weight*. Toxins given for 8 months; improvement more rapid after first 6 weeks; *complete regression*; no further metastasis; in good health and very active for 37 years; in autumn of 1944 carcinoma developed at the site of original growth in lumbar region causing death June 11, 1946 at age 73; no toxins were given for this neoplasm. (10; 43; 46; 51; 128; 139)

39

41. (HOWE): Mrs. C.McM., aged 50; recurrent inoperable round cell sarcoma uterus; infiltrating mass filled pelvis clinically resembled carcinoma; severe pain and bladder symptoms; general health bad, prognosis hopeless. Date of onset not stated. April 7, 1908, toxins 4 times weekly; *general condition improved, pain ceased; tumor decreased steadily in size*. Toxins stopped during hot weather; severe pains immediately returned, toxins resumed and given steadily, 119 doses in 26 months; *complete regression*; no further recurrence; in good health until death at age 81, from cerebral arteriosclerosis. (10; 47; 51; 67)

28

42. (RESHOWER): Mrs. S.R., adult; extensive recurrent round cell sarcoma

SERIES A, INOPERABLE SUCCESSES

Years Traced
After Onset

involving all abdominal viscera. Date of onset not stated; primary growth removed from pelvis as well as possible, but all organs were involved in the adhesions; fistula remained; x-ray treatment given briefly; stopped because it caused so much dermatitis; recurrent tumor filled whole abdomen; prognosis grave. July 7, 1908, toxins: given aggressively for 9 months; *complete regression*; no further recurrence; alive and in excellent health 1915. (10; 67)

7

43. (TOSIER): Female, aged 22; inoperable spindle cell sarcoma of left ovary, involving broad ligament, uterus and intestine. Onset October 1907; exploratory laparotomy December 1908; due to extensive involvement and fear of hemorrhage, only biopsy was performed; prognosis hopeless. Toxins begun after her return home; given daily at first; *immediate improvement*; *gained 60 pounds*. Toxins given for 10 months; periods regular; no recurrence; had second child in autumn of 1909, year after toxins stopped; in good health 1912. (48; 51; 67; 100; 193)

5

44. (LEACH): H.H., male, aged 33; twice recurrent inoperable spindle cell sarcoma of right kidney; metastases involved intestines extensively. Patient had been ill for 6 months, lost 40 pounds, coughed; chest films revealed only "bronchial trouble", thought to be tuberculosis. Exploratory laparotomy May 30, 1908; practically solid growth weighing 13½ pounds filling whole abdominal cavity removed; recurrent tumor size of orange; on April 17, 1910 whole omentum removed up to stomach; metastases on right side, involving intestines; exploratory incision; condition inoperable. July 1, 1910, toxins: 41 in 60 days; *complete regression*; *patient regained 40 pounds and former strength*; perfectly well 1916. (10; 67)

6

45. (DA COSTA): Female adult; huge inoperable spindle cell sarcoma of thigh and groin. Date of onset not stated. Portion of growth removed surgically in 1910; *toxins begun immediately thereafter*; *given daily*; *violent reactions every day for weeks*; *complete regression*; no recurrence. (72)

4

46. (HAINES): J.M. male, aged 52; inoperable round cell sarcoma of right rectus and internal oblique muscles; immovable tumor size of hen's egg; date of onset not recorded; exploratory operation, incomplete removal April 25, 1910; 2 days later toxins begun: 3 courses in 6 months; *considerable sloughing of necrotic tumor tissue*; *complete regression*; well and free from recurrence until death from heart attack in 1933. (10; 51; p. 166; 67)

22

47. (HARMER): L.E.F., female, aged 46; extensive recurrent infiltrating

SERIES A, INOPERABLE SUCCESSES

Years Traced
After Onset

spindle cell sarcoma of antrum and ethmoid. Onset 1904; had 6 operations; recurrences. February 19, 1912, toxins given for 6 weeks after 6th incomplete operation; *remains of growth apparently destroyed*; no further recurrence; in excellent health next 20 years; died cerebral hemorrhage April 16, 1932. (10; 100; 120)

28

48. (COLEY): J.G.K., male, aged 25; inoperable spindle cell sarcoma of retroperitoneal region and iliac fossa. Onset December 1911. Toxins March 26, 1912 for 4 weeks; decrease in size of tumor, softening; incision; necrotic tissue evacuated. Toxins resumed; given several weeks longer; *complete regression*; no recurrence. Patient alive and well 1918. (41; 55; 67)

6

49. (STEWART): D.A.D., male, aged 56; inoperable mixed cell sarcoma of right groin, "decidedly malignant"; loss of strength and appetite, 15 pound weight loss. Onset, February 1912. Toxins, April 1912; meticulously administered; *complete regression*; no recurrence; remained in excellent health more than 20 years; then carcinoma of stomach, metastases to spine; death September 21, 1934, aged 77, from general carcinomatosis, chronic myocarditis and arteriosclerosis. (67; 127)

22

50. (MCDONALD AND BURNS): M.P., female, aged 27; inoperable round cell sarcoma of kidney, involving retroperitoneal lymph nodes. Onset early 1912; surgical exploration revealed an inoperable condition; there was a large retroperitoneal mass as well as a mass occupying the lower pole of the kidney; no attempt at removal; condition hopeless in September 1912 when toxins (Tracy XI) were started; given intramuscularly into buttocks; febrile reactions to 105°F.; *immediate improvement*; *sinuses healed*; *complete regression*. Patient gained 20 pounds; well. Multiple fibroids developed requiring panhysterectomy in 1927; no evidence of disease at site of former sarcoma of elsewhere. She subsequently had several operations for intestinal obstruction due to adhesions; no evidence of malignant disease; later developed cerebrovascular disease causing death November 1966. (10; 51; 66; 67; 138, case 20; 145)

54½

51. (SHIELDS): Mrs. F.H.D., aged 48; inoperable myxosarcoma of left tonsil and palate; submaxillary lymph nodes enlarged; tumor size of hazel nut beneath left ear. Onset in spring of 1913. Biopsy of buccal tumor. September 29, 1913, toxins: at first daily, then every 48 hours, some into tumor; dose increased to 21 minims; *complete regression*, *gained 16 pounds*, *in excellent health*; no recurrence. Sudden death pneumonia following influenza, 1918. (67; 176)

5

SERIES A, INOPERABLE SUCCESSES

Years Traced
After Onset

52. (CRUIKSHANK): W.L.W., male, aged 28; large spindle cell sarcoma of retroperitoneal region. Onset about October 1913; exploratory operation; 3 months later colostomy necessary because of complete obstruction; mass extended to umbilicus; prognosis 2 to 3 weeks. February 4, 1964, toxins into abdominal muscles (no reactions from Parke Davis XII given first 5 days; thereafter Tracy XI given with marked local and general reactions); total of 87 in 5 months; *complete regression*; no recurrence. (Subsequently this man's wife had 5 children in 12 years.) In good health except for gallstones requiring cholecystectomy 1942; coronary thrombosis 1949, complete recovery, in excellent health until hemiplegia 1954, again complete recovery; 1959 developed gastric carcinoma with liver metastases causing death November 8, 1960. (55, case 31 in table; 67) 47
53. (COLEY): J.K., male, aged 31; inoperable round cell sarcoma of nasopharynx and right superior maxilla involving ethmoid and frontal bones. Onset April 1913; neuralgic pain at sites of involvement and also in temporal and supraorbital regions, right naris occluded, weight loss; biopsy. April 22, 1914, toxins injected intramuscularly into right chest for 4 months; *almost immediate diminution in size of tumor; complete regression in 4 months*; no recurrence. Alive and well 1924. (5; 67; 128) 10
54. (COLEY AND ZACHARIE): Mrs. D.B., aged 22; extensive inoperable fibromyxosarcoma of calf, thigh and hip; possible lymphadenopathy. Onset November 1913; larger mass measured 70 × 43 cm.; smaller tumors also present, filling popliteal space; 50-pound weight loss; general health poor; severe pain; biopsy. Toxins (Tracy XI & Tracy XI F) May 18, 1914, at first into buttocks, later into growths on hip or surrounding tissues, *some decrease in size of tumors; increase in mobility; atrophic changes, no necrosis, sloughing or discharge, very little absorption; apparently toxins destroyed malignant elements without affecting fibrous stroma*. Patient regained strength and weight very slowly; alive and well except for some arthritis of spine 1954; hypertension 1957; myocardial infarction, death January 15, 1969, acute auricular fibrillation with myocardial failure due to arteriosclerotic heart disease. (10; 67; 128) 46
55. (WILLIAMS): Mrs. R.A.H., aged 56; inoperable recurrent sarcoma of nares and superior maxilla. Onset autumn 1913; nose cauterized; primary growth removed; recurrence; extensive 2nd operation left superior maxilla, left lower orbital plate removed; recurrence, condition believed hopeless. September 1, 1914, toxins given daily at first; 62 intramuscularly in 6½ months, 7 marked reactions; *tumor disappeared in 3 months*; in good health 5 years; then epithelioma of hard palate developed; 3 radium

SERIES A, INOPERABLE SUCCESSES

Years Traced
After Onset

treatments in 1920; disease not controlled, later extended to left naris and antrum; further palliative radiation in March 1921 and March 1922 (no toxins); death March 9, 1923, no further evidence of sarcoma. (10; 52; 67)

9

56. (TUHOLSKE): M.B., male, aged 28; round cell sarcoma of right pharynx and nasopharynx; almost complete obstruction of air. Date of onset not stated. Biopsy; toxins May 1915; no effect from massive doses of Parke Davis XII given intramuscularly, remote from tumor; first dose of Tracy XI caused violent reaction, chills, high fever and necrosis in center of tumor; *complete regression in 6 weeks*; left hospital feeling well; a few months later recurrence on opposite side of pharynx with abducens nerve paralysis (metastasis in region of hypothalamus). Daily intramuscular injections of toxins into arms for a week; no reactions or effect on tumor; then injections given in thighs and abdominal wall alternately; marked febrile reactions causing *rapid complete regression of tumor* though not of nerve paralysis. Toxins stopped in last week of January 1916; patient began to vomit; very drowsy; in coma for 3½ weeks; weight fell to 89 pounds; then began to improve, gained 28 pounds in 7 weeks; *complete regression of cerebral metastasis; speech and sight normal; nerve paralysis subsided*; symptoms of eunuchism apparent when he recovered from coma; no further recurrence or metastases; in good health. Mild hypertension in 1942; slight hemiplegia, 1945; moderate arteriosclerosis 1946; died coronary occlusion and arteriosclerotic heart disease November 23, 1948, aged 63. (Detailed history deserves study.) (6; 10; 67; 139, case 23)

33

57. (FOLLANSBEE): Mrs. D.M.W., aged 23; recurrent small round cell sarcoma of gluteus maximus muscle. Onset February 1915; motion of hip joint steadily diminished; tumor grew slowly until after birth of child, October 10, 1915; loss of 35 pounds; severe pain; surgical removal (tumor weighed 24 ounces); prompt recurrence, size of hen's egg. February 2, 1916, toxins (Tracy X and XI) started; first dose into tumor, later into region of growth; *complete regression in 3 weeks*. Toxins stopped for 1 week; prompt recurrence on inner thigh (adductor muscles); toxins resumed; given into tumor daily; tumor grew to size of grapefruit, *then broke down and discharged necrotic tumor tissue; disappeared completely during toxin therapy given for 8 months*. Had 4 more children; in 1956 ulcerative colitis with peritonitis; operated; seriously ill, but recovered; alive and free from any evidence of recurrence in October 1958. Intractable regional ileitis of half of small intestine with fistula into bladder and rectum; death January 1968 at age 73. (10; 67; 128)

55

SERIES A, INOPERABLE SUCCESSES

Years Traced
After Onset

58. (DONALDSON): Female, aged about 20; recurrent inoperable sarcoma of scalp. Date of onset not stated. Primary tumor excised; local recurrence. In 1918 toxins for over 4 months; shortly after first febrile reaction tumor began to shrink; *complete regression in a month*; no further recurrence; alive and well 1928. (10; 193) 10
59. (MACLEAN): Male, aged 2; recurrent rapidly growing angiosarcoma of right cheek; date of onset not stated. Primary growth excised; prompt recurrence. 1918 toxins for 2½ months directly into tumor; little febrile reaction; *complete regression in a month*; no further recurrence; alive and well 1943. (10) 25
60. (CALKINS): Mrs. M.M., aged 26; inoperable mixed cell sarcoma of ovary; extensive involvement of intestines and pelvis; onset September 1919; exploratory operation January 29, 1920; large degenerated left ovary, large cauliflower masses between tumor, cecum, sigmoid flexure and rectum, appendix size of large cucumber; bilateral salpingo-oophorectomy, panhysterectomy, appendectomy; impossible to remove areas of involved intestine. Toxins begun a week after operation; given steadily for 12 months; *complete regression of metastatic growths*; no further recurrence or metastases. Patient alive and in excellent health in 1927. (10; 67) 7

Parke Davis XII and XIII (10 cases)

These commercial preparations of Coley's toxins were available from early 1907 to 1950. (137; 139)

61. (PILCHER): Male, aged 55; inoperable round cell sarcoma of abdominal wall. Date of onset not stated; exploratory operation, specimen removed. August 1908, toxins for 4 months; *gradual complete disappearance, gained 20 pounds*; well and free from recurrence 1914. (51, p. 165; 67) 6
62. (OCHSNER): Mrs. V.H., aged 17; inoperable small round cell sarcoma of axilla. Onset February 1910; extensive operation March 11, 1910; mass size of grapefruit excised, but involved areas could not be completely removed as axillary nerves and vessels were surrounded. March 26, 1910, toxins injected into deltoid; febrile reactions, 102°-105°F.; given 6 months; *remains of growth regressed completely; no recurrence*. Married and had 3 children; alive in excellent health in 1946. (10) 36
63. (POLLAK): P.H., female, aged 22 months; inoperable angiosarcoma of mediastinum, causing severe pressure erosion of spine and ribs and par-

SERIES A, INOPERABLE SUCCESSES

Years Traced
After Onset

alysis of both legs. Onset at 5 months in December 1922; child suddenly stopped walking at 21 months; total inability to stand due to paresis of both legs; mass between scapula and spine; anemia. Exploratory operation by Lilienthal April 15, 1924; condition inoperable, removed part of tumor for biopsy. April 25, 1924, toxins injected into gluteal muscles daily for 11 days; marked febrile reactions (to 106°F.); *extraordinarily rapid wound healing; anemia became temporarily worse, then blood picture rapidly improved; child began walking 3 weeks after first injection; in next few months pertussis, measles and bronchitis developed, all severe; complete regression of tumor; resected ribs regenerated; child developed and grew normally; married and had 2 normal children; alive and well in 1975.* (10; 115, 132; 139, Case 28)

52½

64. (BLUM): Mrs. E.A., aged 37; malignant myoma uterus weighing 15 pounds removed surgically. Onset 1923; x-ray examination 1927 indicated extensive metastases to femur, sacrum and skull; anemia, poor general condition. July 21, 1927, toxins in large doses; *complete recovery; gained weight and strength; no recurrence or further evidence of skeletal metastases; alive and well 1933.* (60; 67)

10

65. (CRAWFORD): L.V.McN., male, aged 26; recurrent reticulum cell sarcoma, primary in bicipital region with metastases in axilla and abdominal wall. Onset November 1927; primary growth excised February 1928; recurrence under left arm a month later; biopsy; 1 x-ray treatment May 29, 1928; toxins then begun, given with intervals of rest for 5 years; *at first further metastatic nodules appeared but they regressed under continued treatment; no further metastases after autumn 1931; in excellent health except for appendectomy in 1952; alive and well 1975.* (10; 115)

47½

66. (R.S. FOWLER): C.S., female, aged 21; inoperable neurofibrosarcoma of popliteal space. Onset February 1929; exploratory operation May 14, 1929; excision of tumor impossible because of involvement of vessels and nerves; 2 specimens removed. May 26, 1929 toxins: *tumor disappeared in 5 to 6 weeks; evidence of recurrence; toxins resumed; given with intervals of rest for 6 years; complete regression; no further recurrence; married and was said to have had a child; alive and well 1945.* (10)

16

67. (BURKE): H.R., female, aged 19; terminal sarcoma of neck, face, submaxillary region involving bones, subcutaneous tissues, especially forehead, parietal regions, left cheek and jaw. Onset March 1931, hard nodular mass in neck below angle of right jaw; incision, x-ray therapy produced no relief; tracheotomy for edema of glottis; radium given with-

out benefit; bilateral chronic mastoid developed; operation January 28, 1932; radium again; marked exophthalmos of both eyes; morphine required. June 12, 1932, toxins intramuscularly *caused improvement*, but were stopped because of painful indurations; recurrence; x-ray therapy; recent recurrent nodules disappeared, leaving masses in right submaxillary and submental regions; extensive mass in floor of mouth; *2 more courses of toxins intravenously, marked reactions; all tumor masses disappeared; part of tongue sloughed; complete recovery.* Married and had children; alive and well in 1958, then severe pneumonia; gastric ulcer 1962; lost 16 lbs., hospitalized January 1963; gastric symptoms exacerbated, then improved; early 1964 ear infection, pneumonia; then constipation, ascites, pretibial edema; explored May 18, 1964; extensive metastases to ovaries from inoperable gastric carcinoma; bilateral oophorectomy; palliated until death, September 21, 1964. (10; 67)

33½

68. (COLEY): N.P., female, aged 26; inoperable retroperitoneal sarcoma, unclassified; firm mass filled whole left lower abdomen and pelvis; clinically regarded as neuroblastoma, myosarcoma or liposarcoma. Onset 1928; needle biopsy; traction to leg; local applications, diathermy, physiotherapy; *recovered full use of limb; well for 5 years.* Pain recurred; exploratory operation; pain increased; large bulging mass (27 cm. in diameter) arising from pelvis extending almost to midaxillary line in flank filling lower right quadrant to umbilicus; x-ray examination showed that upper anterior half of right ilium involved, apparently from external pressure erosion; x-ray therapy; apparent complete regression in 3 months. June 3, 1935, 20 injections toxins in 28 days, first 11 intramuscularly, next 7 intravenously and last 2 intramuscularly; febrile reactions to 105°F. *Patient gained weight, general condition improved;* married in autumn of 1935; artificial menopause (radiation-induced) in 1936; menstruation resumed March 6, 1937; periods regular after August 1937; 2 normal pregnancies and confinements 1939 and 1940; no recurrence or metastases; alive and well in 1968. (10; 128)

40

69. (DODD): Mrs. Y., aged 52; extensive recurrent inoperable desmoid sarcoma of left erector spinae muscle. Onset prior to March 1936; primary growth excised April 30, 1936; postoperative x-ray therapy during next 18 months did not prevent recurrence in October 1936, nor control it; another excision attempted November 1937; skin, scapula, ribs and pleura fused into homogeneous mass of tumor tissue; biopsy; operation abandoned; further deep x-ray therapy proved ineffective; condition hopeless; huge lumpy mass. April 2, 1938, toxins injected into shoulder

SERIES A, INOPERABLE SUCCESSES

Years Traced
After Onset

muscles, continued weekly for 8 months; marked reactions; *complete regression* by absorption and saneous discharge in 20 months; second course of toxins January 29, 1940; given every other week alternating with T.A.B. vaccine to relieve causalgic pains continued 7 months; *complete resolution of scar tissue*; no further pain after August 1940; alive and well 1957. (Treated as out-patient, as she had 4 children and could not afford hospitalization.) (10)

21

The following case received Type SKI XIV, made at Sloan Kettering Institute

70. (HASLEY): Male, aged 53; generalized hemangioendotheliomata (site of primary unknown), with lesions on hands, arms, face, head, body and legs. Onset December 1946. Some lesions bled and were painful; telangiectasia under tongue, but no bleeding from mucous membrane. Penicillin, rutin and x-ray therapy (to 3 lesions on face) tried without benefit; March 24, 1947 surgical removal of a few tumors on the abdomen and head, some by scalpel, other by electrodesiccation; aspiration biopsy of tumor on left arm; x-ray (1200 to 1800 r) for a few lesions without apparent benefit. April 1, 1947, toxins injected intravenously, 12 in 18 days; febrile reactions averaged 102°-104°F.; *within 5 days the tumors were quite dry and falling off, with considerably less bleeding of the irritated lesions; marked regression in 8 weeks; complete regression of all tumors; little atrophy and no telangiectasis; no evidence of disease.* Well for 11 years; in spring 1958 malignant melanoma developed on right shoulder; excisional biopsy on June 13, 1958; well, no further evidence of disease July 1958; advised to have further toxin therapy but refused; March 1959, metastases to cervical region and axilla; axillary mass biopsied; finally consented to further toxins March 21, 1959, only a few injections given; disease progressed, liver metastases; death June 21, 1959. (10)

14½

COMMENT: It is of interest that only seven patients in this successful series received radiation therapy prior to toxin therapy.

It was thought wise to analyze the preceding 70 cases to see if certain factors in the patient or in the treatment could account for the successful results. The classification with respect to operability or inoperability was made by the surgeon when the case was treated. This designation undoubtedly varied at least to some degree with the surgeon, and therefore the distinction is not too exact since no precise criteria are available for the differentiation. "Primary inoperable tumor" refers to inoperability at the time when toxin therapy was first considered, and "recurrent inoperable tumor" refers to inoperability after recurrence had taken place.

SERIES A: INOPERABLE SUCCESSES: ANALYSIS

STAGE OF DISEASE WHEN TOXINS WERE BEGUN:

Primary inoperable, 32 cases:

#1, 3, 4, 8, 11, 14, 15, 18, 20, 25, 27, 28, 30, 36, 37, 43, 45, 46, 48, 49, 50, 51, 52, 53, 54, 56, 60, 61, 62, 63, 66, 68.

Recurrent inoperable, 34 cases:

six times, 1 case, #47

three times, 5 cases: #6, 9, 22, 33, 34

twice, 5 cases: #2, 10, 16, 24, 44

once, 23 cases: #5, 7, 12, 13, 17, 19, 21, 23, 26, 29, 31, 32, 35, 38, 39, 41, 42, 47, 55, 57, 58, 59, 69

Metastases present, 9 cases: #6, 16, 20, 40, 44, 60, 64, 65, 70

Cachexia or ascites present, general condition poor, or terminal, 20 cases:

#1, 3, 4, 7, 8, 13, 23, 34, 39, 40, 41, 44, 48, 50, 52, 53, 54, 57, 63, 67

Concurrent complications, 2 cases:

Pregnancy (#12, normal confinement)

Bright's disease (#30, no ill effects)

OTHER FORMS OF TREATMENT

Radiation prior to toxins, 7 cases:

#33 - several courses of x-ray therapy; died x-ray cancer 50 years later

#42 - brief course x-ray therapy caused severe dermatitis

#65 - 1 x-ray treatment

#67 - radium and x-ray therapy (large amount) did not control disease

#68 - x-ray therapy (8,500 r) caused regression

#69 - x-ray therapy did not prevent or control recurrence

#70 - x-ray therapy (small amount) did not control disease

Surgery prior to toxins, 54 cases:

Biopsy and/or exploration, 32 cases

#1, 3, 4, 5, 8, 11, 14, 15, 17, 18, 20, 25, 27, 28, 30, 32, 36, 37, 43, 44, 49, 50, 51, 52, 53, 54, 56, 61, 63, 66, 68, 70

Incomplete removal, 12 cases

#6, 19, 23, 24, 26, 33, 40, 45, 46, 47, 60, 62

SERIES A, INOPERABLE SUCCESSES, ANALYSIS

More than 1 operation, 17 cases

#2, 5, 6, 7, 9, 10, 16, 19, 22, 23, 24, 32, 33, 34, 35, 47, 69

Untreated, 22 cases

Primary inoperable, 1 case: #48

Recurrent or metastatic (primary tumor removed), 21 cases:

#7, 12, 13, 16, 21, 22, 23, 26, 31, 34, 35, 38, 39, 41, 42, 55, 57, 58, 59, 64, 65

Treatment during toxin therapy, 7 cases

Radiation, 2 cases:

#32 - a few x-ray treatments

#33 - x-ray therapy, mostly given prior to toxins

Evacuation of necrotic tumor tissue, 5 cases:

#8, 15, 17, 30, 48

Treatment after toxin therapy, 13 cases

Radiation, 2 cases:

X-rays, 136 in 28 months, finally controlled disease but extensive x-ray cancers developed some years later: #28

X-ray treatment caused some regression, although both x-ray and radium therapy prior to toxins produced no apparent benefit: #67

Surgery, 6 cases:

Remains of growth excised, #54

Scar tissue or fibrous stroma excised, #7, 10, 13, 22

Amputation, #6

Plastic operation, #9

IMMEDIATE AND FINAL EFFECTS OF TOXIN THERAPY ON MALIGNANT LESIONS

Recurrence of metastases developed during or shortly after toxin therapy; complete regression with further toxin therapy, 10 cases:

#6, 14, 23, 39, 41, 56, 57, 65, 66, 67

SERIES A, INOPERABLE SUCCESSES, ANALYSIS

Tumor continued to regress after toxins stopped, 7 cases:

#1, 3, 5, 7, 56, 63, 64

Malignancy destroyed: fibrous stroma remained: 3 cases:

#7, 22, 54

Complete regression due to toxins; traced 5 to 78 years: 64 cases

Complete regression apparently due to toxins: traced four years: 4 cases:

#8, 16, 30, 45

Complete regression, control of disease due more to radiation than toxins: 2 cases:

#28, 68

(Note: Case 68 developed radiation menopause for a year, but recovered, bore 2 healthy children—effect of toxins?)

DEVELOPMENT OF OTHER FORMS OF CANCER 5 TO 50 YEARS LATER (10 CASES)

Hepatoma, 24 years after onset of sarcoma, #27

X-ray cancer (basal-cell epithelioma) 20 years after onset of sarcoma; repeated surgery, finally disarticulation of shoulder; death 50 years after onset of sarcoma; autopsy showed also a bronchiogenic carcinoma, #33

Carcinoma in lumbar region at site of former sarcoma, 37 years later, #40

Carcinoma of stomach, 45 years later, #52

Carcinoma of stomach, 20 years later, #49

Carcinoma of stomach, 43 years later, #67

Epithelioma of hard palate, 5 years after sarcoma of naris; not controlled by radium; death 9 years after onset of sarcoma, #55

Malignant melanoma 11 years after onset of hemangioendotheliomata; excisional biopsy; brief course toxins, death 14½ years after onset sarcoma, #70

(Note: The foregoing 8 patients died from their second neoplasm; the following did not)

Epithelioma of neck, 59 years after onset of sarcoma, #2

Basal-cell epithelioma of nose, 45 years later, #15

X-ray carcinoma of abdominal wall, multiple, about 8 years after onset of sarcoma, #28

SERIES A, INOPERABLE SUCCESSES, ANALYSIS

CONDITIONS OTHER THAN CANCER, CAUSING DEATH 5 TO 47½ YEARS AFTER ONSET OF SARCOMA (25 CASES)

Accident (fell downstairs) – 1 case, #34
Pneumonia; influenza – 1 case, #51
Bronchopneumonia (also arteriosclerosis) – 2 cases, #15, 28
Pulmonary tuberculosis – 1 case, #29
Herpes, involving Gasserian ganglion – 1 case, #26
Hemorrhage due to gastric or duodenal ulcer – 2 cases, #24, 35
“Unrelated causes” – 1 case, #23
Cardiovascular diseases – 11 cases, #1, 2, 3, 7, 15, 31, 46, 47, 49, 54, 56
Regional ileitis, ulcerative colitis – 1 case, #57
Cerebrovascular disease – 4 cases, #39, 41, 47, 50

PATIENT ALIVE AND IN GOOD HEALTH WHEN LAST TRACED 4 TO 78 YEARS AFTER ONSET OF SARCOMA (40 CASES)

Cases #4-6, 8-14, 16-22, 25, 30, 32, 36-38, 42-45, 48, 53, 58-66, 68, 69

Note: In addition to the above 67 determinate cases traced 4 to 78 years, four more inoperable successes were found with microscopic confirmation of diagnosis in which complete regression occurred but the patients were traced less than four years. These were all treated effectively as to site, frequency and duration of injections, and are believed to have been permanent successes, but since they were not traced they have been excluded from the above series. The tumors were:

- 1) spindle cell sarcoma of the abdominal wall and pelvis, biopsy only, complete regression under toxins alone given 5 months; traced 2½ years;
- 2) spindle cell sarcoma of the omentum with local metastases and emaciation; biopsy only, complete regression under toxins alone for 4 months;
- 3) intra-abdominal sarcoma, biopsy only, complete regression under toxins alone, traced well 3 years;
- 4) fibrosarcoma of thigh of rapid growth, biopsy only, complete regression under toxins alone, traced well 3 years.

SERIES A, INOPERABLE SUCCESSES, DETAILED HISTORIES

CASE 1: Inoperable spindle cell sarcoma of the abdominal wall and pelvis involving the bladder, confirmed by microscopic examination by Dr. Harlow T. Brooks, pathologist.

PREVIOUS HISTORY: J.F.F., male, aged 16, born in Germany, living in New York City. The family history was negative for malignancy. There was no history of syphilis. Onset, in October 1892 pain developed in the abdomen. About two months afterward a hard lump was felt in the lower abdomen. This increased slowly but steadily in size. Occasionally the pain in the tumor was very severe, being intermittent in character. There was no loss of weight. Examination on admission to Postgraduate Hospital showed a hard tumor measuring about 15 by 13 cm. which was apparently 13 cm. thick. This was about three months after onset. There was no fluctuation. The growth involved the entire thickness of the abdominal wall, was attached to the pelvis and, judging from the symptoms and position, evidently involved the bladder. The patient was unable to retain urine when admitted. The general condition was poor, the patient being confined to bed most of the time.

EXPLORATION: An exploratory laparotomy was performed by Dr. L. Bolton Bangs, professor of Genito-Urinary Surgery at N.Y. Postgraduate Hospital and Medical School. The condition was found to be inoperable and the patient was referred to Dr. William B. Coley.

TOXIN THERAPY (Type IV): Injections were begun by Coley on January 24, 1893, and were given directly into the tumor mass. They were continued in slightly increasing doses until May 13, 1893, a little less than four months. The Memorial Hospital records state: "These injections produced within eight hours a rise in temperature from 0.5° to 6°F., the pulse running from 100 to 106. The chill and tremblings were extreme. For the severe headache following the chill, phenacetine was given. Aseptic precautions being successful no pus was produced in spite of the many needle punctures. The tumor gradually diminished in size, at times for a few days after injection it would be enlarged, but the final diminution was indisputable." The dosage used varied between 0.5 and 1.5 cc. of erysipelas, and 0.25 and 0.5 of prodigiosus. Coley stated that the chill usually occurred within the first half hour after injection, though occasionally it was delayed an hour. Sometimes local redness and swelling accompanied the reaction. Usually both local and constitutional symptoms had subsided at the end of 24 hours.

CLINICAL COURSE: The patient was discharged on May 13, 1893, at which time the tumor was 1/5 the size it had been on admission. No further treatment was given. At examination two weeks later the tumor was no longer visible. Palpation

SERIES A, INOPERABLE SUCCESSES, DETAILED HISTORIES

revealed a small, movable mass, 5 cm. in diameter at the site of the former growth. (When the toxins were begun the mass measured 14×16.5 cm.) The enlarged nodes in the right inguinal region still persisted. The patient had gained 10 pounds in weight in the previous four weeks. By August 1, 1893 the remains of the growth had almost disappeared, save for a small mass palpable in the right iliac fossa. The inguinal nodes were still enlarged. The patient was kept under constant observation. He was able to resume his regular work and received no further treatment. He was presented before the N. Y. Academy of Medicine on November 15, 1894. Six years later he developed a primary lesion of syphilis, which ran the usual course and was finally cured by mixed treatment. He was presented by Coley before the N.Y. Surgical Society in 1900 and again on February 13, 1907, in perfect health. He remained in very good health and free from recurrence until his sudden death on February 26, 1919, over 26 years after toxin therapy. The death was investigated by the Chief Medical Examiner and the cause listed as chronic myocarditis, a contributory cause being "fatty degeneration of the heart". (7)

REFERENCES: 7; 10; 14; 16; 17, p. 70; 41; 42; 51; 139

CASE 2: Twice recurrent inoperable angiosarcoma of the nasal septum and nasopharynx, involving the base of the skull, confirmed by microscopic examination.

PREVIOUS HISTORY: W.S.G., male, aged 16, of Nyack, N.Y. The family history was negative for cancer, tuberculosis or venereal disease. At the age of 10 the patient fell, striking his nose, which bled quite freely. About three years later, in July 1891, he began to have nosebleeds. These occurred frequently with much loss of blood and difficulty in breathing. The family doctor was consulted and he found a neoplasm. The patient then came under the care of Dr. D. Brysan Delavan and was admitted to Memorial Hospital in July 1892. The growth involved the nasal cavity and septum, extending back to the posterior pharyngeal wall and the retronasal spaces to the basilar processes of the occipital bone and the sphenoidal sinuses. Necrosed bone was felt in the roof of the nose.

EXPLORATION: An exploratory operation was performed by Delavan. "A speculum was introduced into the nose and the tumor was found to involve the nasal pharynx and to have a number of ramifications at the base of the skull and to be impossible to remove without endangering the life of the patient. There was profuse hemorrhage which was controlled by packing the entire cavity with iodoform gauze."

CLINICAL COURSE: The patient was discharged unimproved on July 14, 1892. During the week of January 15, 1893 he had two rather severe hemorrhages.

SERIES A, INOPERABLE SUCCESSES, DETAILED HISTORIES

There was also a great deal of discharge from the nose, but no pain. The patient was readmitted to Memorial Hospital in late January 1893. At this time there was a large tumor mass filling the nasal fossa, obstructing air so that he breathed entirely through his mouth. The tumor bled very easily when handled. There was slight swelling of the left side of the nose and face. At this time the patient weighed about 130 pounds. He was given iron and strychnine and other tonics by Delavan and the nose was sprayed daily with a special mixture. He remained two months and was discharged improved in weight and strength, the anemia having disappeared.

SURGERY: Delavan reported: "The tumor was removed by Dr. Robert Abbe, with prompt recurrence. Again Abbe operated, at St. Luke's Hospital, taking away most of the superior maxilla on the left side. The growth again promptly recurred, and in a few months attained considerable size. Abbe made two attempts to treat it by the electrolytic method. These were unsuccessful because of the great pain they caused, the patient being unable and unwilling to endure the applications." The patient was then referred to Dr. W. B. Coley for toxins.

TOXIN THERAPY (Type IV): Injections were begun in June 1893, two years after onset. At first they were given daily at Dr. William Bull's private hospital on 33rd Street. The patient was then discharged, returning to the hospital for his injection every other day for two months. For two months following this, the injections were given twice a week, then for a period once a week, and finally once in two weeks. The exact duration of treatment was not recorded. The injections were made in the left cheek about 2.5 cm. from the nose on the affected side. The effect of the first injections was very pronounced: a violent reaction, attended by fever, chill and malaise and in about half an hour the patient would get up again and dress. He stated that there was very little pain at the site of injection, but that the cheek would swell up for a short time. Delavan stated: "After a time improvement began to be manifest. This continued uninterruptedly until all trace of the growth had disappeared."

CLINICAL COURSE: There was no further recurrence. The patient married and had five exceptionally bright and healthy children. He remained in excellent health and was examined by Coley from time to time, the last examination being in 1915, 22 years after toxin therapy. His only serious illness occurred in 1920, when he developed a severe attack of erysipelas. He reported in January 1944 that he was "working six days a week, nine hours a day in the office of the General Electric Company in Pittsfield, Mass." In March 1944 he had a bad hemorrhage from the nose on the side which had been operated upon in 1892. This was due to a ruptured blood vessel and was treated by a local physician, causing no further trouble. The patient retired from work on April 1, 1944, at the age of 68. He remained in good health during the next five years, his only complaint being that

SERIES A, INOPERABLE SUCCESSES, DETAILED HISTORIES

he was a little deaf. His weight in 1946 was 124 pounds, his height being 5 feet 5 inches. He had an attack of coronary thrombosis in April 1949, but recovered. In May 1950 a small epithelioma was removed from the back of his neck. He remained in fairly good health until January 15, 1951, when he had a severe heart attack. He died early next morning, the cause of death being heart failure. He was 75 years old, and death occurred 59½ years after onset of the sarcoma of the nasal septum.

REFERENCES: 10; 67

CASE 3: Extensive inoperable fibrosarcoma of the abdominal wall, confirmed by microscopic examination by Dr. W. F. Whitney, Pathologist at the Massachusetts General Hospital, Boston. He reported: "A small, dense, ill-defined, whitish-looking mass, which on microscopic examination was found to be made up of large numbers of small cells with a tendency to form fibres . . . the diagnosis is fibrosarcoma." (120)

PREVIOUS HISTORY: Mrs. E.J.L., female, aged 29, of Melrose, Massachusetts. The patient's father had died of tuberculosis, but the family history was negative for malignancy. The patient had been married for ten years, and had one son born in 1884, when she was 20, a difficult delivery. She wore tight corsets during her pregnancy. The baby was said to be "undernourished" at birth. Onset, she first noticed a small swelling in the abdominal wall in late April 1893. This increased in size with considerable rapidity and was associated with pain in the left side. On August 16, 1893, the patient consulted Dr. Maurice H. Richardson, of Boston, Mass. On examination he found a tumor filling the left side of the abdomen, which clinically he believed was connected with the Fallopian tube. The patient was pale and cachectic, there was no color in the face and rather a waxy look.

EXPLORATION: On August 31, 1893, an exploratory operation was performed by Richardson at Massachusetts General Hospital, assisted by Dr. Farrar Cobb. An incision directly over the medial line revealed an inoperable tumor involving the abdominal wall but not the tubes. A second incision was made over the most prominent part of the tumor, revealing a firm growth, which Richardson stated "in its gross appearance . . . was clearly malignant". As the condition was inoperable, a small portion was removed for microscopic examination. Richardson gave a very bad prognosis, but decided to refer the patient to Dr. W. B. Coley for a trial of the toxins.

TOXIN THERAPY: Injections were begun early in October 1893, using the mixed filtered preparation (Type IV). *Local injections into the tumor were repeated daily for six*

SERIES A, INOPERABLE SUCCESSES, DETAILED HISTORIES

weeks causing marked reactions. Within two weeks after the first injection, improvement was very evident. The patient's general condition suffered but little and she was able to be up and about almost the entire time. Little reaction followed moderate doses, and it required very large doses to raise the temperature to 101° or 102°F. On December 22, Coley advised the patient to go home for a month to allow the inflammation caused by the local injections to subside, so that the exact amount of improvement caused by the treatment could be determined. Richardson found her improvement so marked after three weeks at home that he wrote Coley he saw no reason why she should not be permanently cured. She returned to New York on January 12 and remained under treatment another month. The tumor steadily decreased in size and had apparently disappeared at the time of her discharge about February 10, 1894. On April 3, 1894 the patient was carefully examined by Richardson and Coley and they were unable to find any trace whatever of the tumor. All signs of inflammatory induration had likewise disappeared. She had gained several pounds in weight and her general health had never been better. This case was one of several reported by Coley before the American Surgical Association on May 31, 1894, and in the discussion of this paper Richardson stated: "In this case there can be no doubt, according to the accepted methods of diagnosis, that the woman had a malignant and necessarily fatal disease. The mass filled the right lower quadrant when I operated. I first incised in the median line and came down upon the tumor. I then made an incision in the lateral region with the same result. There was nothing to be done surgically. I took out a section and had it examined. It was pronounced sarcoma. The patient was sent to New York in October; when she came back (in February) there was not the slightest sign that could be detected. Unless the diagnosis was entirely wrong, unless the history, gross appearance and microscopic examination were entirely wrong, this was a case which must have died sooner or later." Whitney, in a personal letter to Coley, also stated that there was not the slightest doubt as to the diagnosis. (67)

CLINICAL COURSE: On March 8, 1895, Richardson again examined the patient and found no trace of the tumor remaining, but at the site of the exploratory incision there was a ventral hernia. In writing Coley about this Richardson stated: "I look upon this case as a most extraordinary one . . . which gives hope that we are on the verge of some great discovery in the treatment of this deplorable condition." (67)

The patient remained perfectly well until 1909 when she developed a fibroid tumor of the uterus which Coley removed by abdominal hysterectomy. The abdominal wall at that time was found to be perfectly normal with no trace of the original sarcoma. The patient was shown before the Clinical Congress of Surgeons of North America on November 12, 1912, in good health. She died in the spring of 1918 of "heart failure", having enjoyed good health until about

SERIES A, INOPERABLE SUCCESSES, DETAILED HISTORIES

three years prior to her death. She had complained of a slight stomach ache during the early evening. On going to bed she had some dyspnea, and then quietly passed away. The patient's husband requested the attending physician to make an examination of the abdominal region at the time of her death, thinking that perhaps there had been a recurrence, but the findings were entirely negative.

NOTE: In 1898 Richardson presented the case of J.R. before the American Surgical Association. This boy had a very extensive recurrent inoperable lymphosarcoma involving the axilla and scapula which was incompletely removed at operation. The remains of the growth then regressed completely following a very severe wound infection.

In presenting this case Richardson stated: "The case seems of interest in connection with the subject of disappearance of malignant tumors under the influence of a general toxemia, whether artificially or accidentally produced. The occasional cure of malignant disease by internal medication excites not only interest by incredulity. Scepticism may be so extreme that carefully observed cases are thrown out for one reason or another, though I cannot but think chiefly for the reason that they were successful.

"As an illustrative example I would cite one of the most extraordinary cures of sarcoma that I have ever seen. In this case Dr. Garland and myself at the time of operation made the diagnosis as hopeless malignant disease of the abdominal wall. Dr. Whitney made a careful microscopic examination of the tumor and reported it as fibrosarcoma. After some months' treatment with Coley, the tumor, though as large as a child's head, disappeared." (The abdominal wall had been infiltrated to a thickness of at least six inches, he added.) He stated in conclusion:

"If a cure by means other than surgical is, from the very fact of cure, declared sufficient proof of a mistaken diagnosis, there seems little use in presenting evidence. I am convinced, however, that a considerable number of tumors, pronounced malignant, disappear under local or systemic conditions which are artificially produced. The curative influence of micro-organisms upon malignant growth, whether during the course of an accidental wound infection or under the influence of deliberate toxin injection, is a hopeful indication of far-reaching possibilities for good." (173)

REFERENCES: 17; 19; 20; 67; 139; 173

CASE 4: Inoperable spindle cell sarcoma of the tonsil, palate and nasopharynx, confirmed by microscopic examination by Dr. James W. Williams.

SERIES A, INOPERABLE SUCCESSES, DETAILED HISTORIES

PREVIOUS HISTORY: T.C., male, aged 16, clerk, of Irish-American parentage. The family history was negative for malignancy or for malignant disease. The patient had always suffered from catarrhal trouble, hypertrophy of the tonsils and acute tonsillitis in winter. He had never been strong or robust. Onset in 1893 a tumor developed, and in October the patient was examined by Dr. W.B. Coley in consultation with Dr. Walter B. Johnson of Paterson, N. J. The growth was found to involve the entire soft palate, the pillars of the fauces, the region of the tonsils, extending forward over the soft palate to within half an inch of the incisor teeth, backward and downward, involving a portion of the pharyngeal wall, the whole base of the tongue, the epiglottis and the upper part of the larynx, but not extending to the true vocal cords. The affected parts were thoroughly impregnated with sarcomatous deposits, and the soft palate was increased to about three times its normal thickness. The growth consisted of cauliflower-like granulations, varying in size from a kernel of rice to a pea. The uvula was entirely destroyed and the cervical lymph nodes were enlarged. (For condition of mouth at this time, see 110, Figure 2.) The patient had lost a considerable amount of weight and strength, but was not cachectic. His weight was 85 pounds. He had difficulty in swallowing and could not breathe through his nose. The tumor was so extensive that Coley expressed very little hope of any permanent benefit being derived from the toxins, but advised giving the treatment a short trial.

TOXIN THERAPY: Injections were begun on October 21, 1893, the initial dose being 15 minims of the Type III preparation (streptococcus filtrate). The dose was increased each day until it reached 60 minims. After a short time the *Bacillus prodigiosus* filtrate was added. The dose consisted of 5 minims of prodigiosus to 35 minims of streptococcus, kept in separate bottles and mixed at the time of each injection (Type IV). The site was sometimes the arm, sometimes the leg, intramuscularly. The injections generally caused swelling, redness and pain, which appeared almost immediately after injection and lasted from 12 to 36 hours. The febrile reactions varied from 99° to 103°F. The patient always felt cold and after some injections had chills, accompanied by nausea, vomiting and pain in the back and head. After the chills subsided, profuse perspiration would follow and the patient would then become much more comfortable. The injections were continued until early June 1894, over seven months, with occasional intervals of rest. The patient had a dozen chills in this period, four of them violent, and after the most severe one the temperature rose to 103°F., and the chill was followed by marked cyanosis, pain in the head and neck, rapid and feeble pulse. The nose and lips were subsequently affected by a severe herpetic eruption, and the general physical condition was such that he remained in bed two weeks and received no further injections in this period. Johnson did not understand what had caused the severity of this reaction, as the same dosage from the same bottle of toxins was used before and after this without any previous or subsequent marked disturbance. (It is possible that the needle pricked a vein, with a dose much too high for intravenous therapy.)

SERIES A, INOPERABLE SUCCESSES, DETAILED HISTORIES

The result of toxin therapy was a steady slow improvement in the condition. Two weeks after the first injection the soreness had left the patient's throat to such an extent that he was able to swallow not only fluids without pain, but also solids. Within two or three weeks he had gained four pounds. The masses began to disappear, improvement continued and the growth gradually regressed, partly by absorption, partly by necrosis. The general condition continued to improve during the entire period of treatment. The final injection was given in early June 1894.

CLINICAL COURSE: By the autumn of 1894 the patient had gained 22 pounds in weight and the physical condition was excellent. He stated at this time that he had never felt so well.

FURTHER TOXIN THERAPY: Johnson believed that there was one point in the mouth which looked slightly suspicious, and he decided to resume the injections for a short time. He stated that the same thing had occurred once before after the injections had been suspended temporarily, and that it had quickly regressed under further treatment. Thus the total duration of treatment in this case was about a year. (For condition of mouth in October 1894, see 110, Fig. 1, p. 616.)

ACCIDENTAL ERYSIPELAS INFECTION: Three months after the toxins were stopped, the patient developed facial erysipelas. The extent or duration of this infection is not recorded.

CLINICAL COURSE: The patient was seen periodically and found to be free from further recurrence. He was last examined by Johnson in June 1915 and found to be in very good health. This was 22 years after onset and recovery under toxin therapy. Subsequent attempts to trace him failed.

REFERENCES: 17; 45; 55, Case XII; 67

CASE 5: Inoperable retroperitoneal round cell sarcoma, apparently recurrent from a primary growth in the uterus; based on microscopic examination at the New York Postgraduate Hospital.

PREVIOUS HISTORY: Miss M.L., aged 35, seamstress, born in Ireland. The family history was negative for malignancy. The patient first menstruated at 15, and was regular until 1889, when she began to complain of menorrhagia, profuse leukorrhea, pain in the back and lower abdomen and failing health.

SURGERY: In June 1893 a hysterectomy was performed by Stannard at the New York Postgraduate Hospital for a large fibroid tumor. The adnexa were also

SERIES A, INOPERABLE SUCCESSES, DETAILED HISTORIES

removed. The patient made a good recovery and remained well until October 1893, when shooting pains developed in the back and side. The patient was told she had cancer. A second operation was attempted in December 1893. The incision was made in the left iliac region, but as the condition was found to be inoperable, the wound was closed.

CLINICAL COURSE: She was then referred to Dr. W. B. Coley, and was admitted to Memorial Hospital on January 12, 1894, complaining of the old pain in the back and abdomen. There was no vaginal discharge. Examination on admission revealed two scars, one in the median line and one in the left iliac region.

TOXIN THERAPY (*Type IV, filtered*): Injections were begun by Coley on January 12, 1894, and were made daily or every second day for about eight weeks (dosage was not recorded). Because the growth was inaccessible, the injections were made in the thigh and the patient complained of pain and soreness at the sites of injection. She also complained of considerable pain in the abdomen and side. The tumor diminished considerably in size during these two months.

FURTHER SURGERY: Coley decided to make an attempt to remove the remains of the growth. He performed an exploratory celiotomy on April 7, 1894 through an incision about 10 cm. long in one of the cicatrices. A digital examination of the abdominal cavity revealed a tumor the size of a goose egg in the left side of the pelvis, in close relation to the iliac vessels. It was decided to allow the tumor to remain as it was considered next to impossible to remove it. The wound was closed. Immediately following this operation the tumor appeared to increase in size.

FURTHER TOXIN THERAPY: Toxins were resumed and continued every second day until the patient complained of soreness at the sites of injection.

CLINICAL COURSE: She then returned to her home in Ireland and during the next few months the tumor gradually regressed and the patient regained her former good health. She remained in Ireland for eight years, and then returned to New York. About February 1, 1908 she noticed a lump in the abdomen and feared another tumor. She had no pain, however, until one week prior to admission to Coley's service at Memorial Hospital on March 11, 1908. Examination revealed a large ventral hernia on the left lower abdomen at the site of one of the laparotomy incisions. Coley's associate, Dr. William A. Downes, performed a left ventral herniotomy (Blake's modified method). A careful examination of the abdominal cavity during the operation revealed no trace of a tumor either in the abdomen or pelvis. The patient was last traced in good health and free from recurrence in 1917, 23 years after toxin therapy.

SERIES A, INOPERABLE SUCCESSES, DETAILED HISTORIES

DISCUSSION: This is one of the rare cases in which the toxins did not destroy the tumor before the injections were discontinued, but the neoplasm regressed completely. In some of Beebe and Tracy's experiments on animals (1907) the tumor continued to regress and finally disappeared after cessation of treatment. (4) However, in the majority of patients in which only a brief period of toxin therapy was given, the disease recurred. Note that because this was an inaccessible growth, Coley gave no injections in or near the tumor, and therefore regression was less rapid than in cases receiving more aggressive treatment (intratumoral or intravenous).

REFERENCES: 51; 67; 128

CASE 6: Extensive, infiltrating, inoperable fibrosarcoma apparently primary in the tendon over the metatarsal bone, several times recurrent in the leg, thigh and gluteal regions, confirmed by microscopic examination by Dr. Farquhar Ferguson, pathologist of The New York Hospital. "Typical structure of fibrosarcoma, with sarcoma elements predominating. Vascular supply fairly abundant."

PREVIOUS HISTORY: F.K., female, age 16. The family history was noncontributory. The patient had measles about ten years before; otherwise she had been in good health. She had never menstruated. She gave a history of repeated trauma to the affected limb: she fell in the street in 1888, injuring her right foot; shortly thereafter two lumps appeared in the region of the injury and grew steadily.

SURGERY: She was operated for fibrosarcoma of the fourth and fifth metatarsal bones of the right foot in 1889 at The New York Hospital.

CLINICAL COURSE: Three years later she received another injury to the foot, which was followed quickly by recurrence.

FURTHER SURGERY: In 1892, Syme's amputation was performed by Dr. William T. Bull, for this local recurrence.

CLINICAL COURSE: In May 1893, she fell downstairs, injuring the stump; shortly afterwards, two lumps appeared at the outer aspect of the stump and very soon after another tumor appeared in the popliteal space, which grew very rapidly. In January 1893 the girl was readmitted to The New York Hospital with a tumor the size of a hen's egg in the stump. The inguinal lymph nodes on the same side were also enlarged and indurated.

SERIES A, INOPERABLE SUCCESSES, DETAILED HISTORIES

FURTHER SURGERY: Another operation was performed early in January 1894 by Bull and an attempt was made to remove as much as possible of the popliteal tumor. It was found very adherent to the vessels and nerve, and not encapsulated, but infiltrating the neighboring muscles. It was possible to make a complete removal. The tumor in the stump was purposely left untouched in order to furnish a guide as to improvement from toxin therapy.

TOXIN THERAPY: (*Type IV, filtered*): Injections were begun in March 1894 by Dr. W. B. Coley almost as soon as the wound had healed, and were given alternately into the groin and stump tumors, and occasionally into the calf of the leg, for about two months, at The New York Hospital, and later under Coley's care at Memorial Hospital. The improvement following the injections was astonishing. The tumor of the stump entirely disappeared, the nodes of the groin could scarcely be felt, and the patient gained 17 pounds in weight and recovered her health completely. In this period of about six months she received 77 injections. She did not have very high temperatures at any time, the maximum being 101.6°F. on September 23, 1894. Most of the time during treatment she felt very well; occasionally she suffered pain in the affected limb. She was presented before the New York Academy of Medicine on November 11, 1894, free from the disease.

FURTHER SURGERY: She remained in good health, but the limb was not straight, and on January 23, 1895, she was operated at Memorial Hospital, an attempt being made to straighten the leg at the knee. The tendons of the internal hamstrings were cut. Another incision was made external to the median line in the popliteal space, but so much thickened scar tissue was present from the previous operation that it was thought best not to attempt further to release the contraction. The leg was straightened as much as possible and put in plaster.

CLINICAL COURSE: The patient made a good recovery and remained well until about October 1895, when a recurrence developed in the gluteal region.

SECOND COURSE OF TOXIN THERAPY (*Buxton VI, Unfiltered*): The toxins were again administered in January 1896, this time using the more potent unfiltered preparation. The tumor diminished in size. The toxins were apparently only given for two months at this time in small doses.

FURTHER SURGERY: The remains of the tumor was removed in February 1896.

CLINICAL COURSE: In the autumn of 1896 signs of returning growth appeared in the popliteal space, as well as in the stump.

FURTHER SURGERY: Amputation at the middle of the thigh just below the trochanter was performed on January 6, 1897, by Coley.

SERIES A, INOPERABLE SUCCESSES, DETAILED HISTORIES

THIRD COURSE OF TOXIN THERAPY (*Filtered Type V*): The injections were not resumed until March 6, 1897, two months after the amputation. The weaker filtered preparation was again used. A slight recurrence again developed in the gluteal region.

FURTHER SURGERY: This was excised with a portion of muscle and tendon on June 9, 1897. *The injections were then continued with occasional intervals of rest for three years, in order to prevent any further recurrence.*

CLINICAL COURSE: The disease did not recur again and the patient remained in excellent health at date of last observation in March 1936, 40 years after treatment was begun.

COMMENT: In analyzing this case it is important to note that the injections of both the filtered and unfiltered preparations given for rather brief periods, combined with repeated operations, did not permanently arrest the disease. It was not until 1897, when the toxins were administered steadily, with brief intervals of rest, for a considerable period of time, that a permanent result was obtained. The toxins were not begun until three operations had been performed and much scar tissue was present in the tumor area. This is known to inhibit the effectiveness of subsequent toxin therapy.

REFERENCES: 17, Case VI; 19; 21, Case V; 25, Case V; 51, Case 32; 58, Case 3; 59, Case 3 in text; 68, Case 1; 128

CASE 7: Very large recurrent inoperable fibrosarcoma of the gluteal region and thigh, confirmed by microscopic examination at Roosevelt Hospital, New York.

PREVIOUS HISTORY: Mrs. M.S., female, aged 29, of Hartford, Connecticut. The family and early personal history were not recorded. Onset, in 1886 pain developed in the upper left thigh where the patient had been lying for some time while in bed following her third confinement. Three months later she noticed a growth the size of her hand a little above and posterior to the greater trochanter. There was a constant ache in the leg. The growth gradually increased in size for four years. In October 1891 it had attained a diameter of 15 by 20 cm.

SURGERY: It was then removed by Dr. Charles McBurney at Roosevelt Hospital in New York. The wound healed in six weeks.

CLINICAL COURSE: Three months later a recurrence developed further up in the gluteal region. This increased in size and caused a great deal of pain. The case

SERIES A, INOPERABLE SUCCESSES, DETAILED HISTORIES

was regarded as hopeless by McBurney. The patient was then referred to Dr. W. B. Coley. Physical examination at the time the toxins were begun showed a very large tumor occupying the left gluteal region, involving the muscles and fascia of the upper thigh, posteriorly. The tumor was so extensive that any attempt to remove it by further operation was out of the question. Pain was very severe. (For a photograph of the condition at this time see 16.)

TOXIN THERAPY (*Type IV*): Injections were begun by Coley at New York Postgraduate Hospital on April 7, 1894. They were made locally and the dose was gradually increased to the point of producing a marked reaction. The pain ceased but improvement was very slow. On June 30, 1894 at the end of nearly three months' treatment the patient left the hospital. While there had been considerable decrease in size, there still remained a large tumor. This continued to decrease in size without further treatment.

CLINICAL COURSE: Examination by Coley five years later showed two small, hard movable masses at the site of the original tumor. On April 29, 1899, Coley operated at Memorial Hospital. The fibrous remains were separated from the surrounding tissue down to their connection with the bone, and this was cut through. Microscopic examination of the tissue showed it to be fibrous stroma, all the malignant cellular elements having been absorbed. The patient remained in very good health and was examined periodically by Coley. She was presented before the Clinical Congress of Surgeons of North America in November 1912, and before the American College of Surgeons in 1932. Her family physician, Dr. Philip G. McClellan, reported on October 10, 1939: "She is now 77 years old and at the site of the original lesions in the buttock there is nothing but a very pliable scarring. Her only symptoms are of a cardiac nature." She died on February 2, 1941, of coronary heart disease, at the age of 77. This was 51 years after onset and 47 years after toxin therapy.

COMMENT: The toxins caused regression of the malignant elements of the growth, but there remained a residue of hard fibrous tissue. This has been observed in a few other cases of fibrosarcoma, especially where one or more operations had been performed prior to toxin therapy.

REFERENCES: 10; 16; 40; 51, Case 65; 67; 128

CASE 8: Inoperable intra-abdominal spindle cell sarcoma, involving the cecum, omentum and mesentery, confirmed by microscopic examination following exploratory laparotomy. The tumor fragments were examined by Dr. F. J. Thornberry, who reported: 'Macroscopically, the specimens comprise principally

SERIES A, INOPERABLE SUCCESSES, DETAILED HISTORIES

irregular and quite firm pieces of tumor varying in size, some of which have shredded margins. Microscopically are seen masses of round and elongated cells, within places, accumulation of brownish pigment granules. The appearance may be due to transverse division of elongated cells. In portions of the growth no cellular elements are discernible, the specimen having a coarse fibrous appearance. Blood vessels throughout the tumor are quite numerous. Necrotic changes have taken place in some parts. From the histological character of this growth, I would consider it sarcomatous."

PREVIOUS HISTORY: C.P., female, aged 12. The family history is not recorded. The patient had been a strong and healthy child until March, 1894, when she had a fall, sustaining a bruise in the left inguinal region. This produced marked swelling at the site of the trauma, accompanied by pain, causing much distress. The swelling did not subside but increased gradually, and the general health became affected with loss of appetite and strength until finally the child was confined to bed. The abdomen continued to increase in size, the child became feverish, and increasing dyspnea supervened as well as edema of the legs. Her condition became critical. A physician was consulted about June 20, 1894. He found the abdomen enormously distended, diagnosed ascites, but on puncturing the abdomen got a dry tap. After this puncture the swelling increased more rapidly, and with the dyspnea, so that the child could not lie down. Urine passed involuntarily, the temperature was 102°F., the pulse 130, small and weak. Dr. Herman Mynter was consulted on July 20, 1894, and asked whether an operation would give the child a chance for recovery. He found a well developed girl, extremely pale and so short of breath that for several weeks she had not been able to lie down in bed. On examination the heart and lungs were normal, the dyspnea being apparently due to the enormously distended abdomen. The latter was evenly rounded and distended, with dull percussion in the lower parts. An indistinct fluctuation was felt by tapping over the whole abdomen. The lower part offered more resistance, and an indistinct mass could be felt in both inguinal regions, and in front, extending upward almost to the level of the umbilicus. On account of the fever, the rapid increase in size, with indistinct fluctuation and increasing marasmus, Mynter thought the condition might be a suppurating dermoid cyst, although the case had many of the characteristics of malignancy. Although the prognosis seemed hopeless, he advised that the child be removed to the Sisters' Hospital in Buffalo, for exploratory laparotomy in order to clear up the diagnosis and, if possible, save her life.

EXPLORATION: On July 22, 1894, under chloroform anesthesia, an exploratory

SERIES A, INOPERABLE SUCCESSES, DETAILED HISTORIES

laparotomy was performed by Mynter in the presence of a large number of well-known surgeons and physicians. On exploration, two quarts of thick, odorless, chocolate-colored fluid escaped, and a soft vascular growth was found involving the parietal peritoneum, the mesentery, the pelvic organs and the cecum. It was partly loosened from the right inguinal region, and a piece as large as a fist removed. The bleeding was so alarming and the patient's condition so unfavorable that further surgery was out of the question. The abdomen was therefore hurriedly irrigated with sterile water, the bleeding checked by tamponade with many yards of iodoform gauze, and the wound closed. The pulseless and livid child was removed to the ward in a dying condition. By active stimulation she was revived, but the prognosis was regarded as hopeless by all who saw her. The specimen removed at operation had a soft homogeneous appearance, looking very much like white brain tissue. During the next three days the patient improved somewhat. This was considered as probably due to the diminished dyspnea following relief of the tension. On July 26 the wound was dressed and the gauze packing removed. This was followed by profuse discharge of the same kind of fluid found at operation. A large glass drainage tube was then inserted, through which several ounces of fluid was pumped out every few hours.

TOXIN THERAPY (*Buxton IV*): On July 26, 1894, Mynter began the injections. They were given daily into the upper end of the thigh, as it was considered impossible to make them directly into the deep-seated tumor. Mynter reported: "During the next week quite an astonishing event occurred. While there was still a profuse discharge of the fluid mentioned, necessitating pumping out every two or three hours, there commenced to be discharged through the drainage tube large masses of necrotic tumor tissue the size of good-sized oysters. It became necessary to remove the drainage tube frequently in order to pick out these necrotic masses, which would completely fill up and choke the tube." By August 7 it was noted that about an ounce of the fluid was removed every three hours, and that this now had more the character of pus, and with this fluid large masses of necrotic tumor tissue continued to be evacuated. Mynter reported at this time: "The patient is remarkably improved, the tumor appears to be receding, the appetite is good, and the abdomen very much smaller." He reported a week later: "The abdominal cavity was irrigated daily with peroxide of hydrogen and large quantities of degenerated tissue continued to come away. The patient is greatly improved, the tumor seems to be rapidly melting away. Her appetite is good, pulse and temperature normal." By August 23 the discharge was diminishing and less necrotic tissue was being evacuated. There was still some swelling deep in the pelvis, particularly on the right side. The patient continued to improve steadily. By September the discharge had almost disappeared.

CLINICAL COURSE: On September 17, 1894, the child was allowed to go home and she was in excellent condition. Mynter stated: "She was the picture of health, with

SERIES A, INOPERABLE SUCCESSES, DETAILED HISTORIES

red lips, plump and healthy-looking." A small fistula remained into which a rubber drainage tube was still inserted, leading to a cavity containing perhaps half an ounce. No swelling could be felt in the pelvis, but there was still some infiltration about the anterior abdominal wall, where the drainage tube was inserted. There was only a slight discharge and the abdomen was reduced to its normal size. The drainage tube was removed by October 4, 1896, at which time the fistula was superficially granulating. The patient remained in good health and free from recurrence when last traced in June 1898, over four years after onset. Attempts to trace this patient or to find a record of her death failed in 1952-1953.

REFERENCES: 7; 50; 58; 135; 137; 141

CASE 9: Large inoperable three times recurrent fibro-angioma of the upper lip, confirmed by microscopic examination.

PREVIOUS HISTORY: J.T., male, aged 32, farmer, born in Germany. The family history was absolutely non-contributory. Since birth the patient had had a thick upper lip, but it did not increase in size very much until he was 21. For the next ten years it grew slowly, but beginning in 1891 it increased very rapidly in size.

SURGERY: An operation was performed by Dr. Andrews in Chicago in 1892. The growth recurred and a second operation was performed by Dr. French. Physical examination in early November 1895 showed a tumor the size of a very large orange involving the entire upper lip, measuring about 23 cm. from one corner of the mouth to the other. The tumor pulsated synchronously with the heart beats, and was the same temperature as the rest of the body. It projected over the lower lip to the level of the chin. The third operation was performed by Dr. Robert T. Morris of New York. The tumor was transfixed with a long narrow scalpel, the handle being used as a hare-lip pin, and a figure of eight gauze bandage thrown around it; the greater part of the tumor was then excised.

CLINICAL COURSE: Two weeks after this operation the whole base of the upper lip was occupied by a tumor 2 cm. thick on the right side, extending upward nearly 5 cm. This being the third recurrence, the condition was considered inoperable.

TOXIN THERAPY (Buxton's Type V Filtrate): The injections were begun about November 19, 1895, and were made into the dense tissue of the tumor about 2 cm. from the lower border. The growth immediately began to decrease in size and at the end of three weeks had almost disappeared. Morris then performed a plastic operation to restore the lip.

CLINICAL COURSE: The patient remained well and free from further recurrence when last traced in December 1903, eight years after treatment.

SERIES A, INOPERABLE SUCCESSES, DETAILED HISTORIES

REFERENCES: 25, Case XVII; 25, Case 21 in Table; 67; 134

CASE 10: Twice recurrent small round cell sarcoma of the lip, confirmed by microscopic examination by Dr. Bertram H. Buxton; a section was reviewed at Dr. W. B. Coley's suggestion in 1934 and again pronounced round cell sarcoma.

PREVIOUS HISTORY: M.S., female, aged 5, of Tacoma, Washington. The family history was negative for malignancy at that time, but about 20 years later a cousin developed a sarcoma of the leg which proved fatal. The patient had always been well except for the usual childhood diseases. Onset, in July 1896, while spending the summer at the seashore, the child was hit in the face with the back of a hairbrush by a playmate. The mother noticed a small lump on the child's chin, which at first resembled a mosquito bite. It was 4 cm. below the mucous membrane of the lower lip.

SURGERY: This lump grew to the size of a pea, when it was removed by Dr. J. R. Yocum of Tacoma, Washington, in September 1896. It recurred almost immediately, and another operation was performed on December 29, 1896, a large v-shaped incision being made. Considerable normal tissue was removed on either side. In January 1897 there was again evidence of a local recurrence. The patient's father, a physician, then brought the child to Coley in New York. At this time there was a tumor at the site of the old cicatrix, extending from the mucous membrane of the lip downwards about 4 cm. It appeared to be increasing rapidly in size.

TOXIN THERAPY (*Buxton V, Mixed Filtrate*): Injections were begun on February 10, 1897, and were made into the tissues of the lip near the tumor, in doses of 2 to 7 minims. These produced a slight reaction, and only once was there a chill. The tumor tissue very soon lost its vascularity and it began to shrink, losing its glossy, tense appearance. After four weeks' treatment there was apparently very little tumor tissue remaining.

FURTHER SURGERY: In order to decrease the chances of recurrence by removing any possible sarcomatous tissue that might be present, Coley decided to excise the entire scar tissue. This was done by making the usual v-shaped incision adopted for epithelioma of the lip, cutting about $\frac{1}{2}$ cm. beyond the cicatrix. The specimen was carefully examined by Buxton and no sarcomatous elements could be found in any of the tissue. After the patient returned home the injections were continued by Yocum, at first in the chin and later in the arm (all intramuscular) and were given for about a year.

CLINICAL COURSE: There was never any further recurrence. The patient married

SERIES A, INOPERABLE SUCCESSES, DETAILED HISTORIES

and had two children, one of whom died just before birth, the other being strong and healthy. The patient herself remained exceptionally healthy. Although she was vaccinated several times for smallpox, these never "took" and she contracted a very severe case of smallpox in 1926 at the age of 30. Her menstrual history was very regular and normal, including menopause. Her health remained excellent. In April 1956 her blood pressure was found to be quite labile, but at times it was as high as 210/90. On November 5, 1958 she was awakened with a crushing sub-sternal pain which was diagnosed as a myocardial infarction. She remained in the hospital for several weeks. There was a moderate degree of arterial hypertension. Raudixin and Diuril were used. Since the myocardial infarction the blood pressure remained about 160/75 usually. She was maintained on anticoagulant therapy with Coumadin. Chest films taken in August 1960 showed nothing remarkable. She remained in excellent health thereafter. Her son developed a brain tumor in 1970 which caused his death in 1971. The patient remained in excellent health, driving her car up to 100 miles daily in 1975, at the age of 83, 78 years after onset. *Note:* this is the only case treated by toxin therapy to have a child develop cancer. One other child of a man who was successfully treated for a sarcoma of the tibia developed Hodgkin's disease.

REFERENCES: 10; 21; 40; 51, Case 61; 65

CASE 11: Inoperable spindle cell sarcoma of the scapular region, with extensive involvement of the chest wall, confirmed by microscopic examination by Dr. Harlow T. Brooks, pathologist at the New York Postgraduate Hospital.

PREVIOUS HISTORY: S.C., female Jewess, aged 16, of New York City. There was no family history of malignant disease. The patient's history was negative for tuberculosis, inflammatory or specific disease. She was born in England and had always been in good health. From before the age of 10 she had always had to work very hard, carrying water, scrubbing and other manual labor. At 13 she attended school for three years. She then worked as a nursemaid. Menses were normal. Onset in March 1894, four months prior to admission, she began to have pain in the left arm, shoulder and scapula. She then noticed a small tumor in her back over the left scapula. This rapidly increased in size, gradually extending both in front and behind, until it had involved the larger portion of the left thoracic wall. It was associated with constantly increasing pain and interfered with motion of the arm. The patient was admitted to Memorial Hospital on June 23, 1894, under the care of Dr. W. B. Coley. Examination at this time revealed a hard fixed mass involving almost the entire region of the left thorax behind, extending from the clavicle to the lowest rib, the vertical measurement being 32 cm. Horizontally it extended from the median line behind to the middle of the sternum in front, and

SERIES A, INOPERABLE SUCCESSES, DETAILED HISTORIES

from 2 cm. below the clavicle, 18 cm. downward, involving a large portion of the region of the left breast. It was flat, being only about 5 cm. thick over the most protuberant portion. The entire tumor was fixed to the scapula and to the ribs, apparently originating in the soft parts over the scapula. The skin over the growth was normal in appearance and not adherent. The growth was not painful on palpation. The left arm could not be raised to a horizontal position, being bound down by the new growth. Movements forward and back were correspondingly limited. Breathing was much diminished on the left side, both anteriorly and posteriorly.

SURGERY: A biopsy was performed and the specimen was carefully examined by Brooks, who reported: "typical spindle cell sarcoma". Because of the rapidity of the growth and the enormous extent, Coley did not believe even temporary arrest possible; nevertheless he decided to try the injections for two or three weeks.

TOXIN THERAPY (Buxton VI): Injections were begun by Coley at Memorial Hospital on June 23, 1894, and were all made into the tumor over the lower part of the scapula or within a radius of 2 cm. of its periphery. They were given daily or every other day and produced fairly marked febrile reactions, usually accompanied by a chill. However, the reactions were never severe enough to keep the patient in bed more than a few hours after injection. At times there was much pain in the growth. To Coley's astonishment, improvement was immediate and very rapid. Within three weeks the arm could be raised to a vertical position, and within one month the growth in front had nearly disappeared. The improvement continued without any interruption until the latter part of October 1894, 3½ months from onset of treatment, when no trace of tumor could be found in front or behind. *The growth regressed entirely by absorption, without any breaking down or sloughing.* Coley presented the patient before the New York Academy of Medicine on November 15, 1894, at which time there was not the slightest trace of the growth or any induration whatsoever. She had regained her normal health and strength. As a precaution against recurrence, injections were continued with intervals of rest until April 12, 1895, almost 10 months, when the patient was discharged as cured.

CLINICAL COURSE: She was examined from time to time by Coley and his associates. In 1900, six years after toxin therapy, she developed myositis ossificans in the pectoral region on the opposite side. She remained in good health and free from recurrence when last traced in December 1913, 19½ years after onset.

COMMENT: In reporting this case in 1895, Coley stated: "This case is to my mind the most brilliant of the entire series . . . (up to 1895). Here we have a tumor, the great malignancy of which was shown by the rapidity of its growth and the extensive involvement that had occurred within four months, and the diagnosis

SERIES A, INOPERABLE SUCCESSES, DETAILED HISTORIES

of spindle cell sarcoma established by the microscopic examination of a skilled pathologist, entirely disappearing within 3½ months from the beginning of the treatment with the mixed toxins."

REFERENCES: 17; 19; 20; 35; 51; 128; 139

CASE 12: Recurrent inoperable fibrosarcoma of the calf of the leg, confirmed by microscopic examination following operation.

PREVIOUS HISTORY: Mrs. D.P., female, aged 40, of Chicago, Illinois. The family and previous personal history was essentially negative. The patient was the mother of nine children. She was admitted to St. Luke's Hospital, Chicago, on March 28, 1894, for a small tumor on the lower third of the inner aspect of the right leg, which is said to have been first noted in 1891.

SURGERY: On March 30, 1894 this growth was removed by Dr. L. L. McArthur. Operation revealed a tumor springing from the muscles of the calf. Although a very radical operation was performed, the patient was warned of a probable recurrence and advised to have an immediate amputation if evidence of recurrence were noted. Dr. John E. Owens stated: "The patient came under my care in April, 1894. The healing of the operative wound was very slow and unsatisfactory. On May 20 skin grafts were used. The open sore finally healed and the patient was discharged."

CLINICAL COURSE: A week after leaving the hospital the leg grew sore and gradually became worse. The patient was readmitted on September 25, 1894, under McArthur's care. At this time there was an ulcer about 8 cm. in diameter at the site of the operation. The edges were ragged, infiltrated and very painful at times. The leg was somewhat swollen, but the swelling for the most part disappeared when the patient lay down. There existed a recurrent tumor the size of a walnut which appeared to be closely attached to the bone or periosteum (very limited motion). As the patient was 3½ months pregnant, McArthur decided it would be wiser not to attempt amputation, but to try Coley's toxins.

TOXIN THERAPY (Buxton VI): Injections were begun on September 28, 1894, the initial dose being 7 minims. The first lot of toxins was used during the first 38 days, during which time 33 injections were given in doses of 7 to 11 minims (mostly 7 or 8). No marked or even moderate febrile reaction occurred from these doses, only a mild one after the third injection on September 30 (.6° rise, vomiting and then a chill). On October 6, after nine injections, "some improvement" was noted, and on October 12, "progressive improvement" was noted. The appetite was variable. On October 12 the patient had pain on urination, and passed 23 ounces. Occasionally the injections would cause some nausea or vomiting.

SERIES A, INOPERABLE SUCCESSES, DETAILED HISTORIES

NEW PREPARATION OF TOXINS: A new lot of toxins was used beginning November 5, and the initial dose of 2 minims given at 8 P.M. caused a febrile reaction of 101.8°F. and a chill, but the patient felt comfortable and slept after 12 o'clock. During the next three weeks 18 injections of these toxins were given, in doses of 2 to 5 minims. They did not produce any real febrile reactions after the first dose, only slight elevations of less than a degree on two occasions. This patient received a total of about 17 cc. of the first lot of toxins during the first five weeks, and about 3½ cc. of the second batch.

Owens and McArthur, who both published this case, do not state the site used for the injections. It is believed that they were all made intramuscularly, rather than into the tumor, as the majority of cases given intratumoral injections in doses of 5 to 10 minims usually had marked febrile reactions.

In describing the results when presenting the case before the Chicago Medical Society on December 17, 1894, Owens stated: "When we began this treatment we had a well-marked tumor, about the size of a walnut, movable in a very slight degree, so it seemed to be closely associated with the periosteum. This has disappeared, and the open wound has healed without any other treatment than a protective covering." McArthur added: "This was undoubtedly to my mind a growth from the sheath of the tibial muscles of the calf of the leg. On removing it I made a crucial incision, enlarging the wound widely because I found the main growth starting from that sheath. At the time of operation I made a diagnosis from the clinical appearance as well as the microscopic appearance of a fibrosarcoma, and predicted its return, no matter how radical an operation was done, and I told the patient that although I had removed it as radically as possible without taking off the leg, I expected she would have to have that done within six months, on account of recurrence. She returned with a very distinct observable growth in the cicatrix, and with the idea of having the leg removed, but in the meantime much more favorable reports having been made in regard to the toxins, this treatment was tried, with the results you see. Instead of a scar standing out 2 cm. above the surrounding surface, it is now hollowed out to compensate for the loss of muscular tissue beneath the sheath."

CLINICAL COURSE: There were no unfavorable effects upon the pregnancy. The patient returned to the maternity ward at full term. There was no further recurrence of the growth. The patient was reported well and free from disease in November 1912, over 18 years after onset.

REFERENCES: 25; 169

CASE 13: Recurrent inoperable spindle cell sarcoma of the parotid confirmed by microscopic examinations.

SERIES A, INOPERABLE SUCCESSES, DETAILED HISTORIES

PREVIOUS HISTORY: Female, aged 39. The family and previous personal history were not recorded.

SURGERY: Dr. Horace Packard, of Boston, Massachusetts, removed the primary growth by operation.

CLINICAL COURSE: Recurrence took place within a year and appeared inoperable.

TOXIN THERAPY (*Buxton VI*): Injections were begun by Packard in August 1895, and were continued for several months, being made daily into the growth and in the surrounding tissues. The tumor shrank away materially and "seemed to become an inert non-offending node". Further injections failed to dissipate it entirely.

FURTHER SURGERY: Consequently the remaining portions of the growth were dissected out, followed by excellent healing.

CLINICAL COURSE: The patient remained in excellent condition with no sign of further recurrence when last traced 3½ years after onset.

NOTE: Packard successfully treated at least two other cases in 1895-1896, using Buxton's unfiltered preparation (Type VI). He later used the less potent commercial product (Parke Davis IX) and wrote Coley in November 1907, after the latter had told him that Dr. Martha Tracy was preparing the toxins and had produced what appeared to be a most potent preparation, saying: "I am very glad to know that I shall be able to get toxin from a more reliable source. I had practically given up using it because what I received from the commercial laboratory seemed totally without action."

REFERENCES: 40, Case 13 in Table of other men's cases; 67; 51, Case 13, p. 152

CASE 14: Inoperable spindle cell sarcoma of the iliac fossa, involving the ilium, confirmed by microscopic examination by Dr. William F. Whitney, Pathologist at Massachusetts General Hospital, Boston.

PREVIOUS HISTORY: M.D., female, aged 40, of Boston, Massachusetts. The family history was negative for malignancy. Eleven years prior to admission the patient was struck with a raft while bathing. Seven years after this injury she began to have frequent attacks of pain which were believed to be sciatica. Onset in the spring of 1895, a year prior to admission to Memorial Hospital, a tumor the size of a hickory nut was first noticed on the pubis. This growth steadily increased in size.

SERIES A, INOPERABLE SUCCESSES, DETAILED HISTORIES

EXPLORATION: An exploratory laparotomy was performed on October 19, 1895, by Johnston of Boston, who reported: "A tumor was found in the right iliac fossa about the size of a coconut, attached to the ilium as well as to the abdominal wall, and totally inoperable. Its exact point of origin could not be made out, but from the exploration and subsequent examination I am convinced that it started from the inner portion of the crest of the ilium."

TOXIN THERAPY (*Buxton VI*): Injections were begun by Dr. Farrar Cobb of Boston on November 1, 1895, 13 days after the operation. At the end of six weeks' treatment the growth had entirely disappeared.

CLINICAL COURSE: During the next few months a recurrence developed, and the patient was referred to Dr. W. B. Coley. Examination on admission to Memorial Hospital on June 1, 1896 showed a median cicatrix 15 cm. long. Another cicatrix about 8 cm. long was situated about 5 cm. to the right. A mass was found filling up the right lower quadrant of the abdomen, extending from the symphysis pubis to within 5 cm. of the costal cartilages. The tumor was fixed to the ilium, the upper part being in the abdominal wall. There was pain in the tumor. The general condition was good. The patient was obese, weighing 211 pounds.

SECOND COURSE OF TOXIN THERAPY: Injections were begun by Coley on June 2, 1896, and in the next 67 days 22 were given. The patient was discharged on August 7, for a six weeks' period of rest. Her general condition was fair and there was very slight diminution in the size of the growth.

CLINICAL COURSE: She was readmitted to Memorial Hospital in November 1896. Examination showed the tumor had increased considerably in size during the interval in which the toxins had been suspended.

FURTHER TOXIN THERAPY: On resuming the injections the tumor at once began to shrink. Whenever the injections were made the patient noticed a peculiar burning sensation in the tumor, and this was true regardless of whether the toxins were injected into the abdominal wall or the thigh. The abdominal wall was so thick with fat that few injections were made into the tumor itself. Coley stated that this patient was one of the very few he had seen in which the toxins produced a very severe irritation of the skin. After each injection a hard, indurated and very painful area about 3 cm. in diameter would appear, and this would not subside entirely for several days. When the patient was discharged from the hospital in June 1897, the tumor had again regressed markedly. It disappeared completely a few months later.

CLINICAL COURSE: Coley examined this patient repeatedly during the next 12 years and reported her to be in excellent health the entire time, with no trace of tumor to be felt. The last examination was made in 1907.

SERIES A, INOPERABLE SUCCESSES, DETAILED HISTORIES

NOTE: The majority of cases treated successfully in the early years by Coley and other physicians appear to have received injections into the tumor or its immediate periphery, occasionally alternating with injections given intramuscularly remote from the tumor. These cases regressed much more rapidly than those in which subcutaneous or intramuscular injections alone were used remote from the growth. The above case appears to be the first one in Coley's personal experience in which it was necessary to use the latter technique, due to the obesity of the patient and the inaccessibility of the tumor. It is now apparent that subcutaneous and intramuscular injections may produce painful indurations. Cases thus treated respond slowly, so that a longer duration of treatment is necessary in order to produce complete regression. During this time the patient or the neoplasm may become immune to the effects of the toxins, so that control of the disease may be lost. These points do not appear to have been recognized during Coley's lifetime except by a few physicians.

REFERENCES: 10; 38, Case 11; 40, Case XI; 46, Case X; 65; 128

CASE 15: Inoperable rapidly growing spindle cell sarcoma of the pectoral region and breast, confirmed by microscopic examination of material removed at biopsy by Drs. B.H. Buxton, E.K. Dunham of New York, and William H. Welch of Johns Hopkins Hospital, Baltimore.

PREVIOUS HISTORY: Miss E.E.F., female, aged 42, of New Britain, Connecticut. The patient's paternal grandmother had died of carcinoma of the breast, but the family history was negative for tuberculosis or specific disease. The patient's previous health had been good. Onset, in October 1895, she first noticed a hard lump below the left clavicle in the pectoral and axillary region. This grew rapidly and in two months had reached the size of an orange. It was firmly adherent to the deep vessels and extended well into the axilla. Her general health deteriorated and she lost 24 pounds in weight. She consulted Dr. M. Storrs of Hartford, early in December 1895. A consultation was held with McKnight, attending surgeon at the Hartford Hospital, and both surgeons regarded the condition as entirely inoperable. The patient was rapidly losing strength and weight. It was decided to try toxin therapy under Dr. W. B. Coley's direction.

TOXIN THERAPY (*Buxton VI*): Injections were begun by Storrs and Dr. R. H. Griswold on December 16, 1895, the day following the patient's admission to the Hartford Hospital. The initial dose was one drop, which was gradually increased to a maximum of 8 minims. The first chill occurred after the fourth injection, on December 29. Injections were given every two days until February 8, during which time 39 were administered, 18 of which produced distinct chills. The dose

SERIES A, INOPERABLE SUCCESSES, DETAILED HISTORIES

was 8 minims on February 8. The following day a more potent solution prepared from more virulent cultures was obtained, and the dose was reduced from 8 minims to one minim. In spite of reducing the dose of this injection, it produced the most violent chill. This more potent preparation was continued and caused chills in doses of 1 to 3 minims during the next five weeks, injections being given daily in this period. The patient reported: "Chills came on 30 to 90 minutes after treatment, lasting 30 to 45 minutes. When the new stronger toxins were used (February 9) I had the worse chill of all; with that toxin the chill would come on sometimes half an hour after the treatment. The days I had a chill I had less pain and felt better after the chill than the days when I had none . . ." (This patient did not take her temperature regularly, and the few times she did take it, half an hour after the injection, it was usually about 100°F., so that the maximum febrile reactions in this case are not known.) The patient remained in the hospital only a short time; thereafter the injections were made at home or in the doctor's office.

The tumor began to shrink shortly after the injections were begun. It was incised nine times during the course of the treatment, in order to facilitate the drainage of necrotic tumor tissue. The discharge increased after the more potent toxin was used. All the incisions were thoroughly irrigated, every time an injection was made, for nearly three months. (This was a painful process, and it is doubtful whether such a procedure should be employed in treating future cases.) During the treatment the patient's appetite was not very good, but she ate in order to maintain a little strength. A total of 76 injections was given in three months.

CLINICAL COURSE: By the latter part of March 1896, a little over three months after the toxins were begun, the growth had entirely disappeared and the patient had gained rapidly in weight and strength, so that she soon regained the 25 pounds she had lost prior to toxin therapy. Coley presented her before the New York Surgical Society on November 11, 1896, and also before the Clinical Congress of Surgeons of North America in November, 1912. She remained in good health, married, and when last traced by Coley shortly before his own death she was well except for pain in her knee joints. On October 10, 1939 (at the age of 86) she was seen by Dr. Philip G. McLellan of Hartford, who stated that examination of the pectoral region showed nothing but the scarring of the biopsy and the sinuses. Shortly thereafter she developed a small basal cell epithelioma at the left side of her nose. She died on May 2, 1943, at the age of 89, of bronchopneumonia and decompensated arteriosclerotic heart disease. This was 48 years after onset.

REFERENCES: 7; 10; 23; 25; 32; 40; 46; 51; 67; 139

CASE 16: Inoperable twice recurrent spindle cell sarcoma of the thigh, with extensive involvement of the

SERIES A, INOPERABLE SUCCESSES, DETAILED HISTORIES

inguinal lymph nodes, "confirmed by microscopic examination by skilled pathologists."

PREVIOUS HISTORY: Mrs. J.R.C., female, aged 47. The family history was noncontributory. The early personal history and date of onset were not recorded. The patient developed a tumor on the outer aspect of the upper third of the thigh.

SURGERY: Two operations were performed, the primary tumor and the first recurrence being removed surgically. The growth recurred a second time. Examination by Dr. C.M. Nicholson, Professor of Anatomy in the Beaumont Hospital Medical College, St. Louis, Missouri, in January 1896, showed extensive involvement of the inguinal lymph nodes, and the entire limb was edematous.

TOXIN THERAPY (Buxton VI): Injections were begun in January 1896 and were given every other day, causing febrile reactions of 101.5° to 103°F. They were continued until March 26, 1896, about 2½ months, by which time the tumor had entirely disappeared, the swelling and edema had subsided, and the evidence of inguinal involvement had also entirely disappeared.

CLINICAL COURSE: Nicholson reported this case in July 1899 as a successful result. It has been impossible to obtain the end-result.

COMMENT: In reporting this and two other cases he had successfully treated with the toxins, Nicholson stated: "During the last two years medical literature has contained comparatively little relative to erysipelas and prodigious toxins as a therapeutic measure in sarcoma, owing in part to the lack of success in the hands of a well-known surgeon who, in 1896, reported at a meeting of the American Medical Association the result of its use in nine cases (three of which were carcinoma), expressing the opinion that the method is valueless. (This was Dr. Nicholas Senn.) I have, however, had several cases where the diagnosis was confirmed by skilled pathologists and where operation was impracticable, owing to the extent of the growth, in which I have used these toxins with seemingly good results." (His only failure was a *terminal* case of sarcoma of the uterus; the patient died 17 days after treatment was begun.)

REFERENCE: 155

CASE 17: Recurrent inoperable spindle cell sarcoma of the uterus, confirmed by microscopic examination.

PREVIOUS HISTORY: Mrs. E. Z., aged 37, of Rochester, New York, born in Canada. The patient had been married nine years and was childless. Menstruation began at 16 and was regular and normal in amount. The patient had had dysmenorrhea

SERIES A, INOPERABLE SUCCESSES, DETAILED HISTORIES

for eight years prior to onset. She was first seen by Dr. H. T. Williams on April 16, 1891. At this time her health was fair but she had noticed a growth in the abdomen six years before, which had gradually increased in size. A diagnosis of uterine fibroid was made.

SURGERY: On May 31, 1891 a median abdominal incision was made. A large, smooth fibroid of the uterus was found, the sound passing 23 cm. There were numerous adhesions, in view of which it was considered best not to do a hysterectomy but to try the effects of sterilization. Both tubes and ovaries, which were large and cystic, were removed as close to the uterus as possible. Catgut was used to ligate the pedicles. The post-operative course was uneventful.

CLINICAL COURSE: The patient was again examined on November 21, 1891. Bleeding had been much less profuse. The uterine sound passed 13 cm. By May 1892 the sound passed 11 cm. The patient had been gaining weight. She was then lost sight of until March 1896, when she again came to Williams complaining of pain in the right side and saying she felt another tumor. Examination showed a large, hard tumor about the size of two fists in the right side of the abdomen, and upon vaginal examination it appeared to spring from the right horn of the uterus. The tumor was not very movable and seemed attached to the abdominal muscles.

EXPLORATION: On March 24, 1896, an exploratory incision through the abdomen revealed a large, elastic tumor, apparently originating from the right pedicle, extending into the abdominal muscles, and adherent to the intestines. It was considered inoperable. A portion was removed for microscopic examination and the abdominal wall was closed with eight silver wire sutures. The wound healed by first intention. The tumor increased rapidly in size, and a month after the exploratory incision it projected several centimeters above the surface of the abdomen.

TOXIN THERAPY (*Buxton VI, Unfiltered*): Injections were begun by Williams on April 24, 1896, the initial dose being 3 minims injected into the center of the tumor. The reaction was very great, the patient had a severe chill, went into collapse, and brandy and strychnia, with saline per rectum and hypodermically were required before she rallied, which she did a few hours later. The temperature had risen to 106°F., but after a few hours had dropped to 100°F., and the next day was normal, but the patient felt much exhausted. Four days after the first injection, one minim was injected into the tumor about 2 cm. below the point of first injection. The symptoms of April 24 were repeated, but were less severe. The temperature only rose to 103°F. The patient declared that "she would rather die than submit to any more injections." However, she was finally persuaded to have another one of 1 minim on May 1. The reaction was less severe, the temperature

SERIES A, INOPERABLE SUCCESSES, DETAILED HISTORIES

reaching 102°F. On May 5, 3 minims were injected, causing temperature of 103°F. and a slight chill. On May 8 and 14, 3 minims were given and were followed by considerable reaction but not much temperature. On May 18, 4 minims were injected, causing a very severe prolonged chill and a temperature of 105.4°F. The patient felt extremely weak for some days afterwards. After each of the previous injections a slight erysipelatous blush had appeared around the point of injection, which disappeared in a few days. This time an area of 8 to 10 cm. in circumference of bright red color appeared. Poultices were applied and in a few days it turned black in the center and a slough about 4 cm. in diameter came away, leaving a hole 5 to 8 cm. in depth in the center of the tumor. The patient positively refused to have any more injections. This opening discharged for several months and the tumor grew rapidly smaller. Six months after the last injection it was the size of a hen's egg. In another two months it had entirely disappeared, and the patient had gained considerably in weight and felt fine.

CLINICAL COURSE: There was no further recurrence. The patient remained in good health when last traced on March 5, 1914, 18 years after toxin therapy.

COMMENT: This case indicates the effects and dangers of too large an initial intratumoral dose. Three minims into the tumor was about ten times more than Coley advised. The severity of the reaction almost caused her to refuse further treatment. Note that a permanent result was obtained, although only seven injections of the toxins were given. However, all were made into the tumor and the preparation used was a potent one, especially so at that period (1894-1897).

REFERENCES: 40, Case VI in other surgeons' series; 51, p. 151; 67

CASE 18: Inoperable round cell endothelial sarcoma of the pelvis, confirmed by microscopic examination, following exploratory operation.

PREVIOUS HISTORY: E.P., female, aged 15. No details are recorded other than that an exploratory operation was performed by Dr. Horace Packard, of Boston, Massachusetts.

TOXIN THERAPY (Buxton VI): The patient was then given injections of the toxins for a few weeks, resulting in the entire disappearance of the growth.

CLINICAL COURSE: There was no recurrence when the patient was last traced in December 1905, approximately 10 years after onset.

REFERENCES: 51, Case 14, p. 152, table of other surgeons cases; 67

SERIES A, INOPERABLE SUCCESSES, DETAILED HISTORIES

CASE 19: Recurrent inoperable intra-abdominal spindle cell sarcoma, confirmed by microscopic examination.

PREVIOUS HISTORY: Female, aged 55. No details were given.

SURGERY: The patient had previously been operated upon for an abdominal tumor and was suffering from a recurrence. Dr. Horace Packard, of Boston, Massachusetts, performed an exploratory operation. He opened the abdomen and at once encountered a large mass of atypical tissues which broke down readily to the touch but was inseparably adherent to the abdominal viscera. Fragmentary masses were removed, but the futility of attempting a complete removal was at once recognized. The wound was closed with drainage. The case was regarded as hopeless. Without much hope of benefit, she was given the Coley toxins.

TOXIN THERAPY (Buxton VI): Injections were begun in May 1896, and Packard reported: "She quickly began to show improvement, both locally and in general." The growth regressed entirely and she made a complete recovery.

CLINICAL COURSE: The patient was last traced in 1906, ten years after treatment, at which time she was earning her living as a nurse. She stated that her only reminder of her former trouble was a ventral hernia. There had never been any further recurrence.

REFERENCES: 40, Case 14 in Table; 44, p. 182; 51, p. 152; 67; 170

CASE 20: Inoperable endothelial sarcoma of the ovary, with many secondary nodes in the adjacent viscera, confirmed by microscopic examination following exploratory laparotomy by Dr. Horace Packard of Boston.

PREVIOUS HISTORY: Female, aged 18, of Springfield, Massachusetts. The patient was referred to Packard by Dr. O. W. Roberts of Springfield, for treatment of an abdominal tumor. Examination revealed an indistinct irregular mass palpable in the left side on vaginal examination. The abdominal enlargement was apparently caused by accumulation of ascitic fluid.

EXPLORATION: Abdominal section disclosed a small nodular tumor, apparently originating in the left ovary, with many secondary nodes scattered about, upon, or beneath the peritoneum of the adjacent viscera.

TOXIN THERAPY (Buxton VI): The patient was sent home immediately after recov-

SERIES A, INOPERABLE SUCCESSES, DETAILED HISTORIES

ering from the effects of the exploratory laparotomy, and Roberts then began the toxin injections, giving them subcutaneously into the abdominal wall. The first effect was a reaction in the wound, which had healed by first intension: the phenomenon of local tissue reactivity first noted by Gregory Schwartzman about 30 years later. It assumed a livid color, which subsided, however, when injections were suspended. After a few days the toxins were resumed and continued faithfully for several weeks, with ultimate full recovery. The growths regressed completely.

CLINICAL COURSE: The patient resumed her school work, completed her training and taught for several years, then married. There was no recurrence when she was last traced in 1908, over 12 years after onset.

REFERENCES: 31, Case 12 in Table of other surgeons' cases; 38; 44; 51, p. 152, Case 46; 170

CASE 21: Recurrent inoperable intra-abdominal spindle cell sarcoma, confirmed by microscopic examination by Dr. B. H. Buxton.

PREVIOUS HISTORY: Female, aged 43. The family and previous personal history were non-contributory. Onset, in the latter part of 1895 the patient noticed a hard swelling in the lower part of the abdomen. This steadily increased in size.

SURGERY: In July 1896 Dr. W. B. Coley removed a tumor the size of a child's head situated behind and to the right side of the uterus, and apparently retroperitoneal in origin.

CLINICAL COURSE: Four months later a recurrent tumor of considerable size was found at the site of the primary growth. This grew rapidly and appeared to be inoperable.

TOXIN THERAPY (Buxton VI): Injections were begun in November 1896 by Dr. Frank N. Zabriskie of Greenfield, Massachusetts, and were continued three times a week for about three months. The tumor decreased markedly in size. Apparently it then remained stationary for when the patient was again seen by Coley in July 1897, a hard tumor the size of a goose egg was found in the region of the left broad ligament. Coley advised an attempt at surgical removal, but the patient refused. Accordingly, the toxins were resumed and were given two or three times a week in moderate doses (not enough to produce a chill), and with occasional intervals of rest. Total duration of toxin therapy was about a year.

CLINICAL COURSE: In June 1898, Coley again examined the patient and could find

SERIES A, INOPERABLE SUCCESSES, DETAILED HISTORIES

only the merest trace of the former tumor. The general health was perfect. The patient remained well and free from further recurrence when last traced 12 years after treatment.

REFERENCES: 25, Case 21; 51, p. 155, Cass 35

CASE 22: Inoperable thrice recurrent mixed round and spindle cell sarcoma of the parotid, confirmed by microscopic examination by Dr. Farquhar Ferguson, pathologist at The New York Hospital, and Drs. B. H. Buxton and E. K. Dunham at Memorial Hospital, New York.

PREVIOUS HISTORY: Mrs. B., female, aged 34. The family and previous personal history were not recorded.

SURGERY: The tumor had been removed three times by Dr. William T. Bull and further operation was deemed inadvisable. The patient was then referred to Dr W. B. Coley for toxins in January 1897. At this time the recurrent tumor was the size of a small egg, infiltrating the entire parotid gland on the right side. The cervical lymph nodes were not enlarged.

TOXIN THERAPY (Buxton VI): Injections were begun late in January 1897, and were continued for four months. They were given only two or three times a week in very small doses, as the patient was an extremely nervous woman. The tumor became much reduced in size and freely movable.

FURTHER SURGERY: Most of the mass was then easily removed under ether anesthesia. (It would have been impossible to remove all of it without sacrificing the facial nerve.) This tissue was examined microscopically and showed no traces of sarcoma, being apparently the fibrous stroma of the former growth. The toxins were then continued after this operation for another three months, in very small doses, not sufficient to produce a chill; total duration of toxin therapy was seven months.

CLINICAL COURSE: The patient was last reported well and free from further recurrence in January 1907, ten years after treatment. Coley was unable to trace her subsequently.

COMMENT: Coley stated in 1897 that he had never seen a case of sarcoma of the neck cured by operation, nor had he been able to find an authentic case reported by other surgeons. In 1901 Coley reported his end-results to date and stated: "It is worthy of note that two of the 15 successful cases (then well about 4 years) are

sarcoma of the parotid gland." (51) He quoted Butlin as stating, in his second edition of *On Operative Surgery of Malignant Disease*: "Up to the present time there are very few instances of cure by operation of undoubtedly malignant disease of the parotid. In both of Coley's cases treated by the toxins, the diagnosis was not only confirmed by a competent pathologist, but further by a history of repeated recurrence after operation." (51)

REFERENCES: 32, Case 16; 33; 40, Case 20 in Table; 51, Case 60, p. 96

CASE 23: Recurrent inoperable spindle cell sarcoma of the neck, recurrent in the thoracic wall, confirmed by microscopic examination by Dr. Kodis, pathologist at Washington University Medical School, St. Louis, Missouri. The metastatic tumors were examined by Dr. Carl Fish.

PREVIOUS HISTORY: Mrs. B., female, aged 50. The patient was the mother of a large family. She first consulted Dr. Joseph Grindon, of St. Louis, Missouri, in April 1897, a few days after onset. A firm, rounded painless mass about 2 cm. in diameter was found, immediately above the left clavicle, just behind the sternomastoid insertion. There was no history or evidence of lues or tuberculosis.

SURGERY: At operation the growth was found to extend into the thoracic cavity, behind the first and second ribs, and possibly much deeper, so that complete extirpation, if at all possible, would have involved disarticulation of the clavicle and ligation of the subclavian vessels. As much of the mass as could be reached without disturbing the clavicle was excised, and the wound closed.

CLINICAL COURSE: The incision promptly healed, but a few days later the skin thinned and assumed a bluish look, and in a few more days it broke down. The mass rapidly regained its former size, soon exceeded it, and continued to grow. The patient began to lose weight and developed anemia, and finally she became so weak that she was bedridden.

TOXIN THERAPY (Buxton VI): Injections were begun by Grindon in mid-April 1897. At first they were given every third day directly into the tumor, but owing to an excessive reaction, resulting perhaps from the needle entering a vein, they were later made intramuscularly in the back. The initial dose was half a minim, which was gradually increased to 10 minims. She received a total of 58 injections in six months. The local and general reactions were severe almost from the first, consisting of a wide zone of erysipelas-like inflammation, spreading from the site of injection, with constitutional disturbance coming on after about two hours. These consisted of a chill, followed by fever, vomiting, headache and, on one or

SERIES A, INOPERABLE SUCCESSES, DETAILED HISTORIES

two occasions, mild delirium. The patient soon began to gain in weight and strength and general appearance. Meanwhile the tumor rapidly subsided and in four months all evidence of the growth had entirely disappeared. By September the patient was apparently completely well. She received no other treatment than the toxins.

CLINICAL COURSE: In January 1898 Dr. Paul V. Tupper was called to see the patient and found that she had two growths in the upper portion of the neck, one in the breast and one in the axilla. He stated: "The masses in the neck contained pus, which was liberated."

SECOND COURSE OF TOXIN THERAPY (*Buxton VI*): Injections were resumed, but only four were given in February and two in March, without visible effect. In April several masses 2 to 3 cm. in diameter were removed and submitted for microscopical examination. Another 22 injections in gradually increasing doses were given during May, June and July. Tupper stated that during treatment "suppuration occurred in all the masses and they entirely sloughed away. The sinus running beneath the sternomastoid discharged for over a year, but presented no evidence of suspicious induration."

CLINICAL COURSE: Tupper stated that "the breast and axilla healed nicely, that the integument was drawn into the axilla, as if the contents had been removed by dissection". The patient remained free from recurrence. She died of other causes eight years later.

NOTE: It is apparent that even though injections were continued six months, recurrence took place only four months after they were stopped, indicating the need for continuing the toxins for a longer period in such far-advanced cases, in order to prevent the possibility of recurrence. Apparently a longer period may be needed in patients who have had one or more operations, or radiation.

It is of interest to note that Grindon wrote Coley on June 28, 1915, asking for some of Tracy's Type XI toxin. He added: "Years ago I obtained a success in spindle-celled rapidly growing sarcoma with your toxins (the above case) made at the Loomis Laboratory—Buxton's. Later in another case I used the Parke Davis product. The reactions were far milder, which made me doubt the value of the product." Grindon wrote to H. C. Nauts in July 1944: "I have not again used the Coley product due to the low potency of the Parke Davis preparation." It is now apparent that a great many other physicians had similar experiences, but did not realize that the weakness lay in the preparations, as well as the technique of administration used, and not in the fundamental principles of toxin therapy.

REFERENCES: 10, 55, Case 1, in *Other Surgeons' Cases*; 67; 194

SERIES A, INOPERABLE SUCCESSES, DETAILED HISTORIES

CASE 24: Twice recurrent inoperable spindle cell sarcoma of the parotid, confirmed by microscopic examination by Dr. Ellis, pathologist at the Bridgeport Hospital, Bridgeport, Connecticut.

PREVIOUS HISTORY: W.L., male, aged 40, a carpenter, of Bridgeport. The patient's maternal aunt died of a malignant tumor of the breast which developed following an injury. In September 1896 the patient received a slight blow in the left parotid region. Onset, a swelling was first noticed in this area early in 1897 and it grew rather rapidly.

SURGERY: In March 1897 this tumor was removed surgically by Dr. J. W. Wright of Bridgeport. It quickly recurred and two more operations were performed in April by Wright at the Bridgeport Hospital. At the third operation the growth was found to be too extensive for complete removal, as the submaxillary lymph nodes on the left side had become involved. The tumor grew very rapidly after this operation.

TOXIN THERAPY (*Buxton VI*): Injections were begun by Wright at the Bridgeport Hospital early in July 1897, and were continued for three weeks with but little improvement except some softening and sloughing in the central ulcerated portion of the growth. (The site, dosage and frequency of injections given by Wright are not recorded.) The patient was first seen by Dr. W. B. Coley on August 10, 1897. At this time there was a tumor 10 cm. in diameter occupying the entire left parotid region, extending from the angle of the jaw to the orbit, and from the external auditory meatus almost to the angle of the mouth. The tumor was hard, markedly protuberant and firmly fixed to the deeper structures, with an ulcerated area in the center nearly 5 cm. in diameter. There was a mass the size of an English walnut in the submaxillary region. The case was absolutely beyond operation. Because the diagnosis was spindle cell sarcoma, and because Coley had noted that in 50 per cent of the cases of spindle cell sarcoma which were inoperable, the tumor had disappeared following toxins, he decided that it would be worthwhile to try further toxin therapy given aggressively.

TOXIN THERAPY UNDER COLEY: The patient was admitted to the New York Postgraduate Hospital on August 9, 1897, and as Coley did not believe the toxins had been "pushed to their full limit" he began by giving daily doses of from 5 to 8 minims. These usually produced a severe chill and a febrile reaction of 103° to 105°F. The temperature rapidly returned to normal and the patient was able to be up and about the ward, except for a short time after the chill. His appetite returned and he went outdoors for a walk nearly every day. After about two weeks of treatment there was a slight but unmistakable improvement noted. The tumor became more movable. It lost much of its vascularity, becoming more of a dull

SERIES A, INOPERABLE SUCCESSES, DETAILED HISTORIES

blue color; the central or ulcerated portion became necrotic with sloughing. The tumor in the submaxillary region was distinctly smaller in size. The improvement continued steadily but slowly. At the end of six weeks the mass was less than half the size it had been when the toxins were begun. The patient was then allowed to go home to attend to some family matters for 10 days; when he returned the condition was about the same. Injections were resumed and "pushed to the limit". In spite of this he lost no weight, but seemed to gain in strength and general appearance. The tumor slowly and steadily diminished, the central portion by sloughing, the periphery by absorption, without breaking down, and finally, by the middle of October, after three months' treatment, both tumors had entirely disappeared. The bright, granulating area remaining at the site of the ulceration soon healed.

CLINICAL COURSE: The patient was shown by Coley before the New York Surgical Society on March 23, 1898, in perfect health, with no trace of tumor remaining. He remained free from further recurrence until his sudden death on November 22, 1903, of severe hemorrhage from a gastric ulcer. This was over six years after the toxins were begun.

COMMENT: In the discussion which followed the report of this case at the New York Academy of Medicine on January 8, 1900, when Coley presented the patient for observation, Dr. John A. Wyeth asked: "What was the object of introducing the toxins directly into the substance of the tumor, and was it Dr. Coley's custom to do this?" *Coley replied that it was his practice whenever it was feasible, his experience having been that the results were far more satisfactory and more rapid when this could be done.* He had, however, had good results in several cases in which it had been necessary to make the injection at some distance from the growth. Wyeth asked if the temperature and inflammation had been exaggerated by this direct injection method. Coley said that he thought this was apt to be the case, especially if sloughing were present, but that pyogenic infection could be largely avoided by careful cleansing and disinfection before making the injections. Wyeth said that he had asked these questions because his own experience had led him to believe that much of the beneficial results following the injections of the toxins was due to an inflammatory process not directly connected with any special virtue of these toxins. This statement was not intended as any criticism of Coley's toxins, because he believed they were directly beneficial. He added that he considered it essential to secure infection with the erysipelas coccus, and "that he believed Coley's method was both scientific and successful". He cited his own two cases of sarcoma of the abdominal wall in which acute inflammation and suppuration occurred followed by complete regression. (201) (These cases have been abstracted among the data on the influence of concurrent infection, inflammation, fever and heat on malignant disease (142), and also in the series of intra-abdominal sarcoma and sarcoma of the abdominal wall as yet unpublished.)

SERIES A, INOPERABLE SUCCESSES, DETAILED HISTORIES

REFERENCES: 7; 24; 25; 26, Case 35; 32, Case 15; 35; 40, Case XIX; 51, Case 63, p. 98; 201

CASE 25: Intra-abdominal sarcoma, confirmed by microscopic examination.

PREVIOUS HISTORY: Adult (sex not given). The family and previous personal history were not recorded.

EXPLORATION: An exploratory laparotomy was performed by Dr. O. W. Roberts of Springfield, Massachusetts. The conditon was found to be inoperable.

TOXIN THERAPY (*Buxton VI*): Injections were given by Roberts, resulting in the entire disappearance of the growth. The details as to site, dosage, frequency and duration of treatment were not given. The tumor regressed completely.

CLINICAL COURSE: The patient was last traced in October 1905, well and free from recurrence over five years after onset and toxin therapy.

NOTE: Roberts had at least two other successful results in similar intra-abdominal tumors.

REFERENCES: 51, Case 47 in table of other surgeons' cases

CASE 26: Recurrent inoperable small round cell sarcoma of the parotid gland, confirmed by microscopic examination by Dr. M. P. Denton and Dr. B. H. Buxton, who stated: "a small round-celled sarcoma invading the interglandular connective tissue. The cells lie in large masses, and among them run numerous immature capillaries, and to a great extent they have degenerated, as indicated by the granular appearance of the nuclei and loss of staining properties. Remnants of glandular tissue can be observed here and there. The histological appearance of the tumor suggests extreme malignancy." Dr. William H. Welch also examined the sections and made a detailed report, stating in conclusion: "There can be no dispute about the diagnosis. It is not one of those sarcoma which simulate chronic inflammatory tissue, nor can it be hyperplastic or inflamed lymphatic gland adjacent to the parotid. The appearances all indicate a sarcoma originating in the parotid gland itself. Histologically, the

SERIES A, INOPERABLE SUCCESSES, DETAILED HISTORIES

new growth is malignant. Indeed, it seems highly malignant composed as it is of closely packed, small round cells."

PREVIOUS HISTORY: E. S., male, aged 55. The family history was non-contributory. Onset, the patient first noticed a lump in the right parotid region in November 1899. As it increased rapidly in size, he consulted Dr. J. D. Rushmore of Brooklyn who advised surgical removal. The tumor was the size of a walnut when the operation was performed by Dr. William T. Bull on April 5, 1900. It originated in one of the outer lobules of the parotid. The larger part of the growth was apparently encapsulated, but a portion was not, the latter containing a larger amount of fibrous tissue. It was impossible to remove the entire tumor without sacrificing the facial nerve, and this was not done.

CLINICAL COURSE: Recurrence developed promptly and increased steadily in size until October, when Bull decided that further operation was inadvisable, and referred the patient to Dr. W. B. Coley.

TOXIN THERAPY (Buxton VI): Injections were begun on October 5, 1900, and were continued daily for one month, being made into the tumor. The patient was never able to tolerate more than two to three minims. The reactions were moderate, the temperature ranging from 99° to 102°F. At the end of this time no very marked change had taken place and Bull felt inclined to doubt the advisability of continuing the treatment. There was, however, a slight diminution in size and increase in mobility, and the tumor seemed less fixed to the deeper structures. Injections were kept up five to six times a week during the entire winter. After three months' treatment, improvement was more marked, and in February 1901 the growth began to diminish more rapidly. By April 1st it was a quarter of its original size, and by June 1, 1901, it had apparently entirely disappeared. Only moderate reactions were aimed at, and only three or four times did the temperature rise above 103°F., and an average of about three slight chills a week occurred following injections. The patient remained in perfect health the entire time and was not confined to bed at all during the treatment. The greater part of the time he was treated at Coley's office, going at once to a hotel and two hours later taking the train home (a 30-mile trip). He gained in weight, strength and general health under treatment. Injections were continued until June 1901, a total duration of eight months. At that time the tumor had entirely disappeared.

CLINICAL COURSE: On November 27, 1901, Coley presented the patient before the New York Surgical Society, at which time there was no evidence of disease. He remained in good health until February 1907, when he had a severe attack of herpes, and the Gasserian ganglion became involved, resulting in death. There was no recurrence of the tumor at that time, more than seven years after onset.

SERIES A, INOPERABLE SUCCESSES, DETAILED HISTORIES

COMMENT: This case is important because it indicates the need for persevering with the injections even when there is no apparent improvement after four weeks' treatment. A study of other cases of sarcoma of the parotid indicates that daily injections alternating the systemic and intratumoral sites may produce a more rapid destruction of the neoplasm. It should be noted that the treatment was continued eight months in this case. This appears to be a decisive factor in preventing recurrence.

In reviewing the results obtained by toxin therapy in sarcoma of the parotid, it must be remembered that the prognosis in these cases is so bad that Butlin had doubted if a single case could be found in which permanent cure had been obtained. Coley, however, was able to state in 1902 that the above patient was the third case of inoperable recurrent sarcoma of the parotid gland that had yielded to toxin therapy under his care. Two of these cases were well four and five years respectively in 1902, and in all three the diagnosis was confirmed by microscopic examination.

REFERENCES: 34; 35; 40; 51, Case 56, p. 92

Case 27: Inoperable spindle cell sarcoma of the abdominal wall, involving the bladder, confirmed by microscopic examination by Dr. B. H. Buxton, Professor of Experimental Pathology, Cornell Medical College. The clinical diagnosis was also confirmed by Dr. F. W. Johnson of Boston.

PREVIOUS HISTORY: Mrs. H.L.G., female, aged 40, of Everett, Massachusetts. The family history was non-contributory. The patient had had measles and pertussis as a child. Menstruation began at 15 and was regular and moderate. In 1891, 15 years later, oophorectomy was performed for cystic ovaries. Nine years after this operation, in April 1900, an inflammatory condition of the bladder developed, accompanied by severe headache and bearing-down pains. The symptoms subsided on wearing a pessary and returned on removing the pessary. (This was two months prior to admission to Memorial Hospital.) There was gradual increase in pallor but no loss of weight. The patient was referred to Dr. W. B. Coley.

SURGERY: On December 19, 1900, he performed an exploratory operation. The tumor was found to be inoperable as it involved the entire thickness of the abdominal wall and some of the bladder wall. Several nodules were excised for microscopic examination.

TOXIN THERAPY (*Buxton VI*): Injections were begun five days after the operation, the initial dose being 0.5 minim, which was increased daily. The patient returned

SERIES A, INOPERABLE SUCCESSES, DETAILED HISTORIES

home on January 4, 1901, and the injections were continued for about three months by the family physician. The growth entirely disappeared.

CLINICAL COURSE: The patient remained free from recurrence. In 1923 or early 1924 she developed carcinoma of the liver, which caused her death at the age of 63, on October 17, 1924, 24 years after she had recovered from the sarcoma of the abdominal wall under toxin therapy.

REFERENCES: 7; 10; 46; 51, Case 73; 128

CASE 28: Extensive inoperable fibrosarcoma of the anterior abdominal wall and iliac fossa, confirmed by microscopic examination following exploratory operation.

PREVIOUS HISTORY: M.J.H., female, age 34, school teacher of Winchester, Mass. The patient's aunt had died of cancer of the uterus and her mother died 16 years previously of what was believed to be intra-abdominal cancer. One sister had a lipoma of the shoulder and an ovarian cyst. The lipoma was removed without recurrence. The patient had measles and pertussis as a child. Menses began at 13, and were regular and moderate in amount. She had always been comparatively healthy until 1894, when she had "nervous prostration". She did not entirely recover until 1896. There was no history of trauma or strain prior to onset.

SURGERY: In August 1898 she was operated upon by Dr. Booth for what was supposed to be a fibroadenoma of the uterus. A hysterectomy, double oophorectomy and salpingectomy was performed, but no microscopic examination was made of the specimen.

CLINICAL COURSE: The patient took two years to recover. In the summer of 1900 she felt pain in the lower abdomen but no evidence of tumor was apparent at this time. She first noticed a growth in the region of the cicatrix of the operation in the early winter of 1900-1901. The pain diminished as the tumor became larger. During the next few months the growth increased quite rapidly in size. She was then seen by Dr. Maurice H. Richardson, who pronounced it inoperable and referred the patient to Dr. W. B. Coley. She was admitted to Memorial Hospital on April 19, 1901. Physical examination on admission showed a hard non-tender tumor the size of a coconut (15 × 16 cm.) in the lower abdomen, filling up the entire right iliac fossa and extending beyond the median line on the left. The growth was firmly fixed and seemed to involve the abdominal wall.

EXPLORATORY: An exploratory incision about 4 cm. long was made under cocaine, and a portion of the growth which infiltrated all the muscles of the abdominal wall was removed. It was found to be a fibrosarcoma.

SERIES A, INOPERABLE SUCCESSES, DETAILED HISTORIES

TOXIN THERAPY (*Buxton VI*): Injections were begun by Coley on April 21, 1901. During the next 60 days about 20 were given in doses of 1 or 2 minims, at least 12 of which produced febrile reactions of 102°F. or more (5 over 103°F.), and one 105.6°F. A few of these were made into the tumor. During these first two months the growth decreased more than half, and became softer. The patient was discharged on June 27, 1901. Apparently the injections were continued more or less constantly until about September 10, 1901, almost five months. There was no further diminution in the size of the growth after the first two months, and for a long time thereafter there was no distinct increase in size.

CLINICAL COURSE: The patient was readmitted to Memorial Hospital on October 3, 1901, stating that since her discharge her general health had been very good. She added that the tumor had diminished in size, and became softer when she was taking the toxins, but that since discontinuing the injections she thought it had become harder and had increased in size. Physical examination, October 3, 1901, revealed that the hard, smooth tumor bulged considerably more than when the patient had left the hospital in June. Measurements were approximately the same as they were when the patient was first referred to Coley, 15 × 16 cm.

FURTHER TOXIN THERAPY: Injections were resumed on October 3, 1901, and were continued three to six times a week during the next 6½ weeks. They usually caused good febrile reactions (102°-104°F). At first there was marked diminution in the size of the growth, but later little effect was noted, and finally the tumor began to grow very rapidly. The patient lost much weight and became cachectic. Coley regarded the case as entirely hopeless at this time.

SURGERY: However, he decided to make a partial removal. This operation was performed on December 27, 1901 through a median incision 10 cm. below the umbilicus. The growth was found to be encapsulated. Much of the mass lying just below the skin was removed. The patient received one more toxin injection on January 23, which caused a marked reaction (105°F.). She was discharged on January 25, 1902. At this time the abdomen had the appearance of a seven-months' pregnancy, the patient was very weak, markedly cachectic and complained bitterly of pressure symptoms. Coley advised a trial with the x-rays.

RADIATION: X-ray treatments were administered by Dr. Clarence E. Skinner of New Haven, Conn., beginning January 28, 1902, and 46 were given in 18 weeks. By this time the lateral circumference of the tumor had increased from 35 to 37 cm. Coley saw her in May 1902 and believed the condition to be "out of control".

CONCURRENT FEVER: The patient then had several attacks of fever lasting a few days, with symptoms of toxemia, apparently due to absorption of necrotic tumor tissue, following which the general health improved considerably.

SERIES A, INOPERABLE SUCCESSES, DETAILED HISTORIES

FURTHER RADIATION: From June to September she received 31 more treatments and during this time there was so much local and general improvement that the patient decided to resume her work as a school teacher in September. X-ray treatments were continued about every five days until April 25, 1903, and for the next four months were given once in two weeks. From August 1903 to May 20, 1904 five more treatments were given, making a total duration of x-ray treatment of 849 days, during which 136 treatments were given.

CLINICAL COURSE: The tumor had entirely disappeared by May 1904, and the patient had gained 19 pounds, her weight being 147 pounds. Coley examined her in July 1904 and was unable to detect any evidence of tumor, but there was considerable skin damage from the radiation.

X-RAY CANCER: Dr. Charles A. Porter reported: "She remained perfectly well until August 1907, though she noticed that the skin of the hypogastric region was irregularly mottled and much thicker than normal, especially on the right side. Pain, from which she had been free, began to be severe and ulceration commenced. Severe and characteristic x-ray lesions developed, not only in the scar of the shrunken tumor but on the skin over the whole anterior abdomen. No treatment seemed of avail, the ulcerative process gradually spreading, undermining the skin, which subsequently necrosed. In addition to the ulcerations there were numerous papules of undoubted epidermoid cancer." The patient "lost weight and strength, becoming anemic and suffered severely from the pain." Porter first examined her on March 7, 1908 at which time there was an irregular triangular undermined ulcer in the hypogastric region about the size of the palm of one's hand, extending to the right side of the pubis, nearly to the iliac spine, the other angle approaching the umbilicus. The base was sloughing in parts, in others presenting poorly vascularized granulation tissue, in which necrosis was advancing rapidly. Several areas in the surrounding skin showed characteristic appearances of x-ray changes. The irregular ulceration with a firmly adherent fibrinous base was surrounded by a very bright scarlet red areola which bled at the slightest touch. Certain points in the ulceration were exquisitely painful on pressure. There was slight fever.

FURTHER SURGERY: After attempting to cleanse the wound with antiseptics for a few days, the whole ulcerated area was excised with a 2 cm. margin down to the aponeurosis of the abdominal muscles. The excision left apparently normal fat, except over an area 5 × 8 cm. to the right of the median line, where extremely firm scar tissue showed the site of the former growth. The skin at the periphery, however, was very tough and three times the normal thickness. The whole area was thoroughly disinfected with phenol, 95% alcohol and saline, and an attempt was made by tension sutures to diminish the gaping wound. It was dressed with protective tissue, gauze and swaths. The tissue was examined by Dr. S. B. Wol-

SERIES A, INOPERABLE SUCCESSES, DETAILED HISTORIES

bach, Director of Harvard Medical School Pathological Laboratory, who reported: "The atypical character of the epithelium, the presence of pearls and many mitoses and the relationship of epithelium to connective tissue in these growths warrant the diagnosis of epidermoid carcinomata." (For greater detail see 200)

POST-OPERATIVE FEVER AND INFECTION: The operation was followed by marked reaction, pain, temperature of 102°F., rapid pulse, exhaustion, and at the end of three or four days, continuous sloughing of the edges of the wound, involving the skin more than the fat. Porter stated that "operation was followed by marked infection which was questionably diphtheric". The general condition was poor. The wound was extremely sluggish and granulations formed very slowly, covered by unhealthy fibrin. (For photograph of the condition see 172, Figure 2.)

CLINICAL COURSE: After months of convalescence, granulation gradually was established and epidermization slowly took place from the pubic and inguinal regions, but the thickened skin ulcerated upward and laterally, with great pain and some fever. Six months after the first operation Porter again operated under ether, and removed the remaining thickened skin and upper half of the subcutaneous fat of the anterior abdominal wall for a distance of 10 cm. above the umbilicus, and laterally to the level of the anterior superior spines. The wound was dressed with protective dressings.

POST-OPERATIVE FEVER: The reaction was well marked but less severe than after the previous operation, and the temperature became normal in ten days.

CLINICAL COURSE: By December 5, 1908 the patient had gained in general strength and color and was walking about. The wound was granulating healthily at this time, and 14 Thiersch grafts were applied from the arm of a friend. These grew vigorously, but "after three or four weeks all of the grafts . . . were raised by blisters and slowly disappeared . . ." Further grafting was done from the patient's own thigh. Porter stated that there was copious discharge from the whole granulating surface. He added that he had "never seen anything like it", and considered that it might be "due to some peculiar condition, or possibly to the irritation of the green soap". By April 1, 1909 almost all the autogenous Thiersch grafts had taken and the huge wound was continuously covered with sound, thick, somewhat movable skin, except for an area 2 × 3 cm. in the right upper margin. There was no tenderness in the scar and no pain. The patient had been up and about for three weeks, having been hospitalized 13 months. Owing to continued flexion of the thighs there was some subluxation of both knee joints and she walked clumsily and somewhat in a stooping manner, owing to the contraction of the anterior muscles of the body. Her general condition was excellent. Porter published this case in 1909 and stated that it was "of extreme interest from many points of view." (172)

SERIES A, INOPERABLE SUCCESSES, DETAILED HISTORIES

The patient was seen periodically by Coley until 1923. She remained in very good health after her long hospitalization in 1908-1909. There was never any further recurrence of the sarcoma. The patient stated in 1947 that the skin-grafting done in 1908 "has held through the years. The surrounding area is not normal; several operations have been necessary, the last one in 1943. Usually if a small break occurs, it will heal in time." On August 28, 1948 she again reported: "My general condition the past year has been as good as anyone who has entered the 80's has a right to expect. This spring there was an attack of what seemed like neuritis, causing severe pain on the left side and shoulder. It yielded to daily exposures to direct sunlight, but did take some of the strength I had enjoyed before. The area of the x-ray burn still causes discomfort, at times breaking then healing. The scar tissue seems to be hardening somewhat." Her weight at this time was 130 pounds, her height being five feet four inches. In November 1949 she had a slight attack of coronary thrombosis, being hospitalized for a month and another month in a rest home. This somewhat limited her activity thereafter. The scar tissue continued to break and heal, but caused no special pain. She reported in October 1950: "A small growth near the right groin was removed about eight years ago by Dr. A. A. Palermo. He finds another slight recurrence at the same place. He feels that if my strength permits it should be removed." Palermo reported on November 28, 1952: "She is now 84 years old, still looks quite well and is up and around and able to do her usual light household duties. There are no enlarged superficial lymph nodes. The liver and spleen are not enlarged and there are no intraabdominal masses suggesting tumor. The skin of the abdomen shows the typical radiation reaction with several masses of recurrent disease . . . Most of these have been present for several years and are very slow growing and apparently do not bother the patient appreciably. The one in the right groin is the largest and the patient states has doubled in size in the past year. They bleed easily but she controls this by applying ordinary cotton which becomes adherent to the lesion and controls the oozing. Particular attention to the groins shows no evidence of lymphadenopathy." The areas of involvement were 1 to 3 cm. in diameter. In March 1954 the patient had a slight cerebral hemorrhage for which she was hospitalized a few days. The only residual effect was some loss of memory. When contacted on April 4, 1957 at the age of 90, the patient had had no recurrence of the sarcoma for which she had been treated 56 years previously, and she appeared to be in fair physical health, having had only an occasional cold in the preceding three years. During the last year of her life there was increasingly extensive ulceration of the anterior abdomen. Carcinomatous degeneration of the skin was surmised but never proven. Radical excision followed by skin grafting was considered but abandoned in view of her increasing debility. She died of bronchopneumonia on April 2, 1959, 58 years after onset.

Porter wrote to Coley in 1923 stating that he believed this case was one of the most remarkable results of combined x-ray and toxin therapy in the literature.

SERIES A, INOPERABLE SUCCESSES, DETAILED HISTORIES

REFERENCES: 10; 34; 36; 39; 67; 128; 172; 200

CASE 29: Recurrent mixed cell sarcoma of the neck, confirmed by microscopic examination by Professor F. N. Whittier of Bowdoin College, Brunswick, Maine, who reported that the cells seemed to be a mixture of large round and spindle.

PREVIOUS HISTORY: A.G.W., male adult. The patient first noticed an enlargement just behind the angle of the jaw in July 1900.

SURGERY: On February 21, 1901, a growth the size of a hen's egg was removed as thoroughly as possible by Dr. O.S.C. Davies, of Augusta, Maine.

CLINICAL COURSE: A recurrence quickly followed and two months after operation the growth was half as large as it had been at the time of the operation. It involved the anterior border of the sternocleidomastoid muscle and the deeper structures. Davies then wrote to Dr. W. B. Coley concerning the case. The latter advised toxins. The tumor was the size of half an egg when the toxins were begun.

TOXIN THERAPY (Buxton VI): Injections were begun by Davies about May 4, 1901, and were continued three times a week for about three weeks. They were then discontinued for a month, resumed and continued until August 14, 1901, at which time the tumor had entirely disappeared. (Total duration of treatment, a little over three months with a month's interval of rest.)

CLINICAL COURSE: The case was followed closely by Davies. There was no further recurrence, and the patient remained in good health when Davies wrote Coley in December 1905. He died in November 1912 of what was considered to be pulmonary tuberculosis. This was over 12 years after onset.

REFERENCES: 51, Case 42 in Table of other surgeons' cases; 55, Case 5 in Table of other surgeons' cases; 67

CASE 30: Inoperable round cell sarcoma of the thoracic cavity, beneath the sternum, confirmed by microscopic examination by Dr. E. J. Meyer, of Buffalo.

PREVIOUS HISTORY: Mrs. B., female adult. The details of the family and previous history are not recorded.

TOXIN THERAPY (Buxton VI): Injections were begun by Dr. Charles P. Chapin, of Buffalo, New York, under Dr. W. B. Coley's direction, in January 1902, the initial

SERIES A, INOPERABLE SUCCESSES, DETAILED HISTORIES

dose being 0.5 minim. They were continued every other day until the desired reaction was reached. In February the skin and subcutaneous tissue in the upper part of the tumor necrosed and a profuse discharge resulted. At the end of two weeks this area began to close and contract and then it healed over. During May the patient received 30 minims once a week. By May 15, Chapin was unable to detect any tumor beneath the sternum. He added that the toxins had produced no harmful effects upon the kidneys in spite of the fact that the patient had chronic Bright's disease.

CLINICAL COURSE: The patient was examined from time to time by Chapin. He wrote in November 1903 that she was in better health than at any time previous to treatment. She was last traced in October 1905, having had no recurrence of the disease. This was approximately four years after onset.

REFERENCES: 51, Case 52 in Table; 67

CASE 31: Spindle cell sarcoma of the triceps muscle in the deltoid region, confirmed by microscopic examination by Dr. J. Homer Wright, pathologist of the Massachusetts General Hospital, Boston.

PREVIOUS HISTORY: H.B.M., male, aged 56, of Lisbon, New Hampshire. The family history was non-contributory in 1903, but the patient's brother died of abdominal carcinoma on September 19, 1934. Onset, in the summer of 1902, a small tumor, which had existed for many years, began to grow rapidly.

SURGERY: In September 1902 it was excised by Dr. Brooks, together with some of the deltoid muscle.

CLINICAL COURSE: The patient was referred to Dr. W. B. Coley in February 1903. Examination at this time revealed a cicatrix 12 cm. long, on the upper and lower extremities of which could be felt a small mass, apparently a recurrence of the growth.

TOXIN THERAPY: Injections were begun by Coley on February 12, 1903. After the patient returned home they were continued by the family physician, Dr. Boynton, with apparent regression of the mass.

CLINICAL COURSE: The patient remained well and free from recurrence until his death on September 25, 1928, at the age of 81. The immediate cause of death was cerebral embolus, a contributory cause being "auricular fibrilatus." This occurred 26 years after onset.

SERIES A, INOPERABLE SUCCESSES, DETAILED HISTORIES

REFERENCES: 7; 51; 67; 120

CASE 32: Recurrent inoperable large spindle cell sarcoma of the cheek, confirmed by microscopic examination by Dr. E. K. Dunham.

PREVIOUS HISTORY: F.Q., male, aged 63, of San José, Costa Rica. The patient's father had died of "stomach trouble", the mother of "old age". The family history was negative for cancer. The patient had had a "fever" three years previously, but with this exception he had always been well. There was no history of antecedent local trauma. Onset, in January 1904, a hard swelling was first noticed on the right cheek.

SURGERY: This was removed a week later in San José, Costa Rica, but recurred almost immediately and the recurrent tumor grew rapidly. The patient was referred to Dr. W. B. Coley on March 2, 1904. At this time there was a hard mass in the central portion of the right cheek, 5 cm. in diameter and 1 cm. thick. Two days later Coley attempted to remove the growth, but found that this would have been impossible without sacrificing almost the entire cheek.

TOXIN THERAPY (*Buxton VI and Parke Davis IX*): Injections were begun by Coley at Memorial Hospital on the 12th post-operative day, and 13 were given during the next 25 days in doses of 1 or 2 minims, the first seven being the Buxton VI preparation, the other six the Parke Davis IX. They caused little febrile reaction.

RADIATION: The patient also received a few x-ray treatments during his stay at Memorial Hospital.

FURTHER TOXIN THERAPY: After his return home the toxin injections were continued by the family physician, the total duration of treatment being about three months, at the end of which time the remainder of the growth had regressed completely and the cheek had regained its normal appearance.

CLINICAL COURSE: Coley examined the patient in 1905 and again in 1910, over six years after onset. He remained well and free from recurrence.

REFERENCES: 51, p. 95; 128

CASE 33: Thrice recurrent inoperable round cell sarcoma of the scapular region, confirmed by microscopic examination by Dr. Harlow T. Brooks, Professor of Pathology at New York Postgraduate Medical School who reported that the growth was of high vascularity.

SERIES A, INOPERABLE SUCCESSES, DETAILED HISTORIES

PREVIOUS HISTORY: W. J., male, aged 10 (in 1904) of New Rochelle, N.Y. The family history was negative for malignancy. The patient's father died of Bright's disease at 67, his mother at 86 from a severe cold. In late August 1901, the child fell from the porch, striking his back. Two or three weeks later his mother noticed a swelling in the left scapular region at the point of the injury. This increased rapidly in size and was soft and fluctuating almost from the first. Four weeks later the child was referred to Dr. W. B. Coley. Examination at this time showed a cystic, markedly fluctuant swelling the size of an orange in the scapular region. A diagnosis of hematoma was made.

SURGERY: On January 12, 1902, Coley made an incision and evacuated several ounces of dark bluish fluid with a trochar. The wound was closed without drainage and healed by primary union. There was no evidence of solid tumor at this time. Onset, three weeks later a tumor began to develop at the original site. This was also cystic in character and increased rapidly in size until it was a third larger than it had been at the first operation. On May 2, 1902 a second operation was performed under ether, and in addition to blood clots a new growth was found which proved to be a round cell sarcoma, following microscopic examination. It was impossible, in view of the large area occupied by the tumor, to make a complete removal.

RADIATION: Two weeks after this operation, and before the wound had healed, x-ray treatments were begun and were given thrice weekly for four months. The remains of the growth apparently regressed completely.

CONCURRENT INFECTIONS: It is of interest to note that during the summer of 1902 the patient had chicken-pox, measles and scarlet fever. The fever and the toxins produced by these infectious diseases may have played a part in the regression of the growth during that period.

CLINICAL COURSE: Three weeks after the growth had disappeared it recurred. By December 1902 there was a well-marked recurrence in and about the cicatrix.

FURTHER RADIATION: This continued to increase in size in spite of further x-ray therapy.

CLINICAL COURSE: On January 26, 1903, Coley operated a third time under ether and removed the recurrent tumor together with the old cicatrix. The wound healed by primary union.

FURTHER RADIATION: Shortly after the child was discharged from the hospital, x-ray treatments were resumed and were continued once or twice a week during all of 1903 and the first half of 1904.

SERIES A, INOPERABLE SUCCESSES, DETAILED HISTORIES

CLINICAL COURSE: In June 1904 another recurrence developed in the cicatrix.

TOXIN THERAPY (*Buxton VI Combined with Further Radiation*): Injections were begun on July 1, 1904 and were continued until June 19, 1905, for almost a year. They were given in Coley's office two or three times weekly at first, later once a week, the site being in the vicinity of the scars. X-ray therapy was also continued for a time twice a week. Under this combined treatment the third recurrence slowly disappeared and the ulcerated area healed over.

CONCURRENT INFECTION: The child had whooping cough in the summer of 1904. This may or may not have helped to control the growth of the recurrent tumor.

CLINICAL COURSE: The patient was presented by Coley before the New York Surgical Society on January 11 and on May 10, 1905, at which times there were no traces of the former growths and the general health was perfect. There were no further recurrences. The patient was traced periodically by Coley. From 1911 to 1924 he became somewhat addicted to alcohol (8 to 16 ounces daily). He gave up drinking in 1924 and was married that year. A son was born about a year later.

RADIATION-INDUCED CANCER: About 1926 an ulceration appeared at the site of the former prolonged radiation, where there had always been a crust. In 1928 two x-ray cancers were excised and the area successfully skin-grafted by Dr. Lester Dragstadt of Chicago. One ulcer at the top of the irradiated area persisted and in 1936 the patient went to Memorial Hospital in New York, and consulted Dr. Bradley L. Coley. At this time the ulcer was the size of a dime. Coley advised surgical removal, but just then the patient went "on the road" (he was a magician) and he did not return to Memorial Hospital for ten years. During this period the lesion over the mesial border of the left scapula increased steadily in size, being 8 × 10 cm. in diameter in May 1946. A crust no longer formed, there being persistent foul-smelling ulceration and drainage. There was also a stabbing pain in the left shoulder which increased if the arm was raised. Examination on admission to Memorial Hospital revealed a slight, thin, 51-year old man. The skin had the general sensation of being keratotic, there being several keratotic papillomas, especially in the sacral region. There was benign hypertrophy of the prostate. The ulcerated area was 4 mm. deep, its base being covered with a gray slough. Over the rest of the back on both sides of the midline there were large healed split-thicknesses of skin grafts. Several areas lateral to these grafts showed small amber crusts overlying minute ulceration. Just medial to the acromioclavicular juncture there was an intracutaneous tender nodule 2 cm. in diameter, which was somewhat cystic. Following a biopsy this growth was reported to be a basal cell epithelioma by Dr. Sophie Spitz, pathologist at Memorial Hospital. On May 10, 1946 the growth was excised with a wide margin of skin (30 × 30 cm.) and skin grafted from the left thigh. Most of the grafts took. The patient was discharged on May

23, 1946. At examination four days later there was a slight, low grade infection. On June 17, 1946, there were some granulations which appeared to have been burned due to applications of silver nitrate. They were considered to be a recurrence. Apparently no further treatment was given.

In September 1947 "the scab came off", but the patient did not return to Memorial Hospital until January 10, 1949. He stated that two months previously the crusted area began to break down and that practically the whole graft which had been applied in 1946 had disappeared. Movement of the left shoulder had begun to be painful in early January 1949. Examination on readmission to Memorial Hospital revealed a deep wound over the supraspinatus extending down to muscle exposing the posterior margin of the trapezius and left supraspinatus muscle. The margins were overhanging the wound, and they were indurated and firm. There were several pearl-like nodules in the granulations over the muscle. There were no nodes palpable in the left axilla or supra-clavicular region. Provisional diagnosis: Recurrent carcinoma of the skin with extensive ulceration. A biopsy was performed on January 10, 1949 and reported to be negative. Dr. Gordan McNeer believed, however, that the patient should have a wide excision with partial scapulectomy and graft. This was done on February 24, 1949 with a large Padgett dermatone skin graft from the the right buttock. The report at this time was "local disease only" . . . "basal cell epithelioma, margins clear". The tumor extended deeply into the supraspinatus and levator scapulae muscles. The upper angle of the scapula was removed. The graft did fairly well and by March 14, 1949, was healing nicely. On August 9th there was still a small area of ulceration at the upper edge of the skin graft which was 1 cm. in diameter. A biopsy taken in October 1949 showed a definite recurrence in the upper outer angle of the wound, with pain and swelling of the upper arm. An interscapulo-thoracic amputation was advised, with resection of two or three ribs. The patient decided that he did not want any further surgical procedures, but wanted to have toxin therapy administered in the hope of controlling the disease by conservative treatment.

TOXIN THERAPY (*Parke Davis XIII*): During the next few months the patient had one or two courses of Coley's toxins given in the vicinity of the tumor by Dr. Alfred Pollak. These treatments eased the pain, and there was some slight evidence of improvement in the local condition.

CLINICAL COURSE: As the condition had not improved much and pain was constant, an interscapulo-thoracic amputation and neck dissection was performed by Dr. Bradley L. Coley in February 1950 at the Hospital for Special Surgery. In December 1950 an excision of the wound ulcer again revealed carcinoma. During a period of 15 months the patient lost weight rapidly, from 140 to 97 pounds. He had dyspnea and orthopnea for a year prior to his final admission, and during

SERIES A, INOPERABLE SUCCESSES, DETAILED HISTORIES

the latter part of this period he developed a cough. In June 1951 there was a gradual enlarging separation of the anterior portion of the old skin graft margin. On July 9, 1951 the ulcerated area was excised and the underlying second rib was curetted. The pathological diagnosis was "recurrent basal cell carcinoma with infiltration of bone, second rib". In November 1951, because of pain, the patient was placed on experimental analgesic therapy. The patient refused further therapy a week later. During November 1951 the ulceration in the left lateral cervical region continued to increase in size and depth.

FURTHER RADIATION: During December 1951 and January 1952 palliative x-ray therapy was given: 4,630 r. delivered to a simple direct port in a four or five week period. There seemed to be some improvement.

CLINICAL COURSE: On December 30, 1951 there was a temperature elevation for no clear cut reason, except possibly the massive pulmonary metastases. Death occurred on February 4, 1952, following acute respiratory distress and deep cyanosis. This was 50 years after onset of the sarcoma of the scapular region, which finally remained free from further recurrence after combined toxin and x-ray therapy in 1904. The provisional anatomic diagnosis at autopsy revealed recurrent carcinoma of the amputation cicatrix, extending to the left posterior neck, bilateral pulmonary metastases, spontaneous left pneumothorax, severe adhesions of the left lung (moderate, right lung), congenital anomaly heart (anomalous left circumflex artery), benign prostatic hypertrophy, edema, left foot, 2 plus. Microscopic examination by Dr. William Millett revealed that the patient "had a terminal bronchiolar carcinoma of the lungs producing a histologic appearance closely resembling basal cell carcinoma. This was thought clinically and initially pathologically, to represent metastasis from a basal cell carcinoma of the left shoulder of long standing." (Autopsy #41, Pathology #2-2023, James Ewing Hospital.)

REFERENCES: 10; 32; 36; 39; 40; 43; 48; 67; 128

COMMENT: This is one of the very few cases treated by Buxton's *serum* (Type VII) as this preparation was made for only a short time and appeared to be less effective than Buxton's unfiltered toxins (Type VI).

CASE 34: Inoperable thrice recurrent angiosarcoma of the left breast, confirmed by microscopic examination by Dr. T. M. Prudden, Professor of Pathology at the College of Physicians and Surgeons, New York. (For microphotographs see 19, Fig. 12, 13, 14, 15; for photographs of condition before and after toxin treatment see 25)

SERIES A, INOPERABLE SUCCESSES, DETAILED HISTORIES

PREVIOUS HISTORY: Mrs. A. C., female, aged 59. The family history was noncontributory. The previous health had been good, except for a tendency to constipation. The patient had two children. At the age of 42 she had received an injury to the left breast. Three months later a small lump appeared at the site of the blow. This grew slowly, was accompanied by some pain, and at the end of three years had reached the size of a fist.

SURGERY: The first operation was performed at St. Francis Hospital, Brooklyn, 14 years prior to toxin therapy. The breast was not removed. There were no enlarged nodes in the axilla.

CLINICAL COURSE: The patient remained free from recurrence seven years when the tumor recurred. It grew slowly for two years, reaching the size of an egg.

FURTHER SURGERY: A second excision was then performed at St. Francis Hospital by Dr. George F. Shrady of Brooklyn, N. Y., editor of the Medical Record.

CLINICAL COURSE: The patient remained free from further evidence of disease for two years when there was a recurrence "in situ". She was then referred to Dr. W. B. Coley as an inoperable case on January 20, 1895. Examination at this time showed a large tumor occupying the region of the left breast, extending from the anterior axillary line to the sternum, and from just below the clavicle to the free border of the ribs. The tumor was fairly well fixed to the chest wall, and was markedly protuberant, made up of more or less distinct nodules, the surfaces of which were purple. In places there was considerable ulceration with foul discharge. The condition was unquestionably inoperable. The general condition was so bad that no attempt was made at first to administer the toxins. After the ulcerated area had become somewhat less foul under careful treatment, and the general condition had improved slightly, the injections were begun.

TOXIN THERAPY (*Buxton VII and V*): The initial injection was given about February 1, 1895, using the Buxton serum (VII). Coley stated that "in small doses of 5 to 10 minims very little effect was noted". Larger doses, 15 to 20 minims, frequently caused intense muscular pain and an urticaria-like condition of the skin, sometimes extending over the whole back and chest, being the cause of intense itching and discomfort. The patient also complained of severe headache, sometimes lasting several days. The dose was never carried beyond 20 minims, but as a rule the injections were given daily. The maximum febrile reaction occurred on May 27, following a dose of 10 minims of the filtered mixed toxins (*Buxton V*). As a rule there was no elevation of temperature. The tumor began to decrease slowly in size and became much more movable. The general condition likewise improved. This preparation was administered between May 23 and 28 and again between September 4 and 8, 1895, and appeared to produce less marked effects

SERIES A, INOPERABLE SUCCESSES, DETAILED HISTORIES

than the serum. Treatment was continued with occasional intervals of rest until September 8, 1895. A total of 51 injections of serum were given and 7 injections of the filtered toxins in a period of 220 days.

FURTHER SURGERY: By September 8 the tumor had become so small that it could be easily removed by operation, and as it had not shown any further diminution in size in the previous month, it was deemed advisable to remove it, together with the remaining breast tissue. This was done, under ether, by Coley on September 18, 1895. The periosteum of the ribs was not involved, but as the skin over the tumor was diseased, an area 10×15 cm. was left to heal by granulation.

CLINICAL COURSE: The patient was discharged from the hospital in the latter part of December 1895, with no evidence of disease. She remained well until 1903, eight years later, when she fell downstairs, receiving injuries which proved fatal. She was examined at this time by one of Coley's associates, Dr. William A. Downes, who found no trace of recurrence of the sarcoma of the breast.

REFERENCES: 19, Case 8; 25, Case 8; 46; 51, Case 58; 128

CASE 35: Inoperable recurrent round and spindle cell sarcoma of the uterus, confirmed by microscopic examination by Dr. J. L. Hirsch.

PREVIOUS HISTORY: Mrs. A.C., aged 38. The patient had two children, the younger one having been born in 1893. Onset, in the fall of 1903, ten years after this pregnancy, she first "noticed trouble." She consulted her family physician who made a diagnosis of myoma. In December 1903 she was operated upon by Dr. J. M. Hundley, Professor of Gynecology at the University of Maryland. He supposed the condition to be an ovarian cystoma and uterine fibroid. The growth was the size of a fetal head.

SURGERY: A supra-vaginal hysterectomy was performed, leaving the cervix. Microscopic examination proved the condition to be a round and spindle cell sarcoma involving the entire uterus. On January 15, 1904, Hundley attempted to remove the cervix, but had to abandon the operation because of the patient's weak heart action. At this time he detected a recurrent tumor in the right lateral fornix, apparently springing from the broad ligament, the pelvic bone and the fascia. He stated that clinically the condition was undoubtedly sarcomatous in character.

TOXIN THERAPY (Parke Davis IX): Injections were begun by Hundley on January 22, 1904, a week after the second operation. They were given alternately into the fornix and cervix through the vagina. The tumors in both regions immediately began to diminish in size. A total of 33 injections were given. The recurrent growths disappeared completely.

SERIES A, INOPERABLE SUCCESSES, DETAILED HISTORIES

CLINICAL COURSE: On September 27, 1904, nine months after the injections were begun, Hundley wrote Coley that to all outward appearances the condition was normal. The patient moved to New York and Coley examined her at frequent intervals and found her in excellent health, her weight normal, and no trace whatever of the sarcoma. She remained in good health during the next 28 years. In July 1932 Coley was called to attend her for a very severe duodenal ulcer, which proved fatal. At this time there was no evidence of recurrence of the sarcoma for which she had been successfully treated by toxin therapy in 1904.

DISCUSSION: A complete regression and a permanent result was obtained in this case using the less potent commercial preparation of Coley's toxins. *It should be emphasized, however, that an effective technique was used, i.e., injections directly into the recurrent tumors.* Also, the disease was not as far-advanced as many of Coley's inoperable cases.

REFERENCES: 40, Case 41 in Table of other surgeons' cases; 51, p. 155; 67

CASE 36: Inoperable spindle cell sarcoma of undetermined origin, occupying the entire lower abdomen, infiltrating the peritoneum, involving the rectus muscles and firmly attached to the symphysis pubis. The diagnosis was confirmed by microscopic examination by Lt. Col. C. Birt, R.A.M.C. (For microphoto see 183)

PREVIOUS HISTORY: C.W.L., male, aged 33. The family and personal history was non-contributory. There was no history of venereal or malignant disease. The patient had always been a healthy man. He was a sergeant in the Royal Field Artillery, having been in the service 13 years. He had had enteric fever in India in 1895. The patient was admitted to the Hospital at Bulford on July 21, 1906, complaining of a hard, painful swelling in the lower abdomen, and frequent and somewhat painful micturition. He had been operated upon for right inguinal hernia in September 1905 and believed the tumor and "weakness of the bladder" had developed shortly after that operation. The patient was a thin, spare man with a rather anxious expression. The general health was good except for loss of weight. He slept well and had a good appetite. Examination revealed a large, very hard swelling in the lower part of the abdominal wall, reaching from pubes to within 4 cm. of the umbilicus, in the median line, and measuring about 8 cm. across. It was apparently firmly attached to the symphysis pubis and was slightly tender. The overlying skin was free. Micturition occurred every three or four hours with some pain at the end. The urine contained some albumin, but was otherwise normal. During the following three weeks the patient seemed to be getting thinner, but no increase in the tumor could be made out, though it became less tender. He was transferred to the Queen Alexandra Military Hospital

SERIES A, INOPERABLE SUCCESSES, DETAILED HISTORIES

at Millbank, England, on August 20, 1906. On admission the condition was as described above except that the urine was normal, the frequency of micturition less, and on rectal examination a hard mass could be felt in front of the prostate, evidently forming part of the tumor.

SURGERY: An exploratory laparotomy was performed by Major C. G. Spencer, R.A.M.C. on September 5, 1906, and revealed a growth involving the recti muscles firmly attached to the symphysis pubis and extending down in front of the bladder where it could be felt per rectum. Because consent to a dangerous operation had not been obtained, only a section was removed and the wound closed. Six days later an attempt at removal was made, but the peritoneum lower down was found to be widely involved and the operation was abandoned. The wound healed by a primary union. (183, p. 154)

TOXIN THERAPY (*Parke Davis IX, a fresh supply*): On September 22, 1906, 11 days after the second operation, an initial injection of 0.5 minim was made into the substance of the growth, and this dose was increased to 3 minims, which caused a sharp febrile reaction with headache and chills two hours later, lasting four hours. There was marked local pain and tenderness at the site of injections. The latter were given alternate days, and after 12 had been administered, treatment was discontinued as no appreciable effect had been produced on the size of the tumor and the patient's health was markedly affected. He had lost weight and suffered a good deal of local and general reaction after each dose.

CLINICAL COURSE: He left the hospital on October 13, 1906, with a very bad prognosis. He returned two months later, improved most strikingly in general health, having gained 15 pounds in weight and being able to take active walking and cycling exercise without inconvenience. The tumor was distinctly smaller and softer above the symphysis, though the hard mass felt per rectum was still present. The patient stated that "a fortnight after the injections were stopped he felt sore in the tumor, as if it were ulcerating", and he then noticed that it was getting smaller, softer and more movable.

SECOND COURSE OF TOXIN THERAPY: Injections were resumed on December 16, 1906, and continued until January 11, 1907, in doses of 1 to 6 minims. Treatment was suspended because the growth had become very tender, and the general health had deteriorated in the same manner as during the first series of injections. The tumor had also continued to regress.

CLINICAL COURSE: The patient was again sent out on furlough for a month and returned on February 20, his health again much improved and the growth further diminished in size. All bladder symptoms had disappeared.

SERIES A, INOPERABLE SUCCESSES, DETAILED HISTORIES

THIRD COURSE OF TOXIN THERAPY: A third series of injections was made consisting of 19 doses of from 1 to 3 minims, making a total of 46 injections in approximately six months.

CLINICAL COURSE: The patient was discharged on April 3, 1907. The tumor had diminished very greatly in front, above the pubes, but the mass felt by the rectum seemed unaffected, as the injections did not directly reach it. From time to time reports were received that the patient was in good health, but he was not again seen by Spencer until December 1908, at which time no trace of tumor could be found, either in the abdominal wall or by rectal examination. The operative scar was firm. The patient had returned to active army life and he stated that he had been in the best of health ever since leaving the hospital. He remained well and free from recurrence when last traced in 1912, six years after toxin therapy. (51, p. 138)

In the discussion which followed the presentation of this case, Spencer stated that he had also observed two cases of recurrent fibrosarcoma in which this method had been used apparently with success. One of the tonsil, which had recurred following each of three attempts at surgical removal, in which the man's life was beginning to be threatened from pressure on the trachea, was given toxin therapy by Peake, of Henley. Spencer states that "following Coley's directions (Peake) gave a full dose, producing a severe attack of toxemia lasting four days. In ten days the patient consented to have another dose, and the treatment so continued, temporarily arrested the pressure on the trachea so that the man desired to resume his occupation, but could not do so because the treatment could not be stopped. In this way the condition was kept stationary for about 12 months. (183) Spencer had not heard of the later progress of the this case so the end-result is unknown.

The second case, also a fibrosarcoma, had been under his care in the Westminster Hospital. The growth was in the sheath of the femoral artery (with tumor thrombus), and had recurred twice, and the only possible operation was amputation at the hip-joint. As an alternative he had been treated recently with repeated injections of Coley's fluid, which certainly prevented any increase in the size of the growth. There was still some persistent thickening around the femoral artery, but it was doubtful whether this was inflammatory or a true recurrence. In this case a rigor was only occasioned if an excessive dose was given, but a severe local reaction could be brought about which on one occasion threatened to cause suppuration, but the swelling subsided after the application of fomentations for a few days. Both the cases had been examined microscopically and reported to be fibrosarcoma.

In the course of the discussion following Spencer's paper, Pearce Gould

SERIES A, INOPERABLE SUCCESSES, DETAILED HISTORIES

stated that at the Middlesex Hospital in London they had not been very fortunate in their results in most of the cases in which Coley's injections had been used. Usually the tumors had been practically unaffected by the injections, and some of the patients had been very ill after the treatment. Most of the experience to which he referred was, however, obtained soon after Coley first introduced the method, and at that time it was almost impossible to obtain in London such well-prepared toxins as were now available, so that possibly this might partly explain the unsatisfactory results. He had certainly never seen a case in which such a favorable result had occurred as in the present one. (183)

COMMENT: Unfortunately, in addition to the fact that the preparations used in England prior to 1909 were weak and variable, few physicians realized the importance of using an aggressive technique of administration in order to produce favorable results, and most of the cases treated were very far advanced, often moribund. (67) As to the importance of aggressive treatment, Coley stated in 1906: "In every case there is a certain stage of equilibrium. There is a natural resisting power in some individuals, which may prevent the disease from advancing, and if we can by means of the toxins do anything else to increase this resisting power and turn the scales . . . we get success . . . many of the failures have been due to not giving enough of the toxins."

REFERENCES: 41; 51; 67; 139, Case 8; 183; 184

CASE 37: Inoperable small round cell sarcoma of the abdominal wall in the region of the umbilicus, apparently originating in the urachus, confirmed by microscopic examination following exploratory operation on December 28, 1906, by Dr. Mahlon D. Ogden, who reported: "Dense fibrous tissue, hyaline in parts, infiltrated with masses of small round cells. In some places are found hyaline fibres in bundles of varying size widely separated from their fellows by the above mentioned masses of cells. These cells are small and round with a barely perceptible rim of cytoplasm surrounding a deeply staining nucleus, and show quite a number of mitotic figures, some of which are atypical. It is not possible to make out any well-defined fibrils between the individual cells as they are closely approximated in most parts of the specimen, while in the thinner parts the intercellular substances seems to be of a homogenous nature. The blood vessels consist of a single tube of endothelium around which the round (tumor) cells are closely packed. Hemorrhages of vari-

SERIES A, INOPERABLE SUCCESSES, DETAILED HISTORIES

ous sizes occur in different parts of the specimen.”
(96) (The concurrent purulent cystitis may have produced these areas of hemorrhage.)

PREVIOUS HISTORY: J.P., male, aged about 20, of Hot Springs, Arkansas. The family and early personal history are not recorded. The patient, a young German, first consulted Dr. W. E. Green of Little Rock in March 1906, suffering from what had been diagnosed as a stone in the urethra. He was emaciated and nervous, showing the effects of a long period of suffering. Examination revealed a large, fixed calculus far back in the urethra, which the boy said his former physicians “had tried to extract by way of the meatus with urethral forceps”. Green immediately had the patient admitted to a hospital and operated the next day by the perineal route. A very large stone, fully 9 cm. long, weighing 1680 grains (3½ ounces) occupied the entire prostatic urethra, projecting both into the bladder and membranous urethra. It had to be comminuted and was removed with great difficulty. The boy recovered slowly, but never regained complete control of his bladder function. Onset, early in November 1906, eight months after this operation, the patient first noticed a tumor in the abdominal wall.

CONCURRENT INFECTION: However, he did not return to Green until December 25, 1906, about six weeks later, at which time he was suffering severely from vesical irritation. Examination showed a purulent cystitis, as well as a large tumor of the abdominal wall, fully as broad as a man’s hand, extending from the symphysis pubis to the umbilicus. The walls were much thickened and very hard. Green made a provisional diagnosis of “tumor of the abdominal wall, probably malignant, originating in the urachus”.

SURGERY: On December 28, 1906, Green performed an exploratory operation. The tumor was found to be confined to the abdominal wall to which the omentum was extensively adherent. A small piece of the growth near the umbilicus was excised for histological examination. As the case was wholly inoperable, toxins were procured.

TOXIN THERAPY (*Parke Davis IX*): Injections were begun by Green about January 1, 1907, the initial dose being 0.5 minim, which was gradually increased to 15 minims. A total of 60 injections were given in the next five months. Green stated: “They were usually made into the tumor, and were at first followed by the most violent reaction: within 30 to 60 minutes a severe chill would occur, followed by high fever and severe aching in the head, back and limbs, often accompanied by nausea and followed by profuse sweating. A bright red rash would appear over the abdomen with greatest intensity at the point of injection, as well as induration in the immediate vicinity of the injection site, which at times looked as if the tissues would break down.” Several times the injections had to be discontinued

SERIES A, INOPERABLE SUCCESSES, DETAILED HISTORIES

on account of the intensity of the local irritation. However, the general condition gradually improved. The patient gained weight and the pale yellowish complexion was in time replaced by a healthy ruddy hue. The toxins were continued until about June 1, 1907, at which time no trace of the tumor could be felt and the boy had gained 40 pounds (from 120 to 160 pounds), and appeared to be in perfect health.

CLINICAL COURSE: He was sent home to Hot Springs, Arkansas, and instructed to return at the first appearance of any recurrence. Green, in reporting the case, stated he regarded it as a most interesting and gratifying result. There was no recurrence. The patient remained in good health when last traced 5 years later.

COMMENT: Green produced at least two other permanent results following toxin therapy, both being inoperable sarcoma of the neck.

REFERENCES: 51, Case 110, p. 167; 67; 96

The following three cases received the Tracy X preparation of Coley toxins, which was produced by Dr. Martha Tracy between March 1906 and the latter part of 1907, under grants from the Huntington Cancer Research Fund. A streptococcus culture obtained from a fatal case of septicemia (not a case of erysipelas) was used. The two organisms were grown separately, heated to 75°C. for one hour (15° higher than Buxton VI)—and the amount of prodigiosus used, determined by Kjeldahl's method, was 5 mg. per cc. of the mixed toxin. After mixing and bottling the mixture was again sterilized at 75°C. for two hours. For the complete formula see (41).

Coley considered this preparation to be more potent and efficient than the Buxton VI, for he stated in March 1907: "During the last year the toxins have been prepared by Dr. Martha Tracy of the Huntington Cancer Research Fund, under Dr. Buxton's direction. Dr. Tracy has I think made an improvement over the older method of preparation, which consisted in growing the *Bacillus prodigiosus* in the same bouillon with the streptococcus of erysipelas. The growth of the prodigiosus has always been variable and it has been difficult to get a standard preparation. Dr. Tracy has during the past year, grown the prodigiosus separately sterilized with just sufficient heat to destroy the bacilli, reduced it to a dry powder and then added a certain definite amount by weight to each ounce of streptococcus broth. This preparation is much more stable and has proved more powerful in its action, requiring smaller doses, and the actual results in inoperable sarcoma thus far have shown a distinct improvement over those obtained with the older preparation." (42)

SERIES A, INOPERABLE SUCCESSES, DETAILED HISTORIES

During the period in which these toxins were used, Coley advised beginning with a very small dose, not over $\frac{1}{4}$ minim diluted with a little boiled water to insure accuracy of dosage. He stated: "If the tumor is highly vascular, it is wiser to begin the injections remote from the same, until the susceptibility of the patient has been ascertained. This varies considerably in certain individuals. After a few doses, it is safe, in most cases, to inject into the tumor itself. As a rule, when giving injections into the tumor, only about one-fifth of the dose used for injections remote from the tumor is required to produce the same reaction. The dose should be increased by $\frac{1}{4}$ minim when given into the tumor; by $\frac{1}{2}$ minim when injected remote from the tumor, until the desired reaction is obtained. The best results are obtained by doses sufficiently large to produce severe reactions, say a temperature of 102° to 105°F .

"The frequency of the injection must depend entirely upon the strength of the patient, some being able to bear daily injections, while in others it is unwise to push the treatment beyond three or four injections a week.

"In the successful cases the results are usually very promptly noticeable. The tumor becomes smaller in size, much more movable and very much less vascular. These changes appear very quickly, often within two or three days.

"The action of the toxins is both local and systemic. Sometimes the best results are obtained by giving the injection alternately into the tumor and remote from the same. In tumors in inaccessible regions, e.g., intra-abdominal sarcoma or sarcoma of the tonsil, a perfect cure may be obtained by entirely systemic injections."

It is evident that Coley realized that there were certain unreliable preparations being distributed as "Coley's Toxins", for on November 13, 1907, after describing in detail the formula used by Tracy for preparing the toxins at the Huntington Fund Research Laboratory, he stated:

"It is important that anyone using the toxins should know how they have been prepared, for the results vary greatly with their composition and manner of preparation. Many of the preparations put upon the market have been so weak as to produce hardly any reaction and have been found of little value. Parke Davis and Company have, I know, made great efforts to keep their product up to the standard of the Research Laboratory. Of other preparations I have no personal knowledge."

He added that it was also important to keep the toxins in a glass-stoppered bottle in a cool, dark place, preferably on ice, from the time of preparation to the time of use. He continued: "The toxins keep some, though not all, of their

SERIES A, INOPERABLE SUCCESSES, DETAILED HISTORIES

virulence for a long period of time, and in some cases excellent results have been obtained from preparations which were at least eight months old. My own experience is that the mixed toxins are liable to lose some of their efficiency with time, and I do not myself use preparations more than a few weeks old."

REFERENCES: 41; 42; 67

CASE 38: Recurrent sarcoma of the left ovary, confirmed by microscopic examination by Dr. Malvern B. Clopton, pathologist.

PREVIOUS HISTORY: Female, aged 30. The patient had suffered for years with profuse menstrual periods which were irregular and too frequent.

SURGERY: A curettage was performed on November 13, 1906, with thorough examination under anesthesia. The uterus was found in good position and was not especially large. Behind the uterus in the hollow of the sacrum was found a mass as large as a lemon which felt rather hard, somewhat nodular, but was freely movable. This mass could be pushed up out of the cul-de-sac, and would fall in front of the uterus, pressing on the bladder. The patient was informed there was a solid tumor in the ovary, which should be removed by operation. Consent was not given until July 18, 1907, eight months later. The operation was performed by Dr. Harvey J. Mudd of St. Louis, Missouri. The incision was made in the median line, exposing a dark, congested tumor which looked almost gangrenous. It was 18 cm. in diameter. Adhesions were freed and there was a flow of dark serous fluid. The tumor was attached to the left ovary with rather a long pedicle. The appendix was also removed. Before the abdominal wound had healed a recurrent mass appeared in the abdominal wall.

TOXIN THERAPY (*Tracy X*): Injections were begun by Mudd and under continued treatment the tumor disappeared. Unfortunately, details of administration in this case were not recorded, but at this time Coley was advocating intratumoral alternating with intramuscular injections and larger initial doses than in later years. Also the product used was a potent one.

CLINICAL COURSE: The patient remained free from any evidence of recurrence. On May 19, 1915 she was seized with severe cramping pains in the abdomen and two days later showed evidences of marked obstruction. An operation was performed under ether, the incision being made a little to the left of the median line. On opening the abdomen a large quantity of dark, blood-stained fluid escaped. There presented at the opening a very large coil of very dark, much distended small intestine. The nature of the obstruction could not be made out readily. The coil of intestine was delivered through the wound. At the base was a narrow band

SERIES A, INOPERABLE SUCCESSES, DETAILED HISTORIES

which constricted the coil so tightly that it was almost gangrenous. This band was cut and was found to be the right Fallopian tube, wrapped tightly about the gut with adhesions at the end of the tube. The patient made a nice recovery and remained well when last traced in June 1919, 12 years after treatment, at which time Mudd cited the case in discussing Coley's paper before the American Surgical Association. He stated: "I report this as merely one more cure of a frightfully malignant condition by Coley's toxins."

NOTE: It is known that Mudd continued using the toxins in many other cases through 1919, possibly later, but this seems to be the only case of ovarian cancer he treated.

REFERENCES: 51, (Discussion by Mudd); 67; 193

CASE 39: Inoperable recurrent leiomyosarcoma of the uterus, confirmed by microscopic examination by Dr. Mallory, Professor of Pathology at Harvard Medical School.

PREVIOUS HISTORY: Miss M.L.W., aged 42, of Worcester, Mass. The patient's mother had died of a malignant tumor of the uterus, without operation. The patient's previous history had been negative. On January 8, 1907, she was operated upon at the Boston City Hospital for a tumor of the uterus by Dr. Homer Gage of Worcester. The uterus was removed. The growth was thought clinically to be a fibroid and proved to be a leiomyosarcoma, following examination by Mallory. During the following summer the patient began to have intermittent attacks of frequent micturition, accompanied by pain. Vaginal examination in September 1907 by Dr. Edward Reynolds of Boston revealed a mass in the vault of the vagina which had almost doubled in size since the last examination a few weeks before. There was also a reddened surface on the posterior wall of the bladder which by September had developed into well-marked papillomata. Reynolds stated in a letter to Dr. W. B. Coley: "I looked on the case as practically hopeless, but recommended Dr. Wheeler to send her to you as the one chance remaining." At examination on September 26, 1907, Coley found an infiltrating tumor occupying the whole lower portion of the pelvis, apparently involving the bladder wall. The tumor was hard in consistency, irregular in outline, and had the "feel" of carcinoma, rather than sarcoma. The condition was entirely inoperable. The patient was suffering a great deal of pain, and had frequent and painful micturition, and had lost considerably in general health. Although the prognosis was unfavorable, Coley decided to give her a brief trial with the toxins. She was admitted to Memorial Hospital on October 1, 1907. Bimanual examination on admission showed a tumor infiltrating the anterior vaginal wall, involving the bladder wall down to the symphysis and extending as high as the finger could

SERIES A, INOPERABLE SUCCESSES, DETAILED HISTORIES

reach. The mass was fixed. There was no ulceration of the vaginal wall. The point of origin was probably in the incision of the old hysterectomy wound.

TOXIN THERAPY (*Tracy X and XI*): Injections were begun by Coley on October 1, and were given daily for 8 days and thereafter five times a week in doses of 0.5 to 6 minims. These caused moderate reaction, no chills. Definite improvement was noted within two weeks, as shown by marked cessation of pain as well as softening and regression of the tumor and improvement in the general condition. The patient was sent home at the end of three weeks, and treatment was continued by Dr. Leonard Wheeler, the family physician, three or four times a week, with occasional intervals of rest. In March and April 1908 one bottle of the Parke Davis unfiltered preparation (Type XII) was used, and from May to July 1909 the Parke Davis filtrate (Type XII F) was administered. During August and September 1908 injections were suspended for almost two months, because of the hot weather. During this time the former symptoms returned and the growth seemed to increase in size. Injections were resumed and with continued treatment the symptoms again entirely disappeared and the growth became smaller and softer. The Parke Davis preparation (XII) was again used in March 1909 and February 1910. Injections were discontinued entirely about the end of February 1910, after having been administered for nearly 2½ years. The last year of treatment they were given by a nurse. The patient's general condition was practically perfect the entire time. Coley stated that in this case the dose was never increased beyond 5 minims, which was sufficient to produce slight malaise and a temperature of 99° or 100°F. three times a week. The low dosage and mild reactions would appear to be the reason the growth regressed so slowly. In writing Coley regarding the progress of the case, Reynolds stated in May 1909: "It has struck me as one of the most remarkable cases I have ever heard of. Results have certainly in every way justified the use of the toxins whether they effect a final cure or not." (67)

CLINICAL COURSE: In May 1910 Coley examined the patient and found only "small traces of the original tumor remaining, and what was left, much softer". She had regained her former weight and stated that she had never felt better. Another examination, in June 1911, showed no trace of the tumor remaining. The patient weighed more than she ever had and her general health was perfect. She remained well during the next 35 years. She was last heard from in February 1944. Her only complaint at that time was that she was having some trouble with her heart. She died on March 28, 1944, of cerebral hemorrhage and hypertension at the age of 80, 37 years after toxin therapy.

REFERENCES: 7; 10; 48, Case 3; 128; 193

CASE 40: Recurrent inoperable large round cell sar-

SERIES A, INOPERABLE SUCCESSES, DETAILED HISTORIES

coma of the muscles of the back, with metastasis to the lower jaw, confirmed by microscopic examination of the primary growth by Dr. John Funke, pathologist at the Jefferson Medical College, Philadelphia, Pennsylvania.

PREVIOUS HISTORY: C.E.C., male, aged 27, of Tamaqua, Pa. The family history was negative for malignancy of tuberculosis at that time, but in 1944 one sister died of carcinoma of the colon. The patient had always been in good health. Onset, in September 1907 a tumor was first noticed in the lower lumbar region at the sacroiliac junction.

SURGERY: It increased in size very rapidly, and two operations were performed in rapid succession in September and October 1907 by Dr. J. C. Biddle of Fountain Springs, Pennsylvania. At the operation in September a tumor the size of two fists was removed. It was of muscular origin, did not involve the bone, but extended down to and round the spinal nerves.

CLINICAL COURSE: A metastatic tumor then developed in the lower jaw. At this time Biddle regarded the prognosis as hopeless and sent the patient home. In November 1907 he was referred to Dr. W. B. Coley by Biddle. At this time he was greatly emaciated and unable to walk without help. In view of the very rapid growth of the tumor with such early metastasis, Coley also gave a very grave prognosis. Examination at this time showed an unhealed wound in the lumbar and gluteal region 15 by 20 cm. in diameter, the unhealed portion being an excavation about 2 cm. lower than the surrounding tissue. The lower jaw showed a tumor beginning about 2 cm. to the left of the symphysis, extending nearly to the angle of the jaw on that side, and apparently occupying the entire thickness of the jaw. (43)

TOXIN THERAPY (Tracy X): Injections were begun by Coley on November 19, 1907, the initial dose being $\frac{1}{4}$ minim given in the gluteal region. The dose was gradually increased until a febrile reaction of 104°F. was obtained following the third or fourth injection. Five injections of Tracy's filtrate (Type X F) were given into the tumor of the jaw in doses of $\frac{3}{4}$ minim, the remaining being given in the gluteal region. In describing the effects of the toxins, the patient stated that a few days after the injections were given into the tumor of the jaw, "I thought I could feel the growth disintegrate. It may be that the total of all the careful treatment from the start was making itself manifest." The highest dose of the unfiltered preparation which was tolerated was 8 minims. The injections were given four or five times a week. The tumor of the jaw slowly became smaller and much softer. When it became fluctuating, Coley made an incision over the most protuberant part and found a highly vascular tumor extending down to the periosteum. The

SERIES A, INOPERABLE SUCCESSES, DETAILED HISTORIES

patient's general condition slowly began to improve under treatment. At the end of the first month there was but slight improvement, while two weeks later the improvement was marked. By early January the patient had gained five pounds. From that time on the tumors melted away with great rapidity until at the end of ten weeks there was no trace left either in the back or on the jaw. Three months after treatment was begun, on February 8, 1908, the patient had regained his lost weight and most of his strength and was allowed to go home. The toxins were continued by the family physician twice a week for two months and once a week until July 1908, a total duration of about eight months. During the last three months of treatment the Parke Davis filtrate (XII F) was used. No other form of treatment was given.

CLINICAL COURSE: The patient was seen periodically by Coley. He remained in good health and free from further recurrence or metastases. By July 1909 he had gained 69 pounds, and thereafter he maintained a weight of 205 pounds for some years. Coley presented him before the Clinical Congress of Surgeons of North America on November 12, 1912. In March 1942 the patient reported that he had been very active since 1908, the previous 12 years as a bank executive without vacations except for a few days at a time. He further stated: "My judgment from observations is that the toxins must be used with skill and care; that the dose and the frequency of the injections are important" (10) In June 1944 one of his sisters died of carcinoma of the colon, and within a few months a brother died. That autumn the patient's health, which had been very good until that time, began to deteriorate. He lost about 45 or 50 pounds in weight during the next year and became quite nervous, with anorexia and faulty digestion. In March 1946 he was admitted to the Pottsville Hospital where he remained under observation for two weeks. Various tests were made and the family was told that these were all negative for cancer or for gastric ulcer. On May 23 he was admitted to the Temple University Hospital in Philadelphia, under the care of Dr. William W. Babcock. Babcock stated that "apparently carcinoma had developed internally at the site of the original growth in the lumbar region in 1907, and had involved all the abdominal viscera." The patient was discharged 13 days later and died at his home on June 11, 1946, at the age of 73. This was 38 years after toxin therapy had caused complete regression of the sarcoma. (10)

RÉFERENCES: 10; 43; 46; 51; 128; 139, Case 11

TRACY XI: The following 19 cases were treated with the Tracy XI product. In this preparation Tracy used the mixed unfiltered toxins of *Streptococcus pyogenes* and *Bacillus prodigiosus*, with much the same formula as for Tracy X, except that the amount of *prodigiosus* was reduced one half, to 2.5 mg. per cc. of the mixed toxins. During part of this period only 2 mg. per cc. was used. In

SERIES A, INOPERABLE SUCCESSES, DETAILED HISTORIES

1909 Coley made the statement that all of his good results had been obtained with the Buxton toxins (Types V and VI) or with the Tracy X and XI. (For the detailed formula used in making Tracy XI, see 46 or 51.)

Among the foreign physicians who used Tracy's product, Odier of l'Institut pour l'Etude des Maladies Cancéreuses, Geneva, Switzerland, reported his experience in 1908 (158) As to technique, he advised injections in the vicinity of the tumor, and gradually into the tumor itself. If the tumor was inaccessible, that is, in the abdominal cavity or the pelvic region, he advised making the injections in the gluteal region or in the immediate vicinity of the growth, in the abdominal wall. He suggested daily injections, if possible, otherwise every two days.

He stated that the development of fluctuation was always a good symptom during toxin therapy, and that it might be localized or progressively affect the whole tumor. He added that it was indispensable to build up the patient by tonics, especially strychnine, quinine and iron.

He warned against the danger of not thoroughly shaking the bottle (injecting the weaker, clear fluid at first and later getting a heavy concentration of the residue). (158)

CASE 41: Recurrent inoperable round cell sarcoma of the uterus, confirmed by microscopic examination by Dr. Rudolf Steiner, pathologist at the Hartford Hospital, Hartford, Connecticut.

PREVIOUS HISTORY: Mrs. C. McM., aged 50, of Hartford. The family and personal history not recorded.

SURGERY: The patient was operated on for a large tumor of the uterus in the spring of 1907 at the Hartford Hospital by Dr. Harmon G. Howe.

CLINICAL COURSE: The tumor recurred and the patient was referred to Dr. W. B. Coley for consultation early in April 1908 as a totally inoperable case. Examination at that time revealed an infiltrating tumor which filled the whole pelvis and which was so hard that clinically it resembled carcinoma, rather than sarcoma. The patient had severe pain, her general health had failed markedly, and bladder symptoms had developed. Coley regarded the prognosis as hopeless and told Howe that all that could be expected was to hold the disease temporarily in check.

TOXIN THERAPY (Tracy XI): Injections were begun by Howe under Coley's instructions on April 7, 1908, and were continued four times a week. Gradually the frequency was reduced to twice a week. The patient's general condition soon

SERIES A, INOPERABLE SUCCESSES, DETAILED HISTORIES

began to improve, the pain disappeared and the tumor diminished steadily in size until August 1908, when the injections were suspended for two weeks. Immediately the severe pains returned. Howe resumed the toxins, giving injections every other day through September, then twice a week, then once a week, and finally once in ten days. On December 14, 1908, after eight months' treatment, the patient wrote Coley reporting her condition. At this time the infiltrating growth had entirely disappeared. She stated: "I feel so well that I can hardly believe I am myself, and on all sides people are congratulating me." (47) Although the disease had apparently entirely regressed, the injections were continued for a total of 26 months, during which time she received 118 injections.

CLINICAL COURSE: The patient was presented by Coley before the Clinical Congress of Surgeons of North America on November 12, 1912. She was examined periodically by Howe and remained free from further recurrence. She was again presented before the Clinical Congress of Surgeons of North America by Coley in 1933, at which time she was in excellent health. She was last traced by Coley in January 1935 and was well at that time. She died on July 7, 1936 at the age of 81, of cerebral arteriosclerosis, 28 years after the toxins were first administered, having never had any further recurrence.

COMMENT: This case seems to indicate the danger of suspending the injections or decreasing the frequency too soon in far-advanced cases as control of the disease may be lost. Note that the toxins stopped the pain in this case and that when the injections were suspended the pain returned at once. These points suggest the importance of sustained, aggressive treatment.

REFERENCES: 10; 47; 51, Case 67; 67

CASE 42: Extensive recurrent inoperable round cell sarcoma, involving all the abdominal viscera, confirmed by microscopic examination by Dr. R. E. Isaacs, of Beth Israel Hospital, New York.

PREVIOUS HISTORY: Mrs. S.R., female, adult. The family and previous personal history were not recorded.

SURGERY: The patient was operated upon by Isaacs at Beth Israel Hospital for a very extensive cystic sarcoma of the pelvis, involving all the viscera. The pelvis was cleaned out as well as possible, but a recurrence was considered inevitable as all the organs were involved in the adhesions. The patient made a prompt recovery from the operation, but a fistula remained.

RADIATION: X-ray treatment was administered but caused so much dermatitis that it was stopped.

SERIES A, INOPERABLE SUCCESSES, DETAILED HISTORIES

CLINICAL COURSE: A recurrence developed, and the patient was seen by Dr. Arpad Gerster, who advised the use of the Coley toxins. At this time the whole abdomen was apparently filled with an inoperable tumor. The prognosis was regarded as unpromising.

TOXIN THERAPY (*Tracy XI*): As Dr. W. B. Coley was in Europe, the toxins were administered by Dr. J. C. Reshower, the family physician. The injections were given at first daily, then every other day, then twice a week. The initial dose was 0.5 minim, and the dose was increased each time by 0.5 minim. The patient proved rather susceptible to the toxins, 1¼ minims producing a severe chill, with a temperature of 103°F. She became more tolerant as the treatment was continued. By the beginning of April 1909 she had received 60 injections, the maximum dose being 11 minims. During this period of nine months the intraabdominal tumor disappeared.

CLINICAL COURSE: The patient remained in good health and free from further recurrence. She was presented by Coley before the New York Surgical Society on April 28, 1915. At that time he stated that ever since the operation the patient had occasional slight swelling of the right foot and leg, with frequent pains. She was married in 1913, but did not become pregnant during the next two years. (She had had x-ray therapy to the pelvis.) Coley examined her under ether at Memorial Hospital in April 1915, and, with the exception of a small swelling the size of a goose egg on the right side (probably a cystic ovary), nothing of a suspicious nature could be found. The patient remained in excellent general health, about eight years after onset or toxin therapy. She was not traced subsequently.

REFERENCES: 10; 67

CASE 43: Inoperable spindle cell sarcoma of the left ovary, involving the broad ligament, uterus and intestine, confirmed by microscopic examination following exploratory laparotomy at the Lewiston City Hospital, Lewiston, Maine. The pathologist reported: "On preparing the patient for operation the condition was found to be so complicated that the surgeon decided to postpone the operation until a microscopic examination could be made of a section of the growth: at the time of the operation they removed only a small piece for me to examine; they were afraid of hemorrhage. The tissue I examined in frozen section, while still on the table, gave a diagnosis of spindle cell sarcoma." (67)

SERIES A, INOPERABLE SUCCESSES, DETAILED HISTORIES

PREVIOUS HISTORY: Female, aged 22, married. The patient's father had died of "inflammation of the bowels", her mother of "general debility, due to frequent childbirth". The patient had always enjoyed very good health until onset. She had had one child. Onset began with a sensation of weight in the pelvis about 13 months prior to admission. Although her periods came at regular intervals, she believed she was again pregnant, and a year after onset she consulted Dr. F. L. Tosier, of Washburn, Maine. A small, soft, boggy growth about the size of a cup was found in the region of the left ovary, which he believed represented a diseased ovary. He kept the patient under observation for three months. By this time the growth had become considerably larger and harder. It was attached to the left broad ligament and uterus, and was easily movable with the finger in the vagina or rectum. The growth caused much pain and operation was advised.

SURGERY: She was admitted to the Lewiston City Hospital in December 1908, where a biopsy was performed as stated above. Because of the extensive involvement and fear of hemorrhage, no attempt at removal was made, and after taking a section for biopsy, the incision was closed and the patient was sent home to die. (67)

TOXIN THERAPY (*Tracy XI*): Injections were begun by Tosier on her return home in December 1908. The initial dose was 0.5 minim diluted in 10 minims of sterile water, apparently given intramuscularly. This caused chills and a febrile reaction of 103°F., a pulse of 100 to 120. Reactions of 100° to 103°F. occurred following the daily injections and became more pronounced when the dose was increased too rapidly. The first three days 0.5 minim was given, then 1 minim for three days and thereafter the dose was gradually increased as the tolerance of the patient increased, until finally 8 to 10 minims were given. The tumor entirely disappeared. At first the discharge from the laparotomy wound was more like pus, and gradually it became more serous in character, then it soon ceased.

CLINICAL COURSE: Seven months later the patient had gained 60 pounds, her periods were regular and normal, and there was no evidence of further trouble. In the autumn of 1910, about a year after the toxins were stopped, the patient gave birth to a second child. She remained in good health when last traced, over five years after onset.

REFERENCES: 48; 51, Case 72 in Table of other surgeons' cases; 67; 100, Case 60; 192a.

CASE 44: Twice-recurrent inoperable spindle cell sarcoma of the right kidney, confirmed by microscopic examination; the metastatic growths involved much of the intestines.

SERIES A, INOPERABLE SUCCESSES, DETAILED HISTORIES

PREVIOUS HISTORY: H.H., male, aged 33. The family history was negative for malignancy or specific disease. There was no history of trauma. The patient had been ill six months, suffering from cough, but examination of the lungs revealed nothing but "bronchial trouble"—he was being treated for pulmonary tuberculosis. The patient's normal weight was 180 pounds, and he had lost 40 pounds in the previous six months. Examination of the abdomen revealed an enormous, solid, non-fluctuating growth which filled the whole abdominal cavity.

SURGERY: Exploratory laparotomy revealed a solid tumor of the right kidney with large blood vessels shining through the periosteum. As it was evident that the growth could not be removed without bisecting it, another opening was made in the loin. A pedicle was clamped through the incision in the loin, thus controlling the blood vessels. The tumor was then removed by an incision through its center. The vessels were tied, and the ureter examined and found not diseased. The patient made a smooth recovery and was discharged from the hospital on June 26, 1908. The tumor weighed 13½ pounds and was practically solid except for a few cysts the size of a pigeon's egg.

CLINICAL COURSE: The patient returned to the hospital on April 17, 1910 with a swelling in the groin the size of an orange. This was found to be an omental hernia with malignant degeneration. The whole omentum was removed up to the stomach. No other growth was apparent in the abdominal cavity. On June 27, 1910 the patient was readmitted to the hospital with irregular recurrent growths on the right side of the abdomen.

FURTHER SURGERY: Exploratory incision proved them to be inoperable, as they involved so much of the intestines.

TOXIN THERAPY (*Tracy XI*): After recovery from this procedure, Dr. Henry M. Leach of Saginaw, Michigan, administered Coley toxins, causing marked reactions on several occasions. A total of 41 injections were given, and in two months the recurrent tumors had entirely disappeared. The patient regained the 40 pounds he had lost and his former strength.

CLINICAL COURSE: He was reported perfectly well in January 1916, over six years after onset. He was not traced subsequently.

REFERENCES: 10; 67

CASE 45: Huge inoperable spindle cell sarcoma of the thigh and groin, confirmed by microscopic examination at the Jefferson Hospital, Philadelphia, Pa.

SERIES A, INOPERABLE SUCCESSES, DETAILED HISTORIES

PREVIOUS HISTORY: Female adult. No details were given as to the family and early personal history.

SURGERY: A portion of the growth was removed by Dr. John Chalmers Da Costa, of Philadelphia.

TOXIN THERAPY (*Tracy XI*): Injections were begun immediately after operation and were continued daily. This patient had a violent reaction every day for weeks. She was given as much as 7 minims at a dose. The remainder of the huge growth completely disappeared under treatment.

CLINICAL COURSE: The patient remained well and free from recurrence when last traced over four years after onset.

REFERENCE: 72, p. 294

CASE 46: Inoperable round cell sarcoma of the right rectus and external oblique muscles, confirmed by microscopic examination following exploratory operation at the Good Samaritan Hospital, Cincinnati, Ohio.

PREVIOUS HISTORY: J.M., male, aged 52, travelling salesman. The previous history was non-contributory. Onset, prior to April 1910 the patient developed a "lump" on his side and consulted a physician who referred him to Dr. W. D. Haines, Professor of Surgery, University of Cincinnati, on April 22, 1910. Examination revealed a growth the size of a hen's egg in the abdominal wall, midway between the costal arch and the umbilicus on the right side. The tumor was immovable and sensitive to palpation. The patient stated that he frequently had chills over the right side and leg. No enlarged lymph nodes were palpable in the axilla or groin on the right side.

SURGERY: On April 25, 1910 Haines performed an exploratory operation at the Good Samaritan Hospital, which revealed a hard mass springing from the right rectus and intimately attached to the overlying aponeurosis of the external oblique. The growth was incompletely removed. The clinical and postoperative findings were confirmed by microscopic examination.

TOXIN THERAPY (*Tracy XI*): Injections were begun by Haines immediately following the exploratory operation, and were continued at home with intervals of rest for over six months. Three courses of injections were given. Haines stated that there was considerable sloughing of necrotic tumor tissue during the treatment. The remains of the sarcoma disappeared.

SERIES A, INOPERABLE SUCCESSES, DETAILED HISTORIES

CLINICAL COURSE: The patient made a good recovery with a smooth scar over the site of the former growth. He remained in good health and free from recurrence until his death in 1933 from a heart attack, 22 years after toxin therapy. (10; 67)

COMMENT: Haines produced a number of other successful results in various types of tumors in the next 20 years.

REFERENCES: 10; 51, p. 166; 67

CASE 47: Many-times recurrent extensive infiltrating spindle cell sarcoma of the antrum and ethmoid, apparently inoperable, confirmed by microscopic examination after the last two operations at Massachusetts General Hospital, Boston, Mass. There had been four previous operations elsewhere.

PREVIOUS HISTORY: Mrs. L.E.F., female, aged 46, of Wakefield, Mass. The patient's parents were dead, five siblings were living and well, but two sisters had died of "tumors". The patient had had the usual childhood diseases, also typhoid fever at 22. She was married and had had two children who were both living and well. She had also had several miscarriages. She had had nocturia for years, also some dyspnea with palpitation, and occasional edema of the ankles and eyelids. The appetite was good, the bowels regular. Onset, early in 1904, eight years prior to admission, she first noticed something "moving inside the nose when blowing it".

SURGERY: A mass in the nares was partially removed by a local physician, but it recurred a year later. A second incomplete operation was performed at the Eye and Ear Infirmary, Boston, early in 1905. The patient was then referred to the Massachusetts General Hospital Out-Patient Department where a considerable amount of tumor tissue was removed with cutting forceps.

CLINICAL COURSE: There was no evidence of further recurrence until the summer of 1911, six years later, when the patient began to feel a dull pain between the eyes, headaches and sudden spontaneous epistaxis. These symptoms increased in frequency and intensity. By October there were intermittent attacks of dizziness, nausea and throbbing in the head.

FURTHER SURGERY: On February 12, 1912 Dr. Crosby Greene operated under ether (the sixth operation). Through an incision at the side of the nose and beneath the eye the antrum was opened. Its inner wall and the middle turbinate were removed. The ethmoidal region was found filled with a vascular growth which was curetted. A large portion of the right nasal bone was removed. There

SERIES A, INOPERABLE SUCCESSES, DETAILED HISTORIES

was little bleeding at any time. At the end of the operation the cribiform plate was exposed and brain pulsations were observed. The frontal sinus contained a small amount of mucopurulent material which was sponged out. Dr. Torr W. Harmer did not believe that all the tumor tissue was removed. The post-operative course was uneventful.

TOXIN THERAPY (*Tracy XI*): Injections were begun by Harmer on February 19, 1912, a week after the sixth operation, and were continued for six weeks, the dose being increased to 4 minims. Febrile reactions were moderate.

CLINICAL COURSE: There was no further recurrence. The patient regained her health and strength and remained in excellent condition when last seen by Harmer on May 29, 1914. (100, Case 3) She later moved to Maine where she died at the age of 66, on April 16, 1932, of cerebral hemorrhage. (10) This was 20 years after recovery following toxin therapy, and 28 years after onset of the primary tumor.

REFERENCES: 10; 100, Case 3; 120

CASE 48: Inoperable spindle cell sarcoma of the retroperitoneal region and iliac fossa, was the clinical diagnosis of Dr. John F. Erdmann and Dr. W. B. Coley. Examination of necrotic tumor tissue evacuated after four weeks' toxin therapy was reported by Dr. James Ewing as follows: "The sections show a process which is either very closely related to, or identical with sarcoma. It is made up chiefly of granulation tissue, spindle cells and giant cells. Much of it is necrotic. The process shows no signs of tubercle." (55, Case 3)

PREVIOUS HISTORY: J.G.K., male, aged 25, of North Plainfield, New Jersey. The family history was non-contributory. Onset, the patient first noticed a swelling in December 1911, four months prior to consulting Coley. There was rapid increase in size, slight loss of weight, but no fever or pain. Physical examination on March 26, 1912, showed a tumor behind the right inguinal and iliac region, extending down over the crest of the ilium, but not into Scarpa's triangle. It apparently originated in the retroperitoneal region or the anterior surface of the ilium. The growth was soft and semi-fluctuating in consistency, with small areas almost nodular in character. The overlying skin was not involved. Erdmann examined the patient in consultation and pronounced the disease sarcoma and inoperable. Aspiration showed only bloody serum. The patient was admitted to Dr. Bull's Private Hospital.

SERIES A, INOPERABLE SUCCESSES, DETAILED HISTORIES

TOXIN THERAPY (*Tracy XI*): Injections were begun on March 26, 1912 and the dose was rapidly increased to 20 minims. After four weeks' treatment the tumor became smaller and fluctuating. An incision was made under ether just above the upper part of the ilium and several ounces of necrotic material was evacuated, which microscopically resembled broken-down tumor tissue. It was too badly degenerated to make satisfactory sections. The toxins were then continued for several weeks, during which time the sinus healed and the tumor entirely disappeared.

CLINICAL COURSE: The patient made a complete recovery and remained well and free from recurrence when last traced in 1918, over six years after onset.

REFERENCES: 51, Case 30, p. 56; 55, Case 3; 67

CASE 49: Inoperable mixed small cell sarcoma of the groin, confirmed by microscopic examination by Dr. Revell, the Alberta Government pathologist, and by Dr. J. Clark Stewart of Minneapolis, Minnesota, who reported that it appeared to be decidedly malignant. (127, Case 19-66345)

PREVIOUS HISTORY: D.A.D., male, aged 56, of Bawlf, Alberta, Canada. The family history was apparently negative for malignancy, tuberculosis, venereal disease or diabetes. One brother had died of pneumonia. There was no history of antecedent local trauma, infection or sprain. The patient was a heavy man, her normal weight being 212 pounds. Onset, 2½ months prior to toxin therapy, about February 1, 1912, his appetite, weight and strength began to fail. A month later he noticed a painless tumor in the right groin. It was very small at first but gradually got larger.

SURGERY: On March 14, 1912 a specimen was removed at home by Drs. McEachern of Bawlf, and Dr. Harrison of Edmonton, Alberta. The tissue was sent to the Alberta Government pathologist in Edmonton, who pronounced it sarcoma. The patient appeared to improve generally and gained some weight after this exploratory operation. On April 6, 1912 he registered at the Mayo Clinic and was seen by Dr. Judd. At this time he weighed about 15 pounds less than normal. Physical examination revealed a "recent operative wound in the right inguinal region which was discharging serum. There were no palpable nodes, but there was a questionable mass within the brim of the right side of the pelvis." (127) The condition was considered inoperable and no treatment was administered at the Mayo Clinic. The patient was immediately referred to Stewart of Minneapolis for toxin therapy.

SERIES A, INOPERABLE SUCCESSES, DETAILED HISTORIES

TOXIN THERAPY (*Tracy XI*): Stewart was familiar with the Coley toxins and he had successfully treated other cases. This physician was apparently aware of the importance of technique, for in describing his treatment the patient wrote Dr. W. B. Coley as follows: "Dr. Stewart . . . took great pains to have me understand fully as to the treatment, the amount of toxin to give each time, whether to increase or decrease, or to skip one treatment; altogether he was very particular to give me the right amount to the fraction of a minim. He was also very particular as to the time the temperature was to be taken . . . and also the length of time required to make sure of a perfect cure." (67) Under toxin therapy the growth disappeared.

CLINICAL COURSE: On May 17, 1913 Stewart wrote Judd that the patient was entirely well. He remained in good health and free from recurrence in August, 1930 at which time he wrote Coley as follows: "Here I am, 74 years old, my health perfect, and full of vigor for a man of my age." In 1933 or early 1934 the patient developed carcinoma of the stomach, with metastases to the spine, and death occurred on September 21, 1934, of general carcinomatosis. This was 22½ years after onset of the sarcoma.

REFERENCES: 10; 67; 127

CASE 50: Inoperable hypernephroma, involving the retroperitoneal lymph nodes, confirmed by microscopic examination by Dr. W. A. Lindsay, pathologist at the Victoria General Hospital, Halifax (formerly at Edinburgh University), and Dr. John Stewart.

PREVIOUS HISTORY: Miss M.P., female, aged 27, of Kentville, Nova Scotia. The family history was apparently negative as regards malignancy in 1912, but in 1945 the patient's mother had a radical mastectomy and the patient's sister had a "cyst" in the uterus requiring a hysterectomy. The youngest sister had tuberculosis. In the winter of 1895, at the age of 10, the patient was injured in the back over the right kidney region while skating. Following this she developed jaundice and that summer had "blood poisoning in her right hand. Two or three years later she had scarlet fever and her attending physician told her that the "glands in the neck and the kidneys were injured". In 1902 she had pertussis. Menses began at 12 and were very irregular for three years, with severe headache, constipation, nausea, some pain and excess flow. Thereafter until menopause, menstruation was normal. Onset, early in 1912 the patient's health rapidly began to deteriorate. In the latter part of August, nine months later, the family physician found a large mass in the ileolumbar region. The patient was taken to Halifax and consulted Drs. H. K. MacDonald and John Stewart (a pupil of Lord Lister).

SERIES A, INOPERABLE SUCCESSES, DETAILED HISTORIES

SURGERY: An exploratory operation was made, through a loin incision, and the kidney was exposed. The upper and middle third were found to be apparently normal, the lower pole being occupied by a large tumor which was adherent to a much large growth anteriorly. A section was removed for microscopic examination. The patient was then turned upon her back and a laparotomy done, disclosing a large retroperitoneal mass which could not be removed. She made a very poor operative recovery and a sinus developed at the site of the loin incision. The condition was regarded as absolutely hopeless, and she was removed on a stretcher and special car to her home. No one believed that she would survive the journey. (51, p. 144)

TOXIN THERAPY (*Tracy XI*): Injections were begun by MacDonald about September 21, 1912, around three weeks after the exploratory operation. They were given intramuscularly in the buttocks. MacDonald stated that her condition at this time was so bad that the toxins were used as a last resort, and he thought that "if they were of no benefit, they would perhaps have the other effect and put the patient out of her misery". However, after the first injection she began to improve. When a dose of 4 minims had been reached, the sinuses in the lumbar region closed. Marked reactions occurred after each of the injections, which were given in the morning: the temperature would rise to about 105°F., dropping to normal in the late afternoon. The tumor began to show marked decrease in size. After 18 injections had been given, Dr. Arthur S. Burns, of Kentville, Nova Scotia, the family physician, stated that the mass in the loin had practically disappeared, that the patient was rapidly putting on weight, and in every way showed marked improvement. The toxins were discontinued on November 9, 1912. By January 23, 1913, four months after treatment was begun, the patient had gained 20 pounds in weight. She ate and slept well, was up and around the house, and was making steady improvement. Careful examination by two physicians failed to reveal any evidence of tumor or enlargement of any kind. Dr. W. B. Coley advised that the injections be continued until the end of January. The recovery was so rapid that the family physician did not consider this necessary. (51, p. 144)

CLINICAL COURSE: Improvement continued, and by the middle of the following June the patient had gained 32 pounds. She was examined two or three times a year by MacDonald, who reported to Coley on her condition. In 1927, 15 years after toxin treatment, the patient developed multiple fibroids, requiring a supravaginal hysterectomy and oophorectomy. At this time MacDonald made a very complete and thorough examination of the abdomen, particularly at the site of the former tumor, and found no evidence of disease of any kind. MacDonald stated that she made a good operative recovery and had since enjoyed excellent health. However, the patient stated in reviewing her history in June 1947 that she had never been extremely well since 1912; that she had had several operations on her bowels due to obstruction and adhesions resulting in loss of muscle tone

SERIES A, INOPERABLE SUCCESSES, DETAILED HISTORIES

and chronic constipation. She remained in good health until cerebrovascular disease developed a few years later. Death occurred from a heart attack in November 1966, 54 years after onset.

COMMENT: This case indicates that a permanent result may be obtained in far advanced renal cancer when a potent preparation of bacterial toxins is aggressively administered.

REFERENCES: 10; 51; 66; 67; 139, Case 20; 145

CASE 51: Inoperable sarcoma of the left tonsil and palate, confirmed by microscopic examination by Dr. J. J. Coons, State Pathologist, and by Dr. Wooley, who reported: "Inoperable myxosarcoma, probably associated with endothelioma" (177) The clinical diagnosis was also confirmed by Drs. Charles and William Hamilton of Columbus, Ohio. (55) The sections were kept by Dr. Edwin H. Shields.

PREVIOUS HISTORY: Mrs. F.H.D., female, aged 48, of Mt. Sterling, Ohio. The family history was non-contributory. The patient had been married 18 years but had had no children. Menopause occurred at the age of 32. Early in 1912 the patient had had an attack of croup and thereafter her throat was always tender and irritated. With this exception she had always been in normal health until onset, in the spring of 1913, when she noticed some trouble with her breathing at night, and complained of sore throat in the mornings. This finally made it difficult to swallow. At this time the left tonsil and palate were badly swollen and inflamed. The patient consulted Dr. W. G. Lewis of Mt. Sterling, Ohio, in the latter part of July 1913. He advised a consultation, and took her to Coons and Rodgers, of Columbus. Examination at this time revealed a tumor the size of a hazel nut beneath the left ear, having a feeling of fluctuation. There was slight enlargement of the submaxillary nodes on that side. The left tonsil was pushed considerably beyond the median line by a rounded swelling in the soft palate. This tumor extended laterally and connected with the tumor in the neck. The mucosa was freely movable over the swelling. There was no redness or other signs of inflammation. The swelling in the soft palate had a distinct feeling of fluctuation and was not painful.

SURGERY: When the mass was aspirated a clear, colloid fluid was removed. A small incision was made over the tumor in the mouth and a specimen removed with a curette, which appeared like "typical soft cellular sarcoma". An x-ray picture was made by Dr. Lange, which showed nothing of importance. (177) As the condition was inoperable they stated that "the only hope was Coley's toxins, but as the

SERIES A, INOPERABLE SUCCESSES, DETAILED HISTORIES

patient was not very strong it was doubtful if she could stand so severe a treatment and that she would surely die within ten weeks." Through a friend who had been successfully treated with the toxins by Dr. Percy Shields, the patient consulted the latter on September 28, 1913. At this time the tonsil tumor was so large that deglutition and breathing were becoming almost impossible. (55)

TOXIN THERAPY (Tracy XI): Injections were begun on September 29, 1913, the initial dose being $\frac{1}{4}$ minim, which was increased gradually to 21 minims in 35 days. At first they were given daily and then on alternate days. On October 18, 1913, 5 minims were injected directly into the tumor beneath the ear. The growth markedly reduced in size and the tonsil returned to its normal position. Through the biopsy incision it was noted that the tumor was still present but not growing. Dr. Percy Shields wrote to Dr. W. B. Coley regarding this case, stating that he kept the incision in the tonsil open during the time the patient was in the hospital and that necrotic tumor tissue drained through it. (67) The patient was hospitalized from October 5 to November 28, 1913, and thereafter injections were continued at home twice a week in doses of 1 cc. (15 minims). On December 10, 1913 an incision was made in the throat wall. No evidence of tumor could be found anywhere. No injections were given for a period of eight weeks as Dr. Percy Shields became ill, and then the patient came under the care of Dr. Edwin H. Shields. Not knowing how much of a tolerance to the toxins had been lost during the rest period, he reduced the dose to 2 minims, and increased it by 2 minims every third day, and by May 25, 1914, the dose was 20 minims. No severe reactions occurred following the second course of toxin therapy, although the first course caused febrile reactions of 104°F. The patient was presented before the Academy of Medicine of Cincinnati on May 25, 1914. Shields stated that "this patient is of remarkable interest, because the result obtained is seldom seen . . . absolutely positive clinical cure". *He discussed how long the treatment should be kept up in such cases, adding that in his opinion these large doses of Coley's toxins should be continued for at least six months.* In this case the injections were given for 14 months, reducing the frequency at the end to once a week and finally to once in two weeks. The patient weighed 96 pounds when discharged from the hospital in November 1913. Her weight increased gradually to 110 pounds by the spring of 1914, which was her maximum weight prior to onset. By May 1914 Shields stated "she never felt better."

CLINICAL COURSE: There was never any evidence of recurrence. The patient remained in perfect health for five years and then died of pneumonia following the 'flu in 1918. (67)

REFERENCES: 55, Case 33 in Table of other surgeons' cases; 67; 177

CASE 52 Inoperable spindle cell sarcoma of the re-

SERIES A, INOPERABLE SUCCESSES, DETAILED HISTORIES

troperitoneal region, confirmed by microscopic examination, as well as by the clinical findings of Drs. Crile, Lower and Skeelee of Cleveland, Ohio, and Dr. Alexander Cruikshank.

PREVIOUS HISTORY: W.L.W., male, aged 28, of Salem, Ohio. The family history was negative for cancer or tuberculosis. The patient had had the usual diseases of childhood, but had otherwise always been well, except that he was troubled with constipation. He did not smoke or drink. He was married in August 1910. During 1912 and 1913 he had attacks of abdominal cramps every few weeks, which "tied him in knots". These were regarded as being due to the chronic constipation. He consulted Cruikshank of Salem, Ohio, on October 27, 1913, complaining of pain in the lower abdomen and a desire to evacuate the bowels without satisfactory results. Rectal examination revealed a large tender fixed mass in the pelvis.

SURGERY: The following day an exploratory incision in the lower right inguinal region revealed a large retroperitoneal mass, but no pus. The patient returned to work on November 25, having remained under observation at St. Luke's Hospital, Cleveland, for a month. Early in January he was admitted to the Salem Hospital with complete obstruction. The case was referred to Lower, of Cleveland, who concurred in the diagnosis; inoperable sarcoma of the retroperitoneal lymph nodes.

FURTHER SURGERY AND CONCURRENT INFECTION: A colostomy was performed by Lower, who also reopened the old inguinal incision and found pus. Some improvement appeared to take place during this slight wound infection. Cruikshank replaced the bowel on January 28, 1914. At this time the mass seemed quite large, extending to the umbilicus. On January 30, Skeelee saw the patient in consultation, concurred in the diagnosis and advised Coley's toxins. The patient was discharged to his home, the prognosis at this time being regarded as two or three weeks.

TOXIN THERAPY (*Parke Davis XII*): Injections were begun by Cruikshank on February 4, 1914, the initial dose being about 2 minims. At first they were given every other day into the muscles of the abdominal wall, apparently not deeply. The patient stated that "each injection was preceded by cocaine, and the swellings were so severe that they had to be as far apart as possible each time," . . . requiring about ten days to subside. They were given every other day, increasing the dose to about 7 minims. The first five injections caused no reactions. *The Tracy XI product was then substituted* and the second injection of this preparation caused a reaction. Thereafter, distinct febrile reactions (102° - 104°F.) occurred after every injection, followed by chills lasting 30 to 60 minutes. The chills usually

SERIES A, INOPERABLE SUCCESSES, DETAILED HISTORIES

occurred half an hour to two hours after the injection, followed by profuse perspiration, the entire duration of the reaction being about eight or ten hours. During the latter part of the treatment the injections were given in the buttocks. There was gradual reduction of the mass. By March 25, 1914, seven weeks after treatment was begun, Cruikshank wrote Coley: "General health, color and weight has improved. Mass distinctly smaller . . . we get considerable swelling at site of injection and mass will swell up like a 3½ months pregnancy—but will soften down before the next injection." (67) On June 11 he wrote again: "He gained much faster on Huntington toxin (Tracy XI, made under grants from the Huntington Cancer Research Fund), got better reactions: 10 minim doses every second day". (67) The injections were continued through June, making a total duration of about five months, during which time 87 injections were given.

FURTHER SURGERY: Early in June, Cruikshank operated to repair a hernia at the site of the colostomy, and during this operation he examined the retroperitoneal region, stating: "I did not find any trouble except from adhesions. He is practically well, good color, up to normal weight—feels well—no mass exists today—simply marvelous." (67) The patient returned to half-time work in June.

CLINICAL COURSE: By August he weighed 125 pounds, a gain of 30 pounds in six months. He remained in excellent health, with no recurrence. During the next 12 years five children were born, and all were in perfect health in 1946. The patient remained well with the exception of a cholecystectomy in July 1942, for cholelithiasis. The gall bladder condition developed in the spring of 1942 when the patient's oldest son and mainstay in business was inducted into the Armed Services (emotional strain a precipitating cause?). Another operation was performed ten months later, in May 1943, for complete common duct stoppage. The patient wrote on February 25, 1946: "Today I am in practically perfect health except that the doctors have just discovered angina pectoris and cannot understand why this should be present as everything else, such as blood pressure and electrocardiogram, are perfect." (10) The patient's weight during the period 1915-1946 increased to a maximum of 170. From 1943 to 1946 it remained around 157. His height was 5 feet 7 ¾ inches. In February 1949 he had a coronary thrombosis and was under oxygen for six days, hospitalized 30 days, in bed nearly three months. There was no hypertension and the patient believed it was caused by too much strain due to travel and speaking engagements, etc. He made a complete recovery and remained in excellent health. He had a hemiplegia in 1954. In 1959 he developed a gastric carcinoma. Liver metastases developed, causing death on November 8, 1960, 47 years after onset. (10).

REFERENCES: 10; 55, Case 31 in Table of other Surgeon's cases; 67.

CASE 53: Inoperable round cell sarcoma of the naso-

SERIES A, INOPERABLE SUCCESSES, DETAILED HISTORIES

pharynx and right superior maxilla, involving the ethmoid and frontal bones, confirmed by microscopic examination following biopsy at Manhattan Eye and Ear Hospital, New York. The section showed numerous mitoses. (67)

PREVIOUS HISTORY: J.K., male, aged 31, timekeeper. The family history was negative for tuberculosis, malignancy or specific disease. Onset, one year prior to admission, in April 1913, a discharge was noticed from the right naris which continued for four months, during which time no treatment was given. The right nostril gradually became obstructed and the discharge more profuse. A surgeon was consulted who removed several polypi. The usual douches were then prescribed. In October 1913 a soft swelling the size of a hazel nut appeared over the right malar bone. This gradually grew larger and by April 20, 1914 it was the size of a hen's egg. At this time the discharge from the nose was quite profuse and purulent with a disagreeable odor. There was neuralgic pain at the site of the growth, in the upper teeth on the right side, and in the temporal and supra-orbital regions. The patient had lost seven pounds in weight in the previous seven months. There were several enlarged nodes along the anterior border of the sternomastoid muscle, also below the mastoid process.

TOXIN THERAPY (*Tracy XI*): Injections were begun by Dr. W. B. Coley on April 22, 1914, and during the next five days four were given in doses of 0.5 to 1 minim, the site being intramuscularly in the right chest. The average febrile reaction was less than 99°F., but on one occasion it was 103.6°F. On April 30, 1914 the right external carotid artery was ligated by Dr. William A. Downes, and some of the enlarged submaxillary nodes were removed and examined by Dr. James Ewing, who reported they were non-malignant. A week after this operation, the toxins were resumed with a dose of 2 minims given in the right pectoral muscles, which produced a febrile reaction of 104°F. and a chill. The next injection was given four days later, a dose of 3 minims, which caused no reaction. Between May 8 and 27, 1914, six injections were given, an average frequency of every third day. The tumor of the nasopharynx began to diminish in size almost immediately after the injections were begun and continued to decrease while the patient was in the hospital. On May 27 he transferred to the out-patient department, where the injections were given for about four months, at the end of which time all evidence of the tumor had disappeared.

CLINICAL COURSE: The patient remained well and free from recurrence when last traced by Coley in 1924, 11 years after onset.

REFERENCES: 5, discussion by W. B. Coley; 67; 128

SERIES A, INOPERABLE SUCCESSES, DETAILED HISTORIES

CASE 54: Extensive inoperable fibromyxosarcoma of the hip and thigh, with possible involvement of the nodes of the groin, confirmed by microscopic examination at Memorial Hospital of the primary tumor. (128)

PREVIOUS HISTORY: Mrs. D.B., Italian, female, aged 22, of White Plains, New York. The family history was negative for cancer or tuberculosis. The patient was married and had two sons. Menses began at 13, a normal, regular 28-day cycle. Dr. Charles C. Zacharie operated and removed a vaginal myoma during her first pregnancy. The patient had always been in good health until the birth of her second child, three years prior to toxin therapy. Eighteen days after this confinement (a difficult instrumental delivery), chills and high fever developed, and she was treated for "blood poisoning". She then developed an acute appendicitis. Appendectomy disclosed a gangrenous appendix. Two weeks after this operation, a myoma was noticed in the uterus, which was removed. The patient's fever kept high after both operations, up to 107°F. Serum was used, and the patient recovered. Onset, 18 months later, in November 1913, a growth the size of a chestnut was noticed in the left groin, and at about the same time a small mass appeared over the left femur and ilium. An x-ray examination was made, but no treatment was given. The growth increased in size until May 1914, when the patient was referred to Dr. W. B. Coley. Examination at this time revealed a tumor occupying the whole posterior region of the calf and popliteal space of the left leg, apparently infiltrating the muscles and fascia, but not originating in the bone. It was firm in consistency but not bony, appearing deeply fixed. The overlying skin was normal, although the veins were slightly dilated. Flexion was limited to a right angle extension, 170°. There was another larger tumor occupying the entire upper portion of the thigh, extending posteriorly as far as the sacrolumbar vertebra, and anteriorly to the popliteal space. The circumference of this tumor was 70 cm. It extended posteriorly from not more than 2 cm. above the lower tumor upwards a distance of 43 cm. On the inner side it measured 28 cm. A third very small growth was found beneath the skin of the thigh; it was attached to the skin and was the size of a lima bean, soft in consistency and freely movable above the muscles. Another small mass, similar to this one, was found in the left leg. These smaller tumors had increased steadily in size. A few enlarged lymph nodes could be felt in the groin, but none were palpable in the iliac fossa. The patient was in poor general health. She had lost 50 pounds in weight, and weighed only about 96 pounds. There was very severe pain.

TOXIN THERAPY (*Tracy XI and XI F*): Injections were begun by Coley at Memorial Hospital on May 18, 1914, using Tracy's filtrate (XI F), and were given into the buttocks at first.

SERIES A, INOPERABLE SUCCESSES, DETAILED HISTORIES

SURGERY: A specimen was removed on May 26, 1914.

FURTHER TOXIN THERAPY: Thereafter injections were given into the muscles outside the tumor. They produced some slight fever, but no marked reaction or chills. The patient was discharged home on June 8, 1914. Injections were then continued by Zacharie every two or three days. Some of them were given into the growths on the hip, the rest into the surrounding tissues. Measurements taken on June 30, 1914 showed the greatest circumference of the tumor, in front of the gluteal region, had decreased from 70 cm. to 66 cm. The skin over the tumor seemed looser and more freely movable. The growth in the popliteal space was somewhat softer and more discrete, the outline being more clearly defined. Examination by Coley on July 21, 1914 showed the greatest circumference over Scarpa's triangle, to be 73 cm., an apparent increase. However, the overlying skin appeared to be looser. The popliteal tumor filled the whole popliteal space, extending down below the middle of the calf, a total distance of 30 cm. Injections were continued with the result that the tumor ceased to grow, and there were some atrophic changes, but no necrosis, sloughing or discharge. Very little absorption took place. The total duration of treatment was about six months. She was confined to bed only during the febrile reactions, which were moderate. The injections were usually given in the morning and by evening the patient was up and around.

CLINICAL COURSE: The toxins apparently arrested the malignant elements of the growth without causing regression of the fibrous stroma. No further tumors developed. The patient regained her strength and weight very slowly, but by December 1916 Zacharie reported that she was much improved. She eventually regained all the lost weight and strength and was able to do all her own housework and lead an active life, her only disability being that the knee remained stiff, making her lame. She remained in very good health except for some hypertension and arteriosclerosis, first noted about 1944. A relative stated in 1952 that she was "as spry and active as a woman of 40". Her weight in 1951 was 135 pounds, her height 5 feet 2 inches. In 1954 the patient refused to admit she had ever had a tumor, and stated it was a "milk leg" and that she had not seen a physician for years. Sometime in the next few years she developed arthritis of the spine. On December 31, 1959 she had a myocardial infarction. Death occurred on January 15, 1960, at the age of 68, from acute auricular fibrillation with myocardial failure due to arteriosclerotic heart disease. This was over 46 years after onset of her sarcoma.

REFERENCES: 10; 67; 128

CASE 55: Inoperable recurrent sarcoma primary in the nares, involving the superior maxilla, confirmed

SERIES A, INOPERABLE SUCCESSES, DETAILED HISTORIES

by microscopic examination by Dr. Gifford, of Utica, N.Y. In 1920: epithelioma of the hard palate, confirmed by microscopic examination at the State Institute for the Study of Malignant Disease.

PREVIOUS HISTORY: Miss R.A.H., female, aged 56, of Remsen, New York. The family history was negative for tuberculosis, specific or malignant disease. Onset, in the fall of 1913 the patient began to have epistaxis and she had the nose cauterized.

SURGERY: A growth was then removed and three months later it again began to bleed profusely. On June 4, 1914, Dr. J. H. Glass of Utica removed the left superior maxilla, including the left lower orbital plate, to get behind apparently involved tissue. Glass stated it was a "typical neglected and advanced sarcoma".

CLINICAL COURSE: Six weeks later there was an active recurrence, and Glass considered the case as practically hopeless, but advised a trial of the toxins.

TOXIN THERAPY (*Tracy XI*): Injections were begun by Dr. H. H. Williams of Mohawk, New York, on September 1, 1914, the initial dose being $\frac{1}{8}$ minim, and they were given daily during September. The first severe reaction occurred after a dose of 2 minims, the temperature rising to 102° to 103°F. No reaction was obtained after that until a dose of 4½ minims was given. Seven marked reactions were obtained during the entire course of treatment. All injections were given intramuscularly remote from the tumor. During October they were given every other day, in November twice a week, in December once a week. In January they were given once in 10 days, and in February and March only one injection each was given, a total duration of seven months.

CLINICAL COURSE: By December 1914 all evidence of the tumor had disappeared. Glass examined the patient on February 27, 1915, and stated: "She has made marvelous progress and this morning when I saw her was apparently well". She was presented by Dr. W. B. Coley before the American Surgical Association in March 1915, at which time there was absolutely nothing abnormal, either in the interior of the mouth or externally. She remained in good health until April 1920, when a growth developed in the region of the hard palate. This was at first believed to be a recurrence, but sections removed at various times between 1921 and 1923 and examined at the State Institute for the Study of Malignant Disease, showed epithelioma of the hard palate, whereas the primary tumor in 1914 had been a sarcoma of the nares and superior maxilla. Two radium treatments were applied in 1920 at Memorial Hospital in New York under Coley's direction. On November 20, 1920 the patient was admitted to the State Institute for the Study of Malignant Disease and three radium seeds were implanted into the growth (2

SERIES A, INOPERABLE SUCCESSES, DETAILED HISTORIES

mc. each, a total of 792 mch.) The disease was not controlled and later extended to the left nares and antrum. Palliative radium therapy was given between March 8, 1921 and December 15, 1922. Toxin therapy was not administered for this second growth (1920-1923). The disease progressed and death occurred on March 9, 1923, 9½ years after onset of the sarcoma of the nares for which she was successfully treated by toxin therapy.

REFERENCES: 10; 52; 67

CASE 56: Inoperable round cell sarcoma of the right pharynx and nasopharynx, confirmed by microscopic examination after incisional biopsy by Professor Tiedemann of the Jewish Hospital, St. Louis. Sections were also examined independently by the pathology departments of Washington University and St. Louis University. Dr. Lister Tuholske stated, and "by three of our ablest pathologists". Sections were sent to Dr. W. B. Coley, who had them examined in New York by Dr. James Ewing of Memorial Hospital, who confirmed the diagnosis.(67)

PREVIOUS HISTORY: M.B., male, aged 28, of St. Louis, Missouri. The family history was negative for cancer or venereal disease. The patient's father had died of chronic alcoholism, one brother of tuberculosis. The patient did not have a tendency to colds or sore throat, nor did he have bad teeth. He did not remember having had any childhood diseases. He was married at 19 and had one son born about a year later. There was no history of antecedent local trauma or infection in the nose or throat. When first seen by Tuholske, having been referred by Kaplan, the patient had a tumor of the right pharynx and nasopharynx of such size that it caused almost complete obstruction. A tracheotomy had been advised by Kaplan. This did not seem to be immediately necessary, so after determining the nature of the tumor, following biopsy, Tuholske decided to try Coley's toxins, as the growth was inoperable because of its size, location and involvement of the surrounding tissues. He had become familiar with the method while at the Augustana Hospital in Chicago, under Drs. Albert Ochsner and Nelson Percy.

TOXIN THERAPY (Parke Davis XII): Tuholske sent for some toxins directly from the main office of Parke Davis & Company and began the injections in May 1915. However, in spite of massive doses, apparently given intramuscularly, remote from the tumor, he was unable to get any reaction whatever. After a few weeks' trial, he wrote Coley and told him of his unsatisfactory experiences with this preparation.

SERIES A, INOPERABLE SUCCESSES, DETAILED HISTORIES

TOXIN THERAPY (*Tracy XI*): Coley then sent a supply of Tracy's XI. The first injection of this product caused a very violent reaction: chills and a high fever, as well as necrosis in the center of the tumor. The patient was treated at the Jewish Memorial Hospital. Between May 15 and June 23, injections were given daily or every other day in doses of $3\frac{1}{2}$ to 15 minims. The details as to the febrile reactions elicited are not recorded except on two occasions, when the temperature was 102.5°F and 103°F. Tuholske stated that within six weeks the extensive growth had entirely disappeared. The patient was discharged from the hospital on June 28, 1915, feeling perfectly well. The injections were continued twice a week for another two months, and then the patient left the city.

CLINICAL COURSE: Sometime during the autumn a recurrence developed on the other side of the pharynx. The patient did not return until November 11, at which time there was a good-sized tumor apparent. He was immediately readmitted to the Jewish Memorial Hospital. Examination revealed that the left pupil was slightly smaller than the right, with a tendency to a rectangular shape. Both pupils responded well to light and accomodation. There was partial paralysis of the left abducens nerve. The patient could carry the eye outward about 30 degrees. The fundus and discs were normal in outline and color.

FURTHER TOXIN THERAPY: Tuholske resumed the injections on November 13, 1915, giving 15 minims daily for a week, without getting any reaction, either local or general, and the tumor continued to grow rapidly. On November 18 he wrote Coley asking if intratumoral injections would be advisable. (Whether any were given is not evident from the subsequent correspondence.) On November 30 Tuholske again wrote, stating that he was very happy to report that in the preceding two weeks a very remarkable improvement had been evident. Prior to November 15 injections had been made into the patient's arm, except for the first which was made into the back and which was so painful that the patient pleaded that further treatments be given in the arms so that he could lie comfortably on his back. As the arms became somewhat indurated, Tuholske felt that this induration interfered with the proper absorption of the toxins, for they failed to act. On November 16, therefore, he began giving the injections into both thighs, on alternate days, and also into the superficial layers of the abdominal wall. These produced quite severe reactions and a wonderful improvement after only two weeks. The injections were continued about every other day until the last week in January, or almost three months. By this time all manifestations of the sarcoma had disappeared except the abducens nerve paralysis, which was supposed to be due to sinus involvement.

CLINICAL COURSE: About January 25, 1916, the patient began to vomit and was drowsy most of the time, becoming irrational at night. There was no elevation of temperature. His kidneys and bowels continued to function normally, but he gave

SERIES A, INOPERABLE SUCCESSES, DETAILED HISTORIES

the impression of being in a toxic state. No injections of toxins were given during this period, and only such nourishment as he was able to retain: glucose proctoclysis, hypodermoclysis and neutral camphor, and stimulants: strychnia and digitalis. The patient remained in a coma for 3½ weeks, during which time the temperature frequently remained as low as 95°F. for hours at a time. Tuholske held little hope for his recovery. During the worst period early in February the patient weighed only 89 pounds. By the last week in April he had gained 28 pounds, and he was then discharged from the hospital. A careful examination of the nose and throat by Kaplan, the laryngologist who had referred the case, failed to reveal any abnormalities, barring scars. The patient's speech, hearing and sight were normal. The paralysis of the left abducens nerve had cleared up and the movements of the eye were normal. Tuholske reported: "The period of one month was a perfect blank to the patient: he had no recollection of what had happened except that he fell asleep, worrying about his tumor, and when he woke up it was gone." (67) The patient also stated that when he returned to consciousness he noted a considerable change in his skin: it was dry and scaly, and there was no hair below the neck, and the testicles were considerably atrophied.

One interesting feature regarding this case was the polyuria, which Tuholske was unable to account for. The patient passed an average of 6,700 cc. of urine in 24 hours for about six weeks, the specimens showing nothing abnormal except occasionally a few pus cells and a trace of albumen. About May 1916 the patient returned to Tuholske, who found a suspicion of a small swelling just below and posterior to the left mastoid process, with no palpable nodes. This was considered as possible localized edema. No biopsy was made, but about six doses of x-ray therapy were given, with complete disappearance of the swelling. Tuholske stated that in 1918 the patient was presented before the St. Louis Surgical Society and a report of the case was then read. (67)

The patient was admitted to the Jewish Hospital on July 16, 1930. Examination at this time revealed that the skin was pasty and waxy and the testicles were almost completely atrophic and pubic and axillary hair growth had not been restored: there were only a few fine hairs on the pubes and scrotum. The hair on the face and scalp had not changed much, except possibly for a decrease in amount and a finer texture. The patient stated that since his illness in 1915 he "felt chilly all the time, needing plenty of covers except in hot weather". He rarely perspired on the palms, and he had evanescent swellings of the hands, face and feet. The facial features were small, the chin rather receding. The atrophy of the testicles was associated with several of the symptoms of hypothalamic pathology. Dr. Louis Cohen, an endocrinologist, then tried various preparations of male sex hormones, pituitrin, thyroid, etc. for about a year, but without any apparent effect. The patient discontinued treatment of his own accord, because he felt that the treatment was more of a nuisance than the symptoms for which he was being treated, and to which he had grown quite indifferent. (10)

SERIES A, INOPERABLE SUCCESSES, DETAILED HISTORIES

Tuholske examined him again 1942 and found a mild hypertension of which the patient was not aware. The symptoms of hypothalamic pathology still persisted at this time. He was again seen in 1946, at which time Tuholske reported: "He has a moderately advanced arteriosclerosis, as a result of which he had a slight hemiplegia last year (1945) from which he recovered. He has recently been at work daily. (10) The patient died of coronary occlusion and arteriosclerotic heart disease on November 23, 1948, at the age of 63. This was 33 years after his recovery from sarcoma of the pharynx and nasopharynx with hypothalamic metastasis following toxin therapy.

COMMENT: This history deserves careful study because it emphasized several important points regarding toxin therapy: (a) the difficulty of obtaining favorable results with a weak preparation (Parke Davis XII) —no effect whatever was noted, even with massive doses; (b) the danger of stopping the injections too soon, even though the neoplasm may have regressed completely; (c) the important role that the site of injection plays in determining success or failure; unless absorption is rapid and complete, a good result may not be obtained even with a potent product; (d) this patient appears to have had a brain metastasis, as evidenced by the abducens nerve paralysis and the coma. No other case has been found in which brain metastases was present and regressed completely following toxin therapy.

It is now apparent from Coley's correspondence files and records that he used the Buxton or Tracy preparations in the majority of his own cases, and was therefore not fully aware of the comparative weakness of the commercial products. After hearing of Tuholske's experience he wrote the Director of the Parke Davis & Company Research Laboratories, asking him to get in closer touch with Tracy, and urging him to make their product conform to Tracy's standards. As a result it was found that Parke Davis had been taking the nitrogen determinations (Kjeldahl method) before heating the toxins for sterilization, while Tracy had been taking them after sterilization. This one factor apparently made Tracy's product at least 10 per cent more potent. Other differences were also discovered.

This experience of Tuholske in treating the above case indicates many of the reasons why physicians became discouraged with this method: most of them used only the commercial product, whose weakness had not been appreciated fully even by Coley himself. The details of technique of administration as regards the best site, dosage, frequency and duration of treatment, adjusted to each type of neoplasm, and the age and condition of the patient, had not been properly studied or taught, yet good technique was as important as the need for potent products.

It is now apparent that in order that toxin therapy may produce the highest

SERIES A, INOPERABLE SUCCESSES, DETAILED HISTORIES

percentage of permanent cures, the techniques of preparing and administering the toxins should be carefully studied, and there should be closer cooperation between the research bacteriologists and the pharmaceutical laboratories who prepare the material, and the physicians who administer it.

REFERENCES: 10; 67; 139, Case 23

CASE 57: Recurrent small round cell sarcoma of the gluteus maximus muscle, confirmed by microscopic examination after operation by Dr. George E. Follansbee in Cleveland, Ohio.

PREVIOUS HISTORY: Mrs. D.M.W., aged 23, of Bedford, Ohio. The patient's mother died of sarcoma originating in the calf of the leg, at the age of 41, one year following onset. She was also treated by Follansbee (amputation), but received no prophylactic toxin therapy. Metastases developed in the neck, spine and sacrum, and six months after amputation she died. The patient's maternal aunt died of intra-abdominal cancer. A paternal aunt died of tuberculosis. The family history was otherwise negative except that three relatives were subject to hay fever. The patient had the usual diseases of childhood, many colds and severe attacks of tonsillitis, but no hay fever, asthma, boils or skin eruptions; she had a very clear complexion always, even during adolescence. When she entered high school at 14 she was small and immature, weighing only 74 pounds. She stated that when she was about 16 she complained of her left leg because it was sore and stiff after exercising. The family physician at that time was consulted and stated that "there was nothing wrong, that she imagined it". Menses began at 16, and the flow was regular but profuse. The patient was married on February 11, 1914, at the age of 21. Her normal weight was 125 pounds at this time, her height 5 feet 2 inches. She had bruised the left buttock about ten years previously, but had no trouble with it until onset, in 1913, when a swelling developed in this region. For the next three years the lump slowly increased in size, and motion in the hip-joint steadily diminished. After the birth of her first child, a son, in October 1915, the patient did not regain her strength. She lost weight and felt terribly tired. (The child was born with a double hare lip and cleft palate, and died a month later—a severe psychic trauma to the patient.) About January 4, 1916 a severe, boring pain in the leg woke the patient at night. She could hardly move the left hip enough to put on her shoes, and there was severe pain if the growth was touched, or on moving the joint. At this time she weighed 88 pounds, 35 pounds less than she had prior to onset.

SURGERY: On January 7, 1916, Follansbee removed the tumor, which weighed about 24 ounces. He found it to be without a capsule of any kind, and bleeding was very free. When the dressings were removed at the end of 10 days there was

SERIES A, INOPERABLE SUCCESSES, DETAILED HISTORIES

a recurrence as large as an egg in the upper end of the scar. The patient was then referred to Dr. W. B. Coley.

TOXIN THERAPY (Tracy XI): Injections were begun by Coley at Memorial Hospital on February 1, 1916, and were continued every other day for three weeks. The first injection was made directly into the tumor. Thereafter they were made in the region of the growth but not directly into the tumor tissue. Coley stated: "The tumor began to decrease in size after the third injection and continued gradually until no evidence of growth remained at the end of three weeks. The patient could lie on the affected side and move the left leg more freely than she had done for months." She then returned to Cleveland and a week elapsed in which no injections were given. On March 1, 1916 an enlargement was noticed on the inner side of the thigh at about the level of the incision, and apparently located in the adductor muscles. Follansbee injected $5\frac{1}{2}$ minims into this recurrent mass on that day, with about the usual reaction. Three days later this mass had increased to the size of a hen's egg. It was very hard and tender. He then injected $6\frac{1}{2}$ minims directly into the mass, with no reaction. The next day the growth was almost double in size. The recurrent tumor became almost as large as a grapefruit and took about three months to absorb. The patient stated that "under continued treatment it burst, leaving a hole in my leg about the size of a dime which discharged for about four days, and then closed up." From March 16 to May 9, 1916, injections were made about twice weekly. At times the local reactions were very severe, causing a great deal of swelling and pain. At other times they were very slight and the general reaction was quite severe, with a temperature of 105°F. to 106°F. During May a rest period was given. (This was three months after injections were begun.) Coley received word from Follansbee on June 12, 1916 that the patient was entirely free from any indication of the disease and that she had gained weight and felt very well indeed. She wrote Coley at this time: "I am feeling splendid and have gained over ten pounds in about three weeks. My strength seems to have come back so rapidly, and with it a good appetite." Follansbee resumed treatment in June, using Tracy's filtrate (Type XI F). Two injections weekly were given, either in the gluteal muscles or sometimes in the muscles surrounding the site of the former growth, and they produced no reaction. They were continued until October 1, 1916, a total duration of eight months. During the entire period of treatment the patient did not menstruate, although before and after treatment the periods were regular.

CLINICAL COURSE: She remained well and free from recurrence. She had four more children, all "bright and above average and of rugged health". She was followed periodically by Coley until his death in 1936. Menopause began at the age of 45 in 1938 and was "difficult, with extreme exhaustion and severe flooding, lasting about six years". The patient was examined at Memorial Hospital by Dr. Walker E. Swift, on January 27, 1943. He reported: "She has been in fine condi-

SERIES A, INOPERABLE SUCCESSES, DETAILED HISTORIES

tion, no swelling of the leg. No impaired function of hip or knee. No pain." On April 19, 1944, she was presented at the Annual Meeting of the American Society for the Control of Cancer in Cleveland by Follansbee, as a 28 year survival. On April 12, 1947 she reported that she had been having some arthritis in her hands, elbows and joints, and that at times her thigh caused some discomfort, which subsided after resting in bed. She was otherwise in excellent health. During the following year she developed a persistent cough and lost 17 pounds. A chest x-ray revealed no evidence of disease. In January 1949 she developed a streptococcus infection of the throat, and erythema multiforme, being quite ill for seven weeks. She stated that "It seemed to affect the bad leg a good deal . . . (with) aches, pains and extreme nervousness". On November 26, 1950, she reported that in the preceding year she had not been too well, "nothing serious, but annoying. A severe bronchial cold which hospitalized me for six days revealed a sinus condition that had not been recognized, bad dizziness and trouble with my eye-sockets. Penicillin did not help me. Arthritis in my hands is annoying me, too. I have to rest more . . . no loss of weight." She reported on September 17, 1951, that she was very well and able to do her own work. She added: "The sinus and vertigo all cleared up and it has not been necessary to visit or call a doctor for a year." Her weight in 1949 increased to 150 pounds, and this extra weight seemed to bother the leg a good deal. She then reduced to 138 pounds. In June 1952 she broke her ankle. The limb was immobilized in plaster for seven weeks. Thereafter her health remained good until the spring of 1954 when she began to have lower abdominal cramps and non-disabling but somewhat bloody diarrhea. This continued and in March 1956 barium enema and x-rays revealed ulcerative colitis. She was hospitalized four weeks at University Hospital. Cortisone was given. The patient did not improve, but became seriously ill. She was admitted to the Cleveland Clinic on June 29, 1956 with a fulminating toxic ulcerative colitis with impending perforation of the colon. The entire colon and rectum were involved. There was persistent high fever and a rapid pulse and the colon was rapidly distending. She was quite toxic and unresponsive.

SURGERY: A diverting ileostomy was performed June 30, 1956. She became progressively worse and on July 2, 1956 Dr. R. B. Turnbull performed a subtotal colectomy with mucosal graft and ileostomy. The patient was disoriented and febrile for a few days but improved enough to be discharged in two weeks.

CLINICAL COURSE: Her course since then was one of rapid and progressive improvement. Turnbull reported that she was "quite well in all regards" on February 26, 1957, and that physically there was no evidence of the previously treated sarcoma. Her husband retired and in 1961 they moved to North Carolina. The patient remained in good health and able to do her housework. Her recurrent regional ileitis later became intractable, with fistula formation into the bladder and rectum. She returned to the Cleveland Clinic early in 1968 for surgery. Dr.

SERIES A, INOPERABLE SUCCESSES, DETAILED HISTORIES

R. B. Turnbull removed some of it but it was too extensive, and she expired at the age of 73, 55 years after onset of her sarcoma. Autopsy revealed no evidence of malignancy.

COMMENT: This case seems to indicate the danger of suspending toxin therapy during the early weeks, even if the tumor has apparently disappeared. It also encourages the persistent use of toxin therapy in recurrent tumors, even when the growth seems to be out of control.

REFERENCES: 10; 67; 128; 139, Case 24

CASE 58: Recurrent inoperable sarcoma of the scalp, confirmed by microscopic examination at Mercy Hospital, Pittsburgh, Pa.

PREVIOUS HISTORY: Female, about 20. The family and previous personal history are not recorded. The patient developed a tumor of the scalp which was excised by Dr. J. J. Buchanan at the Mercy Hospital, and reported as sarcoma. A local recurrence rapidly developed.

TOXIN THERAPY (*Tracy XI*): Injections were then administered by Dr. H. H. Donaldson, of Pittsburgh, beginning with a dose of .5 minim, which was increased daily by .5 minim until a reaction occurred. The injections were continued for over four months. Shortly after the first febrile reaction the recurrent tumor began to shrink in size, and within a month it had disappeared completely.

CLINICAL COURSE: The patient remained in good health and free from further recurrence when last traced over ten years after onset.

REFERENCES: 10; 193

CASE 59: Recurrent angiosarcoma of the cheek, of rapid growth, confirmed by microscopic examination by competent pathologists.

PREVIOUS HISTORY: Male, aged 2. The child developed a rapidly growing tumor on the right cheek. It was angiotic in character, indurated and growing rapidly. It was excised, but within three weeks recurred and again grew rapidly. The recurrent growth was 2 cm. in diameter when the toxins were begun.

TOXIN THERAPY (*Tracy XI*): Injections were given directly into the tumor in small, increasing doses at from five to seven day intervals. There was very little febrile reaction, but the growth regressed steadily, and entirely disappeared in about 2½ months.

SERIES A, INOPERABLE SUCCESSES, DETAILED HISTORIES

CLINICAL COURSE: There was no further recurrence. The patient was last traced in 1943, about 26 years later, at which time he was serving in the United States Army in Europe.

REFERENCE: 10

CASE 60: Mixed cell sarcoma of the ovaries with extensive involvement of the intestines and pelvis, confirmed by microscopic examination after operation on January 29, 1920. Sections from numerous portions of the intestines and the tumor itself were examined.

PREVIOUS HISTORY: Mrs. M.M., female, aged 26. The family and previous personal history were not recorded. The patient consulted Dr. F. R. Calkins of Watertown, New York, in January 1920 for a large painless growth in the abdomen, of about five months' duration, which had been diagnosed as a pregnancy. The patient was a strong, healthy young woman, who had been married for four years, but who had not been pregnant. On examination Calkins found a large firm mass filling the entire pelvis, and extending up for a distance of about 8 cm. above the umbilicus. He made a pre-operative diagnosis of fibroid tumor.

SURGERY: On January 29, 1920, under ether anesthesia, Calkins operated through a lower median incision. A large degenerated tumor of the right ovary was found, also a double hydrosalpinx also undergoing degeneration, and a degenerated dermoid cyst of the left ovary about the size of an orange. An attempt to reduce the size of the ovarian cyst by aspiration resulted in failure, and the incision had to be enlarged to 7 cm. above the umbilicus. Large masses of cauliflower growth were encountered between the tumor, the cecum, the sigmoid flexure and the rectum. The appendix had taken on this new growth and was nearly as large as a good-sized cucumber. A bilateral salpingo-oophorectomy, a panhysterectomy and appendectomy were performed, but it was impossible to remove all the extensions of new-formed growth attached to the intestines. The patient made a good recovery from the operation.

TOXIN THERAPY (*Tracy XI*): One week later the injections were begun, and were given daily for the first six months and after that semi-weekly, with occasional intervals of rest for six months longer.

CLINICAL COURSE: The remains of the growth disappeared, and there was no recurrence or metastases. Seven years after treatment Calkins examined the patient and found her to be the picture of health, working every day. She was not traced subsequently.

SERIES A, INOPERABLE SUCCESSES, DETAILED HISTORIES

REFERENCES: 10; 67

PARKE DAVIS XII and XIII

The following ten cases were treated by the Coley toxins as prepared by Parke Davis & Company from 1907 to May 1915, Type XII, and from May 1915 to 1950, Type XIII. (The first Parke Davis product, Type IX, is discussed above.)

Apparently the toxins prepared commercially after 1906, even with the modifications suggested by Dr. Martha Tracy, continued to be much weaker than the products made by Tracy. This fact was brought out by letters from a considerable number of doctors, both here and abroad. (67) While these men realized something was wrong with the toxin preparation, undoubtedly a far larger number did not, condemning instead the fundamental principles of the treatment. In this way the natural reticence of physicians to embrace any radical new ideas was heightened by an increasing number of failures and even the reported successes were largely discounted. To illustrate:

Dr. W. E. Savage, of Cincinnati, Ohio, wrote to Dr. W. B. Coley on September 10, 1912, asking for some Tracy toxin (Type XI), stating: "I have used the commercial preparation without beneficial result."

Dr. G.N.J. Sommer, of Trenton, New Jersey, wrote on December 18, 1912, with a similar request. He stated: "I have never been able to get any results with the commercial product."

Dr. B.P. Weaver, of Fort Wayne, Indiana, wrote: "Is it not possible that the preparation as put out commercially is less virtuous than that put out by the Huntington Cancer Research Fund?" (Tracy XI)

Finally, after hearing of Dr. Lister H. Tuholske's unfortunate experience (see above, Case 56), Coley wrote on August 20, 1915 to Houghton, the director of the Biological Laboratories of Parke Davis in regard to the apparent weakness of the Parke Davis preparation. As a result of this it was found that Parke Davis had been taking the nitrogen determinations before sterilizing the cultures and that Tracy had been taking them after sterilization. From various experiments and comparisons made during September 1915 it was found that this one factor made the Parke Davis preparation weaker, as approximately .11 grams of nitrogen per cc. was driven off during sterilization. (Parke Davis & Company were not at fault because the formula which was originally given them by Tracy was not entirely clear on this point.) Houghton stated on October 19, 1915 that he felt this factor was the only one to which he could attribute variation in the two products.

SERIES A, INOPERABLE SUCCESSES, DETAILED HISTORIES

The subsequent correspondence indicates that Coley was not yet satisfied with the Parke Davis preparation, and on February 4, 1916 Houghton sent him a copy of the formula they were using at this time. This showed substantial variation from the formula used in the Tracy preparation, not only in the amount of *Serratia marcescens* used, but in sterilization procedures. The Tracy preparation was sterilized for two hours at 75°C. in a water bath, whereas after May 1915 Parke Davis sterilized the mixture in the autoclave at 120°C. for half an hour (Type XIII). (From 1907 to 1915 Parke Davis had sterilized the preparation in the same way as Tracy; two hours in a water bath.) It is now known that bacterial toxins are largely destroyed or altered by such a high degree of heat, and this factor may have been chiefly responsible for the weakness of the Parke Davis XIII toxins from 1915 to 1950.

In spite of efforts to improve the strength of the commercial products, such letters continued to arrive: Dr. J. J. Buchanan, of Pittsburgh, Pa., wrote on April 16, 1921: "For many years I used Martha Tracy's preparation of Coley's serum, always getting a reaction with the minimum dose. Dr. T. informed me some time ago that she no longer made the same serum, but that it could be had from a commercial biological laboratory. I secured some last week for a patient in Ohio . . . and have had no reaction up to 3 minims. I am, therefore, in doubt as to whether this preparation is efficient."

On January 13, 1923 Dr. M. F. McGuire, of Montpelier, Vermont, wrote in regard to an inoperable sarcoma of the neck: "I gave eight drops of the commercial preparation without a single mark of reaction. From the literature of the toxin treatment I judge I should have had before this a definite chill and, as she is taking eight minims to a dose, I feel the solution is not good."

It is unfortunate that the weakness of this preparation was not clearly recognized at this time, so that the dosage could have been increased or the formula modified.

Problem of Maintaining Virulence of Streptococcus: In his constant efforts to improve the toxins, Coley in 1931 became concerned over the degree of virulence of the streptococcus cultures used in the preparation of the toxins, for he remembered how very vital this factor had been in the early success of the method (1893-95). At that time Lambert and Buxton succeeded in increasing the virulence by passage through a large number of rabbits in a short period of time. They found that cultures so treated would kill a mouse in 24 hours, in a dose of 0.000001 cc.

Clark wrote that the streptococcus culture being used during 1931 was the same one originally sent from the Mayo Clinic on January 21, 1922 (obtained

from a case of erysipelas), that it had been passed through white mice every other week regularly for 11 years and that it had consistently killed white mice in a dose of 0.01 cc. in an 18-hour broth culture. Occasionally they tested the strain in higher dilutions and found that it would kill white mice in dilutions of 0.001 cc. of an 18-hour broth culture.

Methods of Sterilization: Coley wrote again on November 11, 1935 in regard to the possibility of improving the toxins by better methods of sterilization. This had been suggested by his son, Dr. Bradley L. Coley. At this time Clark of Parke Davis condemned the Krueger method, because by this process only the endotoxins are preserved and he stated that this fraction is known to be lower in antigenic principle than either the unwashed bacterial cell or the "washings prepared by the method of Ferry and Horder."

Beebe and Tracy recognized the advantage of concentrated suspensions of the streptococcus cultures. In their special experiments on the effects of various bacterial products on lymphosarcoma of dogs in 1907 they used centrifugation to produce more concentrated suspensions and the results were definitely superior to the regular method. (4) However, this desirable modification was not incorporated in Tracy's formula as sent to Parke Davis & Company, although Tracy herself may have used it in making her preparations (Type X and XI).

Clark further stated in his letter of November 19, 1935 to Coley: "In view of the data accumulated both clinically and from the laboratory standpoint in support of the principle developed by Ferry and Horder, coupled with the fact that your toxins represent the unaltered suspension of the two species, which is known to be second only to the "washings" in antigenic activity, we certainly would not be in favor of jeopardizing a product such as yours, which has stood the test of time, by introducing modifications which we are unable to verify." (67)

Variation in results obtained: In attempting to analyze the reasons for variation in results obtained by toxin therapy, Coley considered the importance of technique of administration, as well as methods of preparing the formula. This point was discussed in 1929 by Coley in one of his papers, as follows:

"Another factor that may throw some light upon the difference in the earlier and late results obtained, is that during the first eight or ten years I made nearly all the injections directly into the tumor, thereby obtaining much more severe and more certain reactions than are produced by intramuscular injections. After having obtained a cure in a considerable number of cases of inoperable sarcoma of inaccessible regions by injecting remote from the tumor, chiefly in the buttocks and pectoral region, I became convinced that local injections were unnecessary and so abandoned them. However, there is one distinct disadvantage

SERIES A, INOPERABLE SUCCESSES, DETAILED HISTORIES

in intramuscular injections, namely, that usually a week is required before marked reaction is produced therefrom . . . Another disadvantage is that intramuscular injections may cause local induration and discomfort."

In November 1935, in replying to the above-quoted letter from Clark of Parke Davis, Coley reiterated this point and added that in the last few years he had again been using intratumoral injections "with better results."

He then noted another possible reason why the results obtained with the earlier product of Buxton VI might have been more effective than in the later years with the Parke Davis XIII:

"The only explanation I can offer is that these (early) cases were treated with toxins prepared according to the original method, i.e., the prodigiosus was grown with the *Streptococcus erysipelas* in the same broth . . . and later the cultures were killed by heat, 58°C. and preserved by thymol."

"Later on, in order to standardize the dose (there had always been an exceedingly variable rate of growth), Tracy conceived the idea of growing the two organisms separately and then adding a certain amount of the *B. prodigiosus* to the streptococcus. That is the method we turned over to you and which you have been using ever since. However, this method does not take advantage of the original idea for which I began using the prodigiosus, based on experiments of Roger, of the Pasteur Institute. He claimed that by growing the prodigiosus with the streptococcus the virulence of the latter was greatly intensified. If there is anything in that idea, it is lost in the Tracy modification."

Clark replied: "I think your suggestion is quite worthwhile, particularly as we know full well that symbiotic relationship is much stronger when the organisms are associated during their proliferating stage than is to be expected from a combination of the by-products of those species." (67)

A small amount of this "special preparation A" was prepared and forwarded to Coley, but unfortunately it arrived too late for a personal trial as he died shortly thereafter (April 1936). Apparently it was not used by any other surgeon.

The Problem of Deterioration or Perishability: Concerning the length of time which the Coley toxins are supposed to remain active, Clark, Director of the Parke Davis Laboratories, wrote Coley in October 1912: "We would like to ask if you have determined wherein Coley's Mixture is different from the bacterial vaccines with which we are now dealing. As you know, it has been determined by more than one investigator that bacterial vaccines will remain active two or three years when

SERIES A, INOPERABLE SUCCESSES, DETAILED HISTORIES

stored under ordinary conditions. If this is true of bacterial vaccines, to what extent can such data be applied to the keeping qualities of your product?"

He wrote again on January 7, 1915: "... Because of some experience several years ago in which it would seem that the product deteriorated rather rapidly, we adopted the plan of endeavoring to see that the consumer never had any product that was over three months old . . . We are glad to know that your experience has allowed you to draw the conclusion that it would keep for at least six months."

Houghton, of Parke Davis & Company, wrote Coley on September 27, 1917: "The question has (again) arisen relative to the perishability of your product . . . We put it out at the present time with a dating of three months from the date of manufacture and feel that the product should be considered as a perishable one."

Problem of Local Irritation: In August 1915 Coley wrote to Parke Davis in regard to the increased local irritation he had noted resulting from toxins recently sent him. The Parke Davis bacteriologists did not understand what caused this increased irritation.

We know that in March 1915 the following changes were made in the formula used from 1907-1915: (1) Streptococcus cultures were grown in 1 litre flasks instead of 6 litre flasks. (2) The virulence of the streptococcus culture was maintained by passage through rabbits every two weeks. (3) Pigment-producing cultures of *Bacillus prodigiosus* were specified. (4) After mixing the two cultures, they were heated for 30 minutes in the autoclave, instead of two hours at 75°C. in a water bath. Tracy stated that possibly this excessive heat caused certain chemical changes in the toxins or the thymol or glycerine which may have caused greater irritation in the Parke Davis preparations. As regards this factor, another physician, Dr. G. S. Forster, of Manchester, New Hampshire, wrote on May 20 and June 7, 1923, stating: "I have for several years used Coley's fluid with considerable success and have had several cases that gave satisfactory results." (He had used Tracy XI, but later he obtained the commercial preparation.) He added that he never used to hear the patients complain of local irritation or pain until he used this latter product, and that the same technique was used with both preparations. This may be a significant point because the greater irritation produced at the site of injection may prevent prompt absorption of the toxins and there by their effect may be weakened. (This factor would not be noticeable when using the intravenous or intratumoral routes.)

The above summary of some of the problems connected with preparing and administering Coley toxins has been presented here so that present and

SERIES A, INOPERABLE SUCCESSES, DETAILED HISTORIES

future investigators may have the facts in accessible form. This summary is based on an analysis of the correspondence between Dr. W. B. Coley and Parke Davis & Company (1900 to 1936), thousands of letters from physicians using the method here or abroad (1893-1958) and over 1,000 detailed histories of cases treated by the various preparations of the Coley toxins.

REFERENCES: 4; 10; 67; 87; 128; 193

CASE 61: Inoperable round cell sarcoma of the abdominal wall, confirmed by microscopic examination at the Jewish Hospital, Brooklyn, New York.

PREVIOUS HISTORY: Male, aged 55. An exploratory operation was performed by Dr. Paul M. Pilcher of Brooklyn, and the condition was found to be inoperable. A specimen was removed for histological examination.

TOXIN THERAPY (*Parke Davis XII*): Injections were given by Pilcher for four months. There was gradual and complete disappearance of the growth. The patient gained 20 pounds in weight.

CLINICAL COURSE: He remained well and free from recurrence when last traced, over five years after treatment.

REFERENCES: 51, Case 97, p. 165; 67

CASE 62: Inoperable small round cell sarcoma of the axilla, confirmed by microscopic examination at the Augustana Hospital, Chicago, Illinois, following incomplete removal.

PREVIOUS HISTORY: Mrs. V. H., Female, aged 17. The family history was noncontributory. The previous personal history was non-contributory until onset, in early February 1910, one month prior to admission, when the patient began to complain of pain in the right shoulder, especially when lying on the right side. She was admitted to the Augustana Hospital on March 10, 1910. Examination at this time was negative, except for a mass in the right axilla. The superficial vessels over the tumor were dilated and tortuous, the skin tense, dry and somewhat discolored.

SURGERY: Dr. Edward O. Ochsner, of Chicago, operated the next day. A tumor about the size of a grapefruit was excised, but it had so completely surrounded the axillary vessels and nerves that not all of it could be reached. The upper outer fourth of the mammary gland and portions of the pectoralis major and minor

SERIES A, INOPERABLE SUCCESSES, DETAILED HISTORIES

muscles were also removed. The wound was closed, and a split rubber and two cigarette drains were inserted through a stab wound. The post-operative course was uneventful.

TOXIN THERAPY (*Parke Davis XII*): Injections were begun about two weeks after the operation. They were made into the deltoid muscles every five or six days. Febrile reactions, varying from 102° to 105°F., were produced but only one chill occurred. The injections were continued for about six months. The remains of the growth regressed and the patient made a complete recovery.

CLINICAL COURSE: She was examined periodically by Ochsner, and remained free from recurrence. She married and had a son and two daughters. She was last traced in excellent health on December 18, 1946, over 36 years after onset and toxin therapy.

REFERENCE: 10

CASE 63: Inoperable angiosarcoma of the mediastinum, confirmed by microscopic examination by Dr. F. S. Mandelbaum, Pathologist of Mount Sinai Hospital. Dr. James Ewing also examined the sections and reported: "Malignant cellular tumor of embryonal type, composed of many blood sinuses lined by two or more rows of tumor cells. Very delicate stroma." He regarded it as an extremely malignant form of tumor. (115)

PREVIOUS HISTORY: P.H., female, aged 22 months, of New York. The family history was negative for cancer, tuberculosis or venereal infection. The maternal grandfather developed diabetes at the age of 60 or 65. There was no history of antecedent local trauma. The child had been normal at birth, weighing nine pounds. She was breast fed for 10 months and walked at 16 months. She had gained slowly in weight although there had been frequent green diarrheal stools. At the age of five months the mother noticed that the child's breathing was distinctly labored, but the family physician found nothing wrong with the lungs. For two months there was respiratory disturbance without cyanosis or other sign of deficient aeration. The child was pale and heart action was often rapid. At the age of eight months the mother noticed a "lump on the right shoulder blade" while bathing the child. She took her to the Babies Hospital where a roentgenological examination was made. This was reported as showing "a large roughly quadrilateral, dense shadow in the lower part of the right chest, extending over the heart, also the left chest and down over the liver shadow. Right chest above this appears free from lung tissue. The right diaphragm appears free from lung

SERIES A, INOPERABLE SUCCESSES, DETAILED HISTORIES

tissue. The right chest is smaller than the left. The right bronchus is not seen. Probably congenital atelectasis." The mother refused to leave the baby but took her to Lebanon Hospital where fluoroscopic examination was made, on April 30, 1923. This revealed "a dense shadow, homogeneous in character, sharply circumscribed, ascending apparently from the lower mediastinum, and projecting to the right. The mass is the size of a small orange; its lower border projects slightly to the left of the median line and is overshadowed by the heart. The appearance is either that of a cyst or a neoplasm ascending from the mediastinum." A puncture was made which produced sterile, bloody, noncoagulating fluid. The Wassermann, blood and urine examinations were all negative. An exploratory operation was suggested but refused by the child's mother, who took the patient home. At 20 months tonsillitis developed and the child was taken to Beth David Hospital where another roentgenological examination corroborated the former findings. On March 16, 1924, when the child was 21 months old, she suddenly stopped walking because of weakness of the right lower extremity, which became rapidly progressive. At first she was able to stand, but the right foot turned out and she fell on attempting to walk. She was first seen by Dr. Alfred W. Pollak at this time, at the Hospital for Joint Diseases. He noted that the patient was a bright, well-nourished child, without fever or pain. There was great weakness of the lower extremities: total inability to stand because of paresis of both legs. There was a mass between the scapula and the spine, with dullness on percussion. Breath sounds were exaggerated anteriorly. A blood examination was reported as follows: hemoglobin, 42%; erythrocytes, 3,200,000; leukocytes, 14,000; polymorphonuclears, 42, small lymphocytes 13; transitionals, 1; eosinophiles, 3. Urinalysis was negative. Roentgenological examination at this time was reported: "cyst, lower right chest; pressure erosions, spine and rib, esophagus is displaced anteriorly" (115, p.616-618 for roentgenograms) Dr. Howard Lilienthal was called in to see the case on April 12, 1924, a month after she had stopped walking. He found both legs flaccid and obviously paralyzed. There was a protruding subcutaneous mass covered with normal skin between the right scapula and the spine which was firmly elastic. The child's general condition was good.

SURGERY: On April 15, 1924, Lilienthal operated at Mount Sinai Hospital. He resected about 4 cm. of a rib subperiosteally over the tumor. He then aspirated a minute quantity of thick, bloody fluid. The posterior mediastinum was then opened and the capsule of the tumor exposed. This was incised so as to admit the index finger. The wall was tense and the tumor rudely spherical. A large part of the contents was removed with the finger, consisting of grayish-red, soft neoplastic tissue, the total amount removed being a little greater than the bulk of a golf ball. The oozing cavity was packed with iodoform gauze. The pleura was not entered. Lilienthal then suggested toxin therapy.

TOXIN THERAPY (*Parke Davis XII*): On April 25, ten days after this operation,

SERIES A, INOPERABLE SUCCESSES, DETAILED HISTORIES

injections were begun by Pollak. The initial dose was 1/25 of a minim, the site being the gluteal muscles. This was followed by a severe reaction. For 11 days the injections were given daily, increasing the dose to a maximum of 4½ minims. The febrile reactions ranged as high as 106°F. Further injections were refused by the patient's mother, because of the severity of the reactions. Pollak's observations as to the effects of toxin therapy are of value: He stated that the intensity of the reactions had been very great, and added: "*From the very first the healing of the operation wound was extraordinary, and after the third injection the progress of the healing was even ten-fold quicker than before, and after the reaction was over the child seemed to be better generally.*" The hemoglobin count was 42% at the time of the operation and after the eleventh injection it went down to almost 30%. Because of the violent reactions the mother requested that the injections be stopped, at least temporarily, and Dr. Lilienthal thought this might be done without ill effect and a transfusion be given. While the advisability of giving a transfusion was being considered, the improvement in the patient's condition became so marked that matters were allowed to stand as they were, and in a comparatively short time the child was up and around." She began to walk within three weeks from the first injection, relief being due apparently to decompression. (115)

CONCURRENT INFECTIONS: During the summer immediately following toxin therapy, the child developed a very severe case of pertussis, there being as many as 14 violent paroxysms in one afternoon. During this time roentgenograms were taken of the lungs to see if they were affected, but the picture was negative. A severe attack of measles, and then bronchitis followed the pertussis, but the child recovered without any ill effects. It is possible that the severe attack of pertussis, as well as the measles and bronchitis may have produced toxins which helped to continue the process of regression of the neoplasm. The possible effects of contagious diseases other than tuberculosis on malignant tumors in man have not been seriously considered until rather recently. (142) However, several investigators have reported the inhibitory effects of concurrent contagious diseases on tumors in mice or rats. (178) Bashford was one of the first to note that mice convalescent from contagious diseases are refractory to tumor transplants. (85)

CLINICAL COURSE: The patient's condition continued to improve and a series of x-ray pictures taken by Dr. H. B. Philips showed the gradual regression of the tumor mass during the next two years. On September 19, 1926, Philips reported: "The irregularity in contour and diminution in size indicates a partial collapse of the tumor. There appears to be considerable regeneration of the posterior ribs, which previously showed marked pressure erosions and considerable regeneration of the resected portion of the eighth rib has taken place." A month later, roentgenological examination showed a normal chest. In February 1928 Dr. Leopold Jaches examined the patient's chest and reported: "No evidence of abnormality in the lungs, diaphragm, heart and aorta. The eighth rib shows

SERIES A, INOPERABLE SUCCESSES, DETAILED HISTORIES

evidence of previous resection, but it has regenerated almost completely." (film No. 11, 846) The patient remained in perfect health and was seen periodically by Pollak and Lilienthal during the next 21 years. She was presented at various medical meetings by Lilienthal, who on one of these occasions stated: "This is not the first time I have noted a continuance of the regression in cases of malignancy after the treatment with Coley's toxins had been discontinued. My experience with this form of therapy in a number of other instances has been so favorable that I would strongly recommend its use in inoperable sarcoma and also a prophylactic post-operative treatment after surgical removal of operable tumors as well."

The patient had her first child, a son, in the summer of 1949, a perfectly normal pregnancy and confinement. Her second child, a daughter, was born in March 1953. Her only complaint during the years following her marriage was a low basal metabolism (minus 25) and that she was over-weight: she weighed from 155 to 165 pounds and was 5 feet 3 inches tall. She was last traced in very good health, having never had any recurrence, or metastases, on September 15, 1975, 52½ years after onset of the sarcoma.

COMMENT: Pollak's observations of the apparently stimulating effect of the toxins on the rate of healing of the operative wound are of interest, as this effect was also reported by other surgeons using the method, and is apparent in many of Coley's cases, especially osteolytic bone tumors, where extensive areas of bone destroyed by the neoplasm completely regenerated following toxin therapy. (147)

REFERENCES: 10; 115; 132; 139, Case 28

CASE 64: Malignant myoma of the uterus, confirmed by microscopic examination by Dr. R. R. Simmons, of Des Moines (Iowa Methodist Hospital, Pathological Report #8890), and by Dr. J. E. McWhorter, Pathologist of the Hospital for Special Surgery, New York. Also skeletal bone metastases in the femur, pelvic bones and skull, confirmed by roentgenological examination by Drs. Herendeen and Duffy at Memorial Hospital, New York. (67)

PREVIOUS HISTORY: Mrs. E.A., female, aged 37, of Des Moines The patient had had measles, pertussis, influenza, tonsillitis and pneumonia (twice). One child, a son, was born when she was 19, a normal delivery. There were no other pregnancies. Three years after this child was born her appendix was removed at the Mayo Clinic, also adhesions were cut and a retroversion of the uterus was corrected. Four years prior to consulting Dr. David M. Blum, of Des Moines, the patient was

SERIES A, INOPERABLE SUCCESSES, DETAILED HISTORIES

in an auto accident sustaining internal injuries and indefinite head and skull injuries, but no skull fracture. Two years after this accident she had been examined and told she had a fibroid uterus. In July 1927 she consulted Blum because of weakness and a growing mass in her abdomen which had been noticed for four years. The tumor had varied in size during this interval, but had recently been of rapid growth, associated with attacks of weakness, anorexia and periodical bearing-down pains not unlike labor pains, occurring about every 20 minutes. There was also a dependent edema when she remained on her feet.

CONCURRENT GASTRO-ENTERITIS: Two weeks prior to observation she had an attack of gastro-enteritis, associated with pain, cramps, vomiting and diarrhea, without mucus or blood in the stool. After this attack she had been unable to digest her food, and vomited frequently.

CLINICAL COURSE: Two weeks prior to observation she also had a uterine hemorrhage while at stool (an estimated loss of a pint of blood), following which there was a "leukorrheal discharge while she was on her feet". There was unremitting pain in the lower lumbar region, and in the region of the right hip, unrelated to motion. There was also loss of weight, and a paroxysmal tachycardia at times. Physical examination was negative except that the sclerae were slightly yellow, the lips and skin waxy pale. The tumor of the lower mid-abdomen was the size of a full-term pregnancy and was somewhat fluctuating and very tender when touched, contracting at intervals like a mild labor pain. No fetal heart tones or bruit were heard. The extremities were somewhat swollen and edematous. Pelvic examination was negative except for an old laceration of the cervix, and ballooning out above the cervix in all directions, filling the pelvis, a soft, fluctuating, tender mass. Urine and Wassermann examinations were negative. Blood examination showed: hemoglobin 50%; red blood cells 3,240,000; white cells 15,400; 96% polymorphonuclears and 4% lymphocytes. While under observation, albumin and pus appeared in the urine and the blood count continued to fall; 35% hemoglobin, 2,030,000 red cells, and the differential count varied between 14 and 81% polymorphonuclears and the lymphocytes from 36 to 19%. Large lymphocytes were present to the extent of 18% on one occasion. There was variation in the size and shape of the red cells. X-ray showed the beginning of bone destruction around the lesser trochanter of the femur, and similar areas about the sacroiliac joint and the skull.

TRANSFUSION: *Two days prior to operation she was transfused with 500 cc. of whole blood, which caused general reaction with aching pains.*

SURGERY: On June 30, 1927, Blum operated, removing the uterus, which weighed 15 pounds. Upon section it showed a degenerated massive fibroid which was undergoing malignant changes and which had broken down so that *there was*

SERIES A, INOPERABLE SUCCESSES, DETAILED HISTORIES

considerable pus at the cervical end of the uterus. There were many adhesions about the uterus between the intestines and the peritoneum, which were separated. The ovaries were cystic and about the size of a small egg, and were left untouched. Recovery from the operation was uneventful but, due to the malignancy of the condition found in the uterus and the skeletal metastases, a hopeless prognosis was made. She was put on a liberal diet including green vegetables, liver, iron and hydrochloric acid.

TOXIN THERAPY (*Parke Davis XIII*): In view of the multiplicity of the metastases it was though inadvisable to submit her to x-ray or radium treatment, and so on July 21, 1927, the toxins were begun by Blum, the initial dose being 2 minims (four times more than Coley usually advised as an initial dose). This was repeated on the next day and on the 23rd of July she received 7 minims in the morning and 10 minims in the afternoon, but not until July 24, when the dose was increased to 15 minims was there a severe reaction, the temperature being 105°F. On July 25 she received 23 minims, on the 26th, 20 minims, on the 27th, 25 minims. Following the injections her temperature varied from 100° to 102.4°F. On July 31, 30 minims produced a temperature of 100°F., and on August 1 the final injection of 40 minims caused a temperature of 102.6°F. Only nine injections were given, but the amount at each dose was a great many times larger than Coley had ever given. Due to financial conditions the patient had to be transferred to the State Hospital, where no further treatment was given. At the University of Iowa further x-ray studies were made, which confirmed the diagnosis of multiple bone metastases, but no further treatment of any kind was given.

CLINICAL COURSE: The patient gradually regained her health and strength and returned to work, and by November 30 was well enough to motor 100 miles. She remained in good health, working as a stenographer when last traced in July 1933, six years after treatment.

DISCUSSION: This case indicates that even weak preparations of the toxins can produce permanent results if given in sufficiently large doses to compensate for their lack of potency. It is probable that Blum did not make very deep injections, for he reports the formation of several sterile abscesses in the buttocks which opened spontaneously and drained for several days. Evidently these large doses made in this way were absorbed slowly and a cumulative effect was produced sufficient to produce a permanent result. In analyzing this case it must be remembered that very few cases remained free from recurrence with such a short period of treatment. The effect on the disease of the toxins generated by the attack of gastro-enteritis just prior to operation should also be considered because apparently enteric organisms produce toxins of high tumor-destructive potency. The pyometra and the transfusion may also have had a beneficial effect.

SERIES A, INOPERABLE SUCCESSES, DETAILED HISTORIES

This case greatly impressed Coley, who compared it with the Marine Hospital case (11), and Lilienthal's case (115: see above, Case 63). In conclusion, Coley stated: "(these cases) lead me to wonder whether I have not been too timid in pushing the dosage to the limits of tolerance". (60)

Brooks and Thomason have reported a case of malignant myoma of the uterus with metastases to the upper left femur. In summarizing this case the writers stated: "Sarcoma of the uterus is a rare neoplasm, probably not occurring in more than one per cent of patients who are operated on for uterine fibromyomas. Metastases from sarcoma of the uterus are most common in the lungs, peritoneum, lymph-nodes, liver and kidneys. Little has been written concerning metastases of uterine sarcoma to bone. We were able to find only three cases reported, and we know of one questionable case through personal communication."

Their case did not conform with Evans' classification of uterine sarcoma as to the degree of malignancy according to the number of mitotic figures present. Their case would fall, according to his classification, in the class of Group III sarcomas, showing only a few mitotic figures, but clinical course of the patient proved the malignancy of the tumor.

REFERENCES: 10; 60; 67; 132

CASE 65: Recurrent reticulum-cell sarcoma, primary in the bicipital region, with metastases in the axilla and the abdominal wall, confirmed by microscopic examination in December 1953 by Dr. Henry L. Jaffe, Director of Laboratories, Hospital for Joint Diseases, New York. (10) See below for the reports of pathologists in 1928-1935.

PREVIOUS HISTORY: L.V.McN., male, aged 26, of Hattiesburg, Mississippi. The patient had measles, mumps, chickenpox, whooping cough and typhoid as a child. He was a strong, healthy man. Onset, in November 1927 he developed a small growth in the right bicipital region which was excised by Dr. C. C. Hightower in February 1928. A month later a growth was noticed under the left arm which gradually became larger. On May 21, 1928 the patient reported to the Crawford Clinic in Hattiesburg with what appeared to be a malignant nodule at the outer border of the left pectoralis muscle and four smaller nodules extending down into the axilla. A specimen was removed by Dr. W. W. Crawford and sent to Dr. John A. Lanford, of Touro Infirmary, New Orleans, who reported that the growth was a melanosarcoma of the most highly malignant type; the cells were dividing so rapidly that no pigmentation was in evidence. Sections were also examined by

SERIES A, INOPERABLE SUCCESSES, DETAILED HISTORIES

Drs. Francis Carter Wood and James McWorter, both of whom agreed it was a malignant tumor but did not classify it. (67)

RADIATION: One x-ray treatment was given at the time of the biopsy.

TOXIN THERAPY (*Parke Davis XIII*): Injections were begun by Crawford on May 29, 1928, the initial dose being 1 minim. This was increased by 1 minim at each injection until the maximum of 15 had been reached. The frequency was daily for the first 11 days and thereafter every two or three days during all of 1928. The maximum febrile reaction was 103.8°F., with a chill which occurred on June 7, following a dose of 9 minims. In August 1928 a small metastatic nodule appeared on the abdominal wall which was removed and also reported to be malignant melanoma by Lanford. The injections were continued, the dosage ranging from 10 to 16 minims. During 1928 a total of 63 injections were given from May 29 to December 31. During 1929 a total of 65 injections were given. In January 1930 a small, typical lesion appeared on the neck, about the size of a small hazel nut, of a purplish-red hue. This could have been removed surgically, but in view of the fact that it was metastatic, Crawford felt it was best to persevere with the toxins. Accordingly the injections were continued, and at the end of three months nothing remained but a small scar. The patient received 6 injections in January 1930, 3 in February, 4 in March, 1 in April, 4 in May and 3 in September 1930. Further courses of the toxins were given at intervals of several months, until about September 1933, in doses of about 12 to 16 minims, making a total duration of over five years. No further metastatic lesions developed after about October 1931. Prior to that, one or two other small lesions appeared and gradually subsided under continued treatment.

CLINICAL COURSE: The patient married about 1933 and one child, a son, was born in 1934. The patient remained in excellent health, except for an appendectomy early in 1952, until 1956, when he began having episodes of mild angina. Electrocardiograms revealed evidence of myocardial ischemia. The episodes of angina were well controlled by Peritrate (10 mg. four times daily). In November 1961, an incisional hernia in the scar of the appendectomy was repaired by Dr. J. Grady Cook. At this time his blood pressure and other findings were within normal limits. In 1962 his only son died suddenly of a coronary occlusion. The patient's weight in 1963 was 205 pounds, his height being 5 feet 11½ inches. He remained in good health when last traced January 26, 1975, over 47 years after onset.

COMMENT: Crawford used the toxins over a period of 27 years, and he regarded the above case as the most outstanding. In sending us the history he added: "The late Dr. Coley seemed to feel that our success in this particular case was due to our systematic and persistent treatment over a period of years." In discussing his

experience with the toxins Crawford stated in 1943 that he has used intramuscular injections in all his cases, usually in the gluteal region, using the Tracy XI product as long as it was available (to 1921), and thereafter the Parke Davis XIII. He usually began with one minim, increasing daily until a definite reaction occurred, the dose necessary to accomplish this varying from 6 to 15 minims. When a definite reaction was obtained, a further injection was not given until the temperature had returned to normal, usually a day or two. The dosage was then reduced by 2 or 3 minims and daily administration resumed until another reaction was obtained. He added: "Whenever a patient was hospitalized it was possible to follow up an aggressive program . . . for several weeks, and later courses were administered at intervals over a period of a year . . ." Among the cases that did not recover, a number showed signs of disintegration of the lesion and in some instances sloughing took place. In other cases there was a definite shrinkage of the lesion temporarily. (10)

REFERENCES: 10; 67

CASE 66: Neurofibrosarcoma of the popliteal space, confirmed by microscopic examination by Dr. Thurston H. Dexter, pathologist of Wyckoff Heights Hospital in Brooklyn, and Dr. McNeal, pathologist of the New York Postgraduate Hospital. The latter reported on December 6, 1929: "This is a neurofibrosarcoma, much modified or altered by x-ray or radium or both. No cells with mitotic figures of sarcoma cells are identified, but that in all probability is because of the destructive action of the x-ray or the radium upon these cells. Some parts of this tumor undoubtedly contain nerve elements. This type of tumor is prone to recurrence and such a recurrence is an indication for amputation. Metastasis does not occur, or is rare, so that amputation is a complete cure. Coley's fluid appears to be effective in some cases . . ." (10)

PREVIOUS HISTORY: Miss G.R., female, aged 21. Onset, about three months prior to consulting Dr. Russell S. Fowler, of Brooklyn, in February 1929 the patient noticed a swelling in the back of the leg above the knee. This increased in size but was painless. Sometimes there was a "drawing sensation". The patient was first seen by Fowler on May 10, 1929. He made a clinical diagnosis of neurosarcoma and advised an exploratory operation. This was performed on May 14, 1929. It was found impossible to remove the growth as the popliteal vessels and nerves were involved. Two large sections were removed. Fowler stated at this time: "This case will probably need an amputation as it has already been treated by x-ray and the tumor has grown". (10)

SERIES A, INOPERABLE SUCCESSES, DETAILED HISTORIES

TOXIN THERAPY (*Parke Davis XIII*): Injections were begun by Fowler on May 26, 1929 and were given in gradually increased doses. Fowler stated on July 18 that the "tumor disappeared after a dose of $13\frac{1}{2}$ minims of Coley's fluid had been reached" (in about five or six weeks).

CLINICAL COURSE: At examination on August 7, 1929 there was no evidence of tumor remaining. A week later the patient was again seen and it was noted that the leg was quite a bit more swollen but there was no evidence of recurrence. Examination of the groin on that side showed quite a number of small lymph nodes. On August 21 Fowler reported: "The leg today is a bit less swollen. There is no increase in the size of the tumor. It is simply a thickening in the popliteal space as compared with the other side. Glands in the groin are less prominent."

FURTHER TOXIN THERAPY (*Parke Davis XIII*): Injections were resumed on August 23, 1929, the initial dose being 0.5 minim diluted in 9 minims of sterile water, injected into the right upper forearm. Another injection (1 minim) was given five days later, and it was noted that the nodes in the groin were no larger. An injection of $1\frac{1}{2}$ minims was given on September 9 and another on September 18, 1929. On the latter date it was noted that the growth was a trifle larger, but on September 23 Fowler stated the growth seemed smaller. Further injections were given on September 27 ($2\frac{1}{2}$ minims), and 30 (3 minims). By October 19 Fowler reported that the tumor was disappearing. About two injections a week were given during October and November, maintaining the dose at 3 or $3\frac{1}{2}$ minims. Thereafter, one injection a week was given during the first seven months of 1930. Fowler reported on November 22, 1930: "Beyond some thickening the tumor has disappeared". On February 19: "Not much of a tumor, but some thickening along the tendon." (10) No toxins were given for six weeks during the patient's vacation, from June 28, 1931. Thereafter they were given every three weeks, maintaining the dose at 3 minims. On August 5 it was noted that the tumor was small and hard with occasional pain. On October 10, 1931 Fowler noted the tumor seemed rather larger and he advised giving an injection weekly, which was done during November and December 1931. Apparently no injections were given during the first $4\frac{1}{2}$ months of 1932. They were resumed on May 21 and given weekly ($3\frac{1}{2}$ minim doses). On October 14, 1932, Fowler reported: "The growth seems a bit smaller. Certainly the Coley's (fluid) is keeping it under control." Weekly injections were continued through 1933. They were given intramuscularly in the deltoid and gluteal regions and the thighs. At examination on October 27, 1933 it was noted that the growth was much smaller than at last examination. There were enlarged nodes in each inguinal region. At examination on June 5, 1935, the nodes in the groin and the popliteal tumor appeared about the same. Some injections were given during 1934 and 1935, making a total duration of six years.

CLINICAL COURSE: The patient married in 1937 and during the next few years is

SERIES A, INOPERABLE SUCCESSES, DETAILED HISTORIES

said to have had a child. She was last traced in good health in May 1945, over 16 years after onset. (10)

REFERENCE: 10

CASE 67: Terminal sarcoma of the neck, face and submaxillary region involving the bones and subcutaneous tissues; the forehead, parietal regions, left cheek and jaw being most affected, confirmed by microscopic examination. There was marked bilateral exophthalmos.

PREVIOUS HISTORY: Miss H.P., female, aged 19, of Mahanoy City, Pennsylvania. The family history was negative for cancer, tuberculosis and diabetes. The patient had had the usual diseases of childhood, but no serious illnesses. She had a tonsillectomy at the age of nine. Thereafter she had chronic bilateral otitis media. (She never had any ear trouble until after her tonsils were removed, but she was regarded as a "sickly" child.) Menses began at the age of 14½ years, a normal cycle. Onset, in March 1931 a hard nodular swelling of the neck was first noted directly below the angle of the right jaw. This gradually became larger and in a few months was 4 cm. in diameter. A provisional diagnosis of deep cervical abscess was made at a hospital in Pennsylvania.

SURGERY: Upon operation no free pus was found. A specimen of tissue was sent to the Research Institute of Cutaneous Diseases in Philadelphia, and a diagnosis of chronic interstitial adenitis was made. Shortly after this operation the hard fixed swelling gradually began to extend inwards until it had filled the entire right submaxillary region and by pressure produced edema of the pharynx.

RADIATION: Several small doses of x-ray therapy were then given without any relief.

CLINICAL COURSE: On June 14, 1931 the patient was admitted to Jefferson Hospital, Philadelphia, where a tracheotomy was performed because of edema of the glottis.

FURTHER RADIATION: Radium treatment was given at this time. (She was hospitalized four weeks.) Further radium treatment was given on August 15, 1931 and again in September, apparently without benefit. By September 21, 1931 the swelling had extended into the face and bones of the skull. Further radium treatments were given after November 31, 1931.

CONCURRENT CHRONIC INFECTION: On January 28, 1932 the patient was operated

SERIES A, INOPERABLE SUCCESSES, DETAILED HISTORIES

upon for chronic mastoiditis, a left mastoidectomy being performed at Jefferson Hospital, Philadelphia.

FURTHER RADIATION: Radium treatment was given "to its full extent" during the next few months. No burns were produced, but the patient experienced marked "radiation sickness".

CLINICAL COURSE: The patient was discharged on May 12, 1932 extremely ill, the end being expected at any time. The tumorous condition was localized to the region of the head and face, seemingly involving the bones and subcutaneous tissues. The forehead, parietal regions and left cheek were most affected. There was marked exophthalmos of both eyes, the lower lids were everted, and greatly swollen. The left mandible was involved and almost completely ankylosed. A foul smelling slough was present in the region of the left lower molar. Treatment at this time was entirely symptomatic, mostly morphine. Her weight had declined steadily from a normal of 120 pounds at onset to 70 pounds in early June 1932. Her height was 5 feet 2 inches.

TOXIN THERAPY (Parke Davis XIII): Injections were begun by Dr. Clemens S. Burke of Mahanoy City, about June 12, 1932, the initial dose being $\frac{1}{4}$ minim, increasing every 48 hours by $\frac{1}{4}$ minim. Burke stated: "An improvement was noted following the first few treatments, subsequently on larger dosage a more rapid result. Although there was always some improvement and the swelling disappeared, another would develop elsewhere . . . The larger dosage that became necessary to use caused much pain and areas of painful induration." The patient and family objected to further use of the toxins at this time, and Burke was forced to discontinue treatment. (This course was given subcutaneously into the arms and buttocks, a route that is no longer considered effective, and which does produce painful indurations and slow absorption.)

CLINICAL COURSE: The tumor again began reappearing at various sites.

FURTHER RADIATION: At a local hospital x-ray therapy was then given, with very marked benefit. The tumor disappeared from all parts of the face and head where it was showing evidence of recent growth. By March 27, 1933 it was limited to the right submaxillary region and under the chin as one large extensive mass involving the floor of the mouth, causing the tongue to be elevated, and great difficulty in breathing and swallowing.

FURTHER TOXIN THERAPY (Parke Davis XIII): Injections were resumed and two more courses were given with an interval of rest between them. The intravenous route was used and marked reactions were produced (102°-103°F.) The total duration of treatment at this time was several months. The tumor mass broke

SERIES A, INOPERABLE SUCCESSES, DETAILED HISTORIES

down, a part of the tongue sloughed out, and also a portion of the lower jaw. The remains of the extensive growth disappeared and the patient made a complete recovery. She gained over 40 pounds of the weight she had lost.

CLINICAL COURSE: She married in March 1937. Her first child, a son, was born the following autumn. The second and third children, both daughters, were born in 1939 and 1945, all being healthy and normal. The patient stated that her only complaint during the years following her recovery was that when she caught cold she tended to get ear trouble in both her ears (otitis media, no further mastoid). However, she was strong enough to do all her own work and, in addition, for 2½ years she had an outside job as well. Her normal weight in 1955 was 114 pounds. In July 1958 she had a severe pneumonia. Thereafter she seemed to be abnormally sensitive to cold or draughts. She remained well until 1962, when she lost 16 pounds due to a gastric ulcer for which she was finally hospitalized in October 1962. In January 1963 her gastric symptoms exacerbated, then rapidly improved. She developed another ear infection and early in 1964 another left lobar pneumonia. This was followed by symptoms of constipation. By April 1964 there was swelling of the abdomen and a month later pretibial edema and ascites were present. The uterus was hard and enlarged to the size of a six months' pregnancy.

SURGERY: An exploratory laparotomy was performed on May 18, 1964. Upon opening the abdominal cavity approximately 1,000 cc. of dark, ascitic fluid was removed. A hard, irregular mass approximately 18 cm. in diameter arising from the right ovary was removed. The left ovary was enlarged, hard and irregular, measuring approximately 8 cm. in diameter. It was also removed. The wall of the stomach was hardened with a tumor apparently involving the greater curvature of the stomach as well as the mesentery of the small intestine. The tumor was hard and nodular. Because of its extent no attempt at further surgery was deemed advisable. The patient tolerated the procedure well. The pathologist reported on examination of both ovaries that these lesions were consistent with metastases from the gastric cancer.

CLINICAL COURSE: The patient was palliated until her death on September 21, 1964, 33½ years after onset of the sarcoma of the neck and face.

COMMENT: In this case the initial course of toxins given in small doses subcutaneously did not prove effective. It is now recognized that subcutaneous injections are not effective and the indurations produced due to poor absorption are unpleasant for the patient. It is of interest to note that radiation in this case had no effect at all until after the initial course of toxins. However, prolonged radiation caused only temporary incomplete regression. The disease was not finally controlled until prolonged intravenous toxin therapy was given. The possible role of the chronic bilateral otitis media and mastoiditis is difficult to evaluate in this

SERIES A, INOPERABLE SUCCESSES, DETAILED HISTORIES

case. However, they may have played a part in supplementing the toxin therapy, to which Burke attributed this remarkable recovery.

REFERENCES: 10; 67

CASE 69: Inoperable sarcoma, type undetermined, was the report based on microscopic examination following aspiration biopsy of a firm, not hard mass which filled the whole left lower abdomen and pelvis. Clinically the condition was regarded as either a neuroblastoma, a myosarcoma or a liposarcoma. Dr. James Ewing reported: "No definite tissue. Shreds of fibrous tissue and much hyaline necrotic material. One fragment shows malignant tumor tissue, cells large and much intercellular material containing fat. Might be a liposarcoma, fragments of fat. Sarcoma, type undetermined." (128) (F 6262) He reported on another section: "No definite tumor . . . Fragments of condensed mucus mixed with fat droplets and hyaline material. This might be a degenerating tumor such as a chondroma." (128)

PREVIOUS HISTORY: Miss N.P., Italian, female, aged 26. The family history was negative for tuberculosis, cancer or diabetes. The patient had pneumonia four times when two or three years old. She had diphtheria at five, and a slight case of scarlet fever; also other diseases of childhood. Menses began at the age of 12, a regular 33-day cycle, the flow lasting 5 days, with moderate to severe pain. She usually took aspirin and went to bed the first day. She went through the seventh grade (? I.Q.), then kept house for her mother. Onset in 1928, at the age of 19, she developed pain in the right hip and buttock, radiating down the right leg to the knee. She stated it felt "like a cold cramp". Onset was very sudden, in the middle of the night. The patient's mother thought that she had appendicitis and put an ice bag on the right lower abdomen and right flank. (The pain was lateral to the appendix.) The patient could not stand the ice bag, so a hot water bottle was substituted, with some relief, and she was given aspirin. She remained awake all night. Next day she could not walk. She remained in bed for three weeks. At the end of the first week the family physician, Dr. F. Walter Gravelle of New York, was called in and he referred her to two other physicians. At the end of three weeks in bed she was sent to Misericordia Hospital where she remained two weeks. Operation was advised by Dr. Butler, but refused by the patient's mother. "Some sort of needle puncture was done and some sort of traction applied to the leg, and some applications were made to the anterior thigh." Shortly after her discharge she was able to walk, but "was weak in the right leg and acted something like a cripple."

SERIES A, INOPERABLE SUCCESSES, DETAILED HISTORIES

HEAT THERAPY: She was taken to the Hospital for Special Surgery in April 1929, where 21 diathermy and physiotherapy treatments were outlined. The patient took only nine of these because the condition improved so that she could walk, and she felt well and thought "she did not need any more".

CLINICAL COURSE: Following this episode there was no atrophy of the leg and no loss of weight, and the patient recovered full use of the limb, being able to walk and to dance. She considered herself perfectly well from May 1929 until August 1934, when the same pain returned and gradually became worse, with cramps and drawing sensations in the right leg extending to the knee, also pain in the buttocks. She stated that she could not sleep at night because of the pain. There had been no history of trauma or accident prior to either of these painful episodes. On December 5, 1934 the family physician, Gravelle, was consulted. He examined her with Dr. Barrows at the Hospital for Special Surgery. According to the patient, Barrows' diagnosis was "cyst of the appendix".

SURGERY: An exploratory operation was advised and performed on December 8, 1934 at St. Clare's Hospital, New York. The patient was "told that operation was of no avail and that she would still have some trouble". Apparently a specimen was removed but no microscopic examination was made at this time. Gravelle "opened a cyst in the wound", and with this exception there were no post-operative complications and the patient was discharged after 13 days in hospital.

CLINICAL COURSE: Thereafter the pain continued and became worse. The patient was advised to go to Memorial Hospital for radiation. She was examined at Memorial Hospital on January 29, 1935 by Dr. Jay McLean. She was a highly strung, nervous young woman, in considerable pain, of which it was difficult to note the severity. The pain was located in the right buttock and right upper thigh posteriorly. There was apparent diffuse swelling of the thyroid, but habitus of the patient's shoulder and neck was considered as possibly giving this undue prominence. There was slight lid lag and tachycardia, but no tremor, and there was a very slight suggestion of exophthalmos. These symptoms were considered as due to parathyroid imbalance. There was a large bulging mass arising from the pelvis and extending almost to the mid-axillary line in the flank, filling the right lower quadrant of the abdomen to the level of the umbilicus and extending across the midline at that level for a short distance. At its widest portion it measured 27 cm, from the midaxillary line across the abdomen horizontally, 3 cm. below the umbilicus. The mass was firm but not hard, and was fairly well fixed but not sufficiently firmly fixed to arise from bone. There was a cicatrix in the midline due to the recent operation. Rectal examination showed the right pelvis to be filled with tumor. The right leg measured 53 cm. in circumference in the mid-thigh, the left being 1 cm. less. The Wassermann reaction was negative. X-rays of the pelvis taken on January 30, 1935 showed no evidence of metastases or tuberculosis in

SERIES A, INOPERABLE SUCCESSES, DETAILED HISTORIES

the chest. "Stereoscopic views of the pelvis revealed evidence of a destructive process involving the body of the right ilium; the outline of a bulky soft part tumor projecting from the inner surface of the ilium into the pelvis and lower quadrant of the abdomen is seen. The process involves at least the upper anterior half of the body of the ilium. Two large areas of bone destruction are shown separated by an area of comparatively uninvolved bone. The upper area of destruction extends through the posterior wall of the ilium. No evidence of bone reaction or bone growth in or about areas of destruction is seen and no bone production in the soft part mass is visualized. Although it appears that the process is definitely a tumor and malignant, it is difficult to state with certainty whether it is overlying tumor. We suspect, however, that because of the bulk of the soft tumor and the diffuse irregular destruction of bone, that the tumor is primary here, possibly a Ewing's tumor." (Ralph E. Herendeen, M.D.) Dr. J. A. Kelly of the Gynecological Service saw the patient in consultation on January 30, 1935. He stated that "the tumor mass filling the left pelvis laterally seemed adherent to the bone or to the pelvic fascia, but gave the impression that it did not arise from the bone. Rectal and abdominal examinations revealed a semi-cystic tumor mass probably retroperitoneal in origin. Diagnosis, retroperitoneal sarcoma . . . not of kidney origin." Two aspiration biopsies were performed on January 30 and 31, 1935. The patient was shown in conference on January 31, and Dr. George Pack stated that he believed the defect in the ilium was due to extrinsic pressure from the tumor mass. He made a presumptive diagnosis of neuroblastoma. The patient was then referred to Dr. Bradley L. Coley who reported: "Owing to the bulk and extent of the tumor it is a little difficult to ascribe it to a primary tumor of the ilium. On the other hand, the x-rays suggest this rather than that the bone changes are due to external pressure. In view of the microscopic findings on aspiration, and the x-ray, together with the report of the operating surgeon, that the tumor was entirely retroperitoneal, I look upon it as most likely a neurogenic, lipogenic or myogenic sarcoma . . ."

RADIATION: Between February 4 and March 15, 1935, x-ray therapy was given six days a week as follows: 198 K.V., 250 r each to the left anterior mid-abdomen (250 r x 8); the right pelvis, anterior (250 r x 8), posterior (250 r x 9), and lateral, (250 r x 9), a total of 8,500 r. These treatments were given as an out-patient. By February 27, three weeks after treatment was begun, Coley stated that a rather striking change in the patient's condition was evident: the mass had largely disappeared from the right pelvis and the patient walked without a limp and without pain and felt markedly improved. At examination on March 13, 1935 the general appearance and abdominal findings continued to show improvement. Rectal examination, however, still disclosed a considerable hard mass in the pelvis. Abdominal examination on March 27, 1935 failed to reveal any palpable tumor, but pelvic examination was not done because the patient was menstruating. Pelvic and rectal examination by Drs. Healy and Smith on April 24, 1935

SERIES A, INOPERABLE SUCCESSES, DETAILED HISTORIES

indicated that the mass was softer when felt through the rectum, but recent x-rays showed no bony change. At examination on May 1, 1935 there was no palpable swelling. On May 15, 1935 the patient was seen in consultation with Dr. W. B. Coley, who strongly urged that toxin therapy be administered. Rectal examination on May 15, 1935 revealed no evidence of tumor.

TOXIN THERAPY (*Parke Davis XIII*): Injections were begun on June 3, 1935 and 20 were given in 28 days. The first 11 were given intramuscularly in doses of 1 to 10 minims, causing febrile reactions averaging 100.6° to 102.4°F. (minimum 99.6°F., maximum 105°F.) Chills occurred after the second, ninth and eleventh intramuscular injections lasting 15, 35 and 40 minutes respectively. Headaches, at times severe, occurred after several injections and nausea after the maximum reaction (ninth dose). Thereafter seven intravenous injections were given in doses of 1/60 to 0.5 minim, causing febrile reactions averaging 101° to 102.4°F. (maximum 103.6°F.) Chills occurred after all but two of the intravenous injections, lasting 15 to 30 minutes. Two more intramuscular injections were given during the latter part of this course, on June 22 and 25, in doses of 12 and 15 minims, causing febrile reactions of 103° and 101.8°F., and a chill lasting 20 minutes after the first of these. The patient was allowed up and about the ward except during her reaction period.

CLINICAL COURSE: X-ray examination of the pelvis taken in July showed no evidences of change in the pelvis. The patient was seen on July 10, 1935 and Coley noted that since her discharge a week previously, she had "picked up in weight, spirits and general appearance, says she has no symptoms. Condition apparently satisfactory." There was no evidence of disease found at examination and the patient remained symptom-free. She was married during the fall of 1935. She continued to gain weight and remained in excellent general health. In May 1936 she stated her only complaints were referable to the artificial menopause (radiation induced). By June 10, 1936 the hot flashes were very much better. She continued to be symptom-free. X-ray examination in January 1937 showed almost complete filling in of the cavity in the right iliac bone. The overlying skin was in excellent condition. Menstruation again occurred on March 6, 1937. After her period in January 1938 she complained of pain in the right side and at examination on February 16, at Memorial Hospital, there was some spasm, but no definite fullness in the right side. She was again examined in the gynecological clinic on March 2, 1938, at which time Kelly stated: "It is interesting to note that despite heavy radiation to the pelvis in March 1935, with almost immediate cessation of menses and vasomotor disturbance of artificial menopause, of hot flashes, etc., that this patient after two years is again beginning to menstruate, having periods (since August 1937) . . . every 28 days, lasts 5 days, with average flow. All symptoms of artificial menopause cleared up . . . cervix is somewhat congested. Corpus is in mid-pelvis, difficult to outline, and enlargement cannot definitely be

SERIES A, INOPERABLE SUCCESSES, DETAILED HISTORIES

noted. Has had some pain in right leg, suggesting recurrence of old lesion, but there is nothing found on examination. A-Z test to be taken for possible pregnancy." The patient became pregnant in June 1938, and the pregnancy proceeded normally. A normal baby girl, weighing 8 pounds, 1 ounce, was born on February 14, 1939, after a total labor of 12 hours (delivery, postpartum course normal). She was examined at rather frequent intervals in the Gynecological Clinic at Memorial Hospital during 1939, and appeared symptom-free. She again became pregnant in October 1939 and the second child was born on July 15, 1940, a normal pregnancy and delivery. She was again seen in the Bone Tumor Clinic at Memorial Hospital on September 11, 1940, at which time she was symptom-free. On September 3, 1941 she returned to the Gynecological Clinic with symptoms of pain in the lower abdomen, pelvic region and thigh extending down to the foot. She appeared to be very worried about her condition. Although nothing palpable was made out on examination, x-rays were taken of the pelvis, right femur, tibia and foot. These revealed no significant changes since the last examination in 1937, but the lesion originally described in the wing of the right ilium showed marked reparative changes had taken place since the first examination in 1935. There were no findings of significance in the right lower extremity. Apparently these symptoms cleared up in a few months and were considered as possibly due to varicose veins. During the winter of 1942 she complained of pain in the area to the right of the umbilicus. Pelvic examination was negative except for some tenderness in each adnexal region. These complaints all cleared up by May 1943. In 1945 the patient was operated upon at the Physicians Hospital in Jackson Heights, New York (ectopic pregnancy). At examination on April 23, 1947 she complained of low back pain. Pelvic examination showed that the uterus was heavy and retroverted. No adnexal masses were palpable. Rectal examination was negative. There was 1.5 cm. erosion on the posterior cervical lip. A biopsy was taken of this area and vinegar douches were advised. The cervix was cauterized in the Gynecological Clinic on May 7, 1947. During September and October 1947 the patient had daily vaginal bleeding. Examination on October 29, 1947 showed an edematous polyp within the cervix. This was removed for biopsy. On May 12, 1948 she stated that for two years she had had a lesion on her right alveolar process in the level of the first molar. On pressure this yielded some pus and blood. The patient also showed evidence of cheilosis, which was considered due to a vitamin deficiency. Brewers yeast was prescribed. She was seen in the dental clinic at Memorial Hospital. The "tumor in the gingivobuccal gutter had the appearance of an apical abscess, and numerous other teeth were in poor condition and carious." Two teeth were extracted. During January 1949 the patient complained of pain in the right hip bone and right ribs. X-rays were taken but proved negative. In June the patient complained of some pain in the left groin at the time of her periods. There was heavy mucoid discharge from the cervix when the patient was examined on June 15, 1949. Due to rather profuse menstruation, with clots during the summer of 1949, the patient had an endometrial

SERIES A, INOPERABLE SUCCESSES, DETAILED HISTORIES

biopsy on September 14, 1949. This was negative. In early 1950 the patient had one or two episodes of spotting, mainly before her periods. The uterus was retrodisplaced, heavy and slightly irregular, and undoubtedly contained myomata. An endometrial biopsy taken on February 8, 1950 was reported "proliferative endometrium". Uterine symptoms persisted and on July 17, 1955 a pan-hysterectomy and bilateral salpingo-oophorectomy was performed at James Ewing Hospital. The pathologist reported that the specimens showed "fibromyomas, atrophic endometrium, chronic cervicitis, with squamous metaplasia; atrophic ovaries". The postoperative course was uneventful and the patient was discharged on July 25, 1955. Thereafter she complained of numerous hot flashes. There was no evidence of disease at examination on May 13, 1968, about 40 years after onset.

COMMENT: An unusual factor in this case is that although radiation menopause occurred lasting for two years, ovarian function then recovered and the patient had two normal children and an ectopic pregnancy. Possibly the course of toxin therapy given so soon after the radiation may have exerted a protective effect.

REFERENCES: 10; 128

CASE 69: Recurrent inoperable dermoid sarcoma of the left erector spinae muscle, confirmed by microscopic examination following the second operation in London, England.

PREVIOUS HISTORY: Mrs. Y., female, aged 52. The family and previous personal history was non-contributory. There had been no local injury or infection. The patient was first seen by Mr. Harold Dodd, Ch.M., F.R.C.S., on March 2, 1936. Examination revealed a swelling in the erector spinae muscle below and inside the inferior angle of the scapula.

SURGERY: On April 30, 1936 Dodd widely excised the growth with the overlying deep fascia and the underlying rib. The base of the wound was filmy pleura. The skin was sutured over it. The tumor was the usual hard, fibrous mass gradually merging into the belly of the muscle. It was the size of a large walnut. The patient made a good recovery.

RADIATION: During the next 18 months she received considerable deep x-ray therapy. The tumor recurred about six months following the operation and was not controlled by the radiation. The recurrent tumor fixed the scapula to the chest wall.

FURTHER SURGERY: Another excision was attempted in November 1937 but the

SERIES A, INOPERABLE SUCCESSES, DETAILED HISTORIES

skin, scapula, rib and pleura were fused into a homogeneous mass of tissue and the operation had to be abandoned on account of profuse hemorrhage. Dodd found it impossible to define the limits of the extensive tumor. A specimen was removed for biopsy.

FURTHER RADIATION: The patient was sent to the radiotherapy department and received further deep x-ray therapy until March 1938, when Dr. Carter Brain discontinued treatment because it was ineffective. The patient was then referred back to Dodd, much worse, and in an apparently hopeless condition. Dodd stated: "The skin, the scapula and the chest wall were a huge, lumpy mass. There seemed nothing further to be done, but as she was the wife of a working man with four children, as a last resort she was given Coley's fluid."

TOXIN THERAPY (*Parke Davis XIII*): Beginning on April 2, 1938, the toxins were administered weekly, the patient being treated as an out-patient. The initial dose was 0.05 cc. given into the shoulder muscles. These caused malaise, chills, headache and some vomiting for three to five days, giving her comparative comfort for 48 hours in which to look after her husband and children. Dodd added: "She was courageous in the way she stuck it. The injections were continued week by week, the dose being increased so as to maintain the reaction at four to five days' duration." During the course of the treatment the affected area became more mobile and the scapula free on the chest wall. In June, after two months' treatment, a week's rest was given. By August 1938 the dose was 1.6 cc. given intramuscularly near the tumor. The growth regressed slowly over a period of about 20 months, by a process of absorption and sanious discharge. The final injection in this course was November 8, 1938, making a duration of eight months.

CLINICAL COURSE: The patient continued to have some pain in the neck, and was given morphia. She also received a few injections of diketal (ethylene disulphonate). By January 1940 the growth had entirely disappeared and the area was firmly scarred.

SECOND COURSE OF TOXIN THERAPY (*Parke Davis XIII*): Injections were resumed on January 29, 1940. These were given on alternate weeks with injections of T.A.B. vaccine. The dosage of Coley's toxins was 0.05 cc., increased gradually to 1.5 cc. The initial dose of T.A.B. vaccine was 50 million increased to 1400 million. The final injection of Coley's toxins was given on August 26, 1940; the final injection of T.A.B. being on November 18, 1940. This second course of toxins and T.A.B. was given to relieve causalgic pain and to enhance the vasodilation and the pyrexia, with a view to the completest resolution of the scar tissue. The final injection apparently entered a vein and caused an extremely severe reaction. Thereafter she refused further treatment.

SERIES A, INOPERABLE SUCCESSES, DETAILED HISTORIES

CLINICAL COURSE: There was no further pain after August 1940. The patient was examined periodically by Dodds. When last seen on July 25, 1960 he reported as follows: "She is now 68. She is keeping house for her daughter and her husband and three children (both the parents work). She has no sign of arteriosclerosis that I could see. Mentally she is bright and optimistic and enjoying life. Her seven children are married and she has ten grandchildren. "The scar, where her sarcoma was, remains supple and depressed, with no evidence of recurrence. She is quite the most dramatic patient I have had."

REFERENCE: 10

The following case received the *Sloan Kettering XIV* preparation of Coley Toxins:

CASE 70: Generalized hemangioendotheliomata (site of primary unknown), with metastases throughout the body, confirmed by microscopic examination of several tumors removed for biopsy at Grace Hospital, Detroit, Michigan, March 23, 1947. The pathologist reported: "Gross: Specimen A consists of tumors from the abdomen and head removed with a knife. Specimen B consists of a tumor from the left arm removed with a needle. Microscopic: The specimens from the three areas are identical in composition and contain a new growth within the corium and subcutaneum. The new growth is unencapsulated and is composed of numerous small blood vascular spaces. The latter are lined with tumor cells which are endothelial in type and the septae between the blood spaces are made up of a proliferation of the lining cells of the blood spaces. There is a tendency for the new growth to form isolated masses of vascular spaces separated by connective tissue trabeculae which vary in thickness and in places exhibits a marked hyperkeratosis. In view of the fact that this individual has multiple tumors of identical composition, it is entirely logical to believe that he had one primary tumor which has metastasized throughout the body. Internal metastases may be present or occur. Diagnosis: hemangioendotheliomata." (10)

PREVIOUS HISTORY: Male, aged 53, of Detroit, Michigan. The family history was negative for similar types of neoplasia and the previous personal history was also

SERIES A, INOPERABLE SUCCESSES, DETAILED HISTORIES

essentially negative. The patient had "several bluish lesions" removed from his lip in 1938 by another surgeon. Onset, in December 1946 he noticed that many reddish macules and papules were appearing on various parts of the body which he referred to as "warts". He was seen by Dr. Felix Pinkus, the well known German dermatologist. A biopsy was performed. Pinkus considered the lesions to be probably Rendu-Osler's type of telangiectasia. His son, also a prominent dermatologist, did not accept this diagnosis.

RADIATION AND OTHER THERAPY: Various types of treatment were tried, including penicillin and rutin, and also x-ray therapy (to three lesions on the face), without benefit.

CLINICAL COURSE: The patient was referred to Dr. Clyde E. Hasley on March 24, 1947, at which time he had multiple lesions on the hands, arms, face, head, body and legs, which had been developing since December 1946. About two months after they first appeared many of the lesions bled and were painful, but there was no bleeding from the mucous membranes. Telangiectasis was detected under the tongue. The other physical examinations were negative. Laboratory tests showed his coagulation time as $4\frac{1}{2}$ minutes, his bleeding time as $1\frac{1}{2}$ minutes.

SURGERY: Several lesions were removed from different parts of the body, some with the scalpel, others by electrodesiccation (see above for pathological report on three of these lesions).

FURTHER RADIATION: Some of the lesions on the hands and arms were then treated with x-ray therapy (1,200 to 1,900 r.). There was no beneficial response to radiation in the period when benefit should have been noted.

TOXIN THERAPY (SKI XIV): Injections of Coley toxins were begun on April 1, 1947 by Hasley. The initial dose was 1/80 minim which caused a slight chill, but no severe reaction. The next day a dose of 1/60 minim caused a febrile reaction of 104°F. It was noted that day that "some of the lesions were quite dry and were falling off . . . there was considerably less bleeding from some of the irritated lesions." The patient was given a total of 12 injections intravenously in a period of 18 days, the maximum dose being $1\frac{3}{4}$ minims. The febrile reactions averaged 102°-104°F. He was discharged on April 19, 1947. He was examined at frequent intervals during the next five weeks. On April 24, three weeks after the first injection, Hasley observed that the lesions were getting much smaller. On May 1, as the patient seemed extremely nervous, he was placed on phenobarbital. A week later the lesions were still smaller; on May 28, 1947, very much smaller.

CONCURRENT INFECTION: After the patient was discharged from the hospital, many of the lesions became secondarily infected. No details are known concerning what type of infection was present or what treatment was given.

SERIES A, INOPERABLE SUCCESSES, DETAILED HISTORIES

CLINICAL COURSE: The patient was not seen again by Hasley for 11 years, until June 5, 1958, at which time he presented a pigmented lesion over the right shoulder area. Clinically it appeared to be melanoma. This was the only pigmented lesion present on the body. All the former lesions present in 1947 were healed with very little atrophy and no evidence of telangiectasis.

SURGERY: The melanotic nodule was removed as an excisional biopsy on June 13, 1958. The pathologist reported "multiple foci of new growth . . . melanoblastoma of skin".

CLINICAL COURSE: The patient was advised to have further toxin therapy post-operatively, but refused. He returned to work and appeared to be well. However, in March 1959 metastases developed in the cervical region and axilla. The axillary mass was biopsied. Again the patient was urged to have toxin therapy. He finally consented on March 21, 1959, but only a few were given. On June 13, 1959 he re-entered the hospital and a biopsy of the liver was done, revealing hepatic metastases. On June 21, 1959 he expired. Death occurred 12½ years after onset of hemangioendothelioma, for which he was successfully treated.

REFERENCE: 10

OPERABLE SARCOMA SUCCESSFULLY TREATED BY TOXIN THERAPY, SERIES B

The following 35 patients are the only ones known to us with operable sarcoma of the soft tissues (other than lymphosarcoma) successfully treated by Coley toxins before or after operation, in which the diagnosis was confirmed microscopically. The first 17 cases were primary operable tumors; the last 18 were recurrent operable tumors. In Cases #3, 10, 14, 16 and 17 a small amount of radiation therapy was also given; in Case #31, somewhat more. In Case #12, concurrent pregnancy was a complication. In Case #16 three other types of neoplasm (endometrial polyps, cystic adenoma and basal cell carcinoma of the face) developed, 17, 19 and 27 years after the onset of sarcoma. In Cases #1, 23, 30 and 33 other types of neoplasm also developed, 57, 15, 27 and 22 years after onset of sarcoma—1 basal cell carcinoma of the face, 1 carcinoma of the prostate, and 2 carcinomas of the stomach. Patients #18, 27, 28 and 33 were the only ones with recurrent operable sarcoma of the soft tissues treated with toxin therapy alone and no further surgery, that remained well. (In Case #10 among the Operable Failures in Series D, recurrent, the tumor also regressed completely, but again recurred.)

Years Traced
After Onset

Primary Tumors (17 cases)

1. (DAVIES): Mrs. O.C.S.D., aged 35; fibrosarcoma of abdominal wall, 10 cm. long. Onset in August 1900; surgical removal September 15, 1900; two weeks later toxins begun (Buxton VI); given for six weeks in vicinity of cicatrix; no recurrence. Patient in good health next 57 years; basal-cell carcinoma on cheek excised September 13, 1957; coxa vara senilis developed; patient became bedridden; generalized arteriosclerosis with terminal congestive failure caused death March 25, 1958 age 92½. (10; 67) 57½
2. (COLEY): L.I., female, aged 19; sarcoma of groin. Date of onset not recorded; surgical removal on June 20, 1907. July 23, 1907: toxins (Buxton VI), 18 in 32 days; no recurrence. Patient alive and well in 1915. (67; 128) 8
3. (LUNDING-SMITH): Male, aged 10; extensive synovioma of popliteal space, involving capsule of knee joint. Date of onset not recorded; surgical removal in 1909. Prolonged course of toxins (Tracy XI) after operation; also a few x-ray treatments; no recurrence. Patient alive and well in 1913. (51; 67) 5
4. (COLEY): V.T., male, aged 39; myxosarcoma of left scapular region. Onset in September 1909; surgical removal; toxins (Tracy XI) after oper-

SERIES B, OPERABLE SERIES, SUCCESSES

Years Traced
After Onset

- ation for 3 months in region of former growth, at first daily; no recurrence. Patient in excellent health for next 34 years, until late 1943. He died on July 24, 1944, at age 75, from uremia "due to hypertrophy of the prostate". (10; 51; 67) 35½
5. (HARMER): L.A.W., male, aged 55; extensive small round-cell sarcoma of antrum and ethmoid, infiltrating in all directions; whole nasoastral wall destroyed. Onset, July 1910; two operations, October 14 and November 28, 1910. Toxins (Tracy XI) begun December 5, 1910; 49 injections in 5½ months; reactions often severe; no recurrence. Patient in good health December 12, 1911; not traced after 1915. (No record of death found in next 35 years, Massachusetts) (100) 5
 6. (COLEY AND FISHER): B.C.C., male, aged 7; fibrosarcoma of nerve sheaths involving pectineal muscle and lymph nodes in groin; rapid growth. Onset, November 1910; surgical removal December 4, 1910; possible recurrence in inguinal region. Beginning December 29, 1910, toxins (Tracy XI and Parke Davis XII) given for 3 months; gain in weight during treatment; no recurrence; normal development. Patient became a physician, married, 3 children, 5 grandchildren; remained in excellent health until 1973, then had 3 operations for gall bladder trouble; in good health 1975. (10; 51; 193) 65
 7. (HAINES): Mrs. R., aged 26, round cell sarcoma of breast. Onset, January 1911. Surgical removal of breast, pectoral muscles and gland-bearing fat in axilla; June 1911, after operation, toxins (Tracy XI) for a year; gained 50 lbs.; no recurrence, well when last seen 1929. Died, unknown cause, about 1933. (67) 22
 8. (REILLY): H.C.S., male, aged 34; small-cell sarcoma of head of colon. Onset in 1915; at operation, 45 cm. of ileum and cecum resected. Toxins (Tracy XI) given postoperatively (duration not recorded); no recurrence. Patient died on April 1, 1950, coronary embolism, at age 70. (7; 10; 67) 35
 9. (CALKINS): Mrs. O.L., aged 28; extensive sarcoma nearly filling pelvis, involving upper portion of vagina. Onset in May 1914, 11 months after abdominal hysterectomy for "large rapidly growing uterine fibroid"; sarcoma completely removed surgically via vagina and lower median incision. January 1, 1915, toxins (Tracy XI) given for 9 months; no recurrence. Patient alive and well in 1933. (67) 19
 10. (COLEY) J.R., male, aged 35; fibrosarcoma of thigh, size of grapefruit;

SERIES B, OPERABLE SERIES, SUCCESSES

Years Traced
After Onset

Onset in May 1920; hip-joint amputation advised by Mayos, Deaver, and Bloodgood; Coley advised exploration and removal if possible, followed by toxins; this was carried out in June 1921. Toxins (Tracy XI) given for 6 months postoperatively; also 5 x-ray treatments. Patient gained 66 pounds; no recurrence; in excellent health except for severe deafness until 1961, then developed prostate cancer; did very well on estrogen; wife had colon cancer resected about 1963; August 1965, incomplete resection of prostate carcinoma; few mild cerebral hemorrhages; death June 14, 1969 at age 84, "thought to be due to prostate cancer with metastases". (10; 67; 128)

49

11. (WARD): W.W., male, aged 42; mixed-cell sarcoma of leg in region of calf. Onset, October 1909; surgical removal September 4, 1910; toxins (Parke Davis XII) postoperatively; 65 injections in 8 months with interval of 6 weeks' rest; no recurrence. Patient remained healthy until death from acute cardiac failure at age 80, February 14, 1949. (7; 10; 197)

39

12. (COLEY AND LEVINE): Mrs. K.S.K., aged 34; neurogenic sarcoma of deltoid region of right arm, size of small orange. Onset December 1918. First operation in June 1920. Toxins (Parke Davis XIII) given post operatively beginning June 19, 1920; 75 injections in 90 days, all into pectoral muscles except 3 into outer limits of tumor area; recurrence. Second operation February 1921; patient 3 months' pregnant; second recurrence (grew faster after confinement); pain in both axillae. Toxins continued one year; radium inserted into tumor (7,900 mch.) during toxin therapy; another slight recurrence. Toxins resumed; given more aggressively, causing marked reactions; total duration 3½ years; no further recurrence. Patient returned to active work running a bookstore; fractured right arm at site of former growth, November 20, 1948; bone healed normally. In excellent health next 10 years, then developed lesion in right lung; segmental resection right lower lobe, March 31, 1960; "adenocarcinoma, low grade, pulmonary adenosis type"; remarkable rapid complete recovery; in excellent health, took round-the-world trip 1962; cataract removed from right eye, complicated by vitreous protrusion and glaucoma; in excellent health, living alone, doing own work until 1973, then "exacerbation of duodenal ulcer"; in November 1973 was mugged, causing fracture of left humerus and tear of right shoulder capsule; recovered; July 1974, fell in street, fracturing right hip, which was nailed; she then entered retirement home, "still alert and able to care for her needs" at 89, in April 1975. (10; 67; 128)

58

13. (COLEY): Mrs. J.M., aged 44; fibrosarcoma in right groin size of small

SERIES B, OPERABLE SERIES, SUCCESSES

	Years Traced After Onset
egg. Onset in April 1922; radium administered (no details given); surgical removal of tumor on October 3, 1922. Toxins (Parke-Davis XIII) given for several weeks; complete recovery, no recurrence. In good health except for gastric ulcer 1928; hypertension, cerebral hemorrhage 1955 due to severe cerebral arteriosclerosis of several years duration; died myocardial infarction May 18, 1959 at age 81. (10; 67)	37
14. (LILIENTHAL): L.F.B., male, aged 44; spindle cell sarcoma of lower chest wall. Date of onset not recorded; 1 x-ray treatment (erythema dose); surgical removal. Toxins (Parke Davis XIII) given for 6 weeks postoperatively beginning June 10, 1924; no recurrence; lipoma developed in 1936; excised; recurred two years later; again removed. Patient had arteriosclerosis in later years and died suddenly from a heart attack on March 20, 1951. (10)	27
15. (CRAWFORD): J.P.C., male, aged 60; myxosarcoma posterior to tibia, anterior to muscles and calf of leg, size of hen's egg. Onset in November 1926; surgical removal on December 29, 1926. Toxins begun on eighth postoperative day; 19 injections in 34 days; no recurrence. Patient alive and well in 1945; died from cerebral hemorrhage on February 9, 1951. (10)	24
16. (McCREERY): M.A.J., female, aged 30; mixed spindle-cell and giant-cell sarcoma of thigh. Onset in May 1927; biopsy June 20; surgical removal June 27, 1927. Severe staphylococcus infection for 9 days; 1 radium pack treatment; severe skin reactions. Toxins (Parke Davis XIII) begun; in 60 days received 16 intramuscular injections; recurrence in November 1927; wide excision; more toxins intravenously for 6 weeks; (patient was interned at Bellevue during her illness); no further recurrence. Radiation menopause in 1944 for menorrhagia due to endometrial polyps; thyroidectomy in 1946 for cystic adenoma; small basal-cell carcinoma excised from forehead in 1954. Patient in excellent health in 1975. (10; 67)	48
17. (COLEY): O.C., female, aged 10½; neurogenic sarcoma of fascia lata. Onset in October 1933; surgical removal November 11, 1933; 3 radium pack treatments (15,000 mch.) Toxins begun the day before first radium treatment; injections given for nearly two years. Acute appendicitis in September 1935; given anti-peritonitis serum, causing severe serum shock. Married in 1949; 2 children; no recurrence; in very good health until November 1974, when profuse menses occurred due to leiomyoma uteri; abdominal hysterectomy, salpingo-oophorectomy, December 5, 1974; complete recovery; only problem hypertension; alive and well June 7, 1975. (10; 67)	48

SERIES B, OPERABLE SERIES, SUCCESSES

Years Traced
After Onset

Recurrent tumors (18 cases)

18. (COLEY): Mrs. D.L., aged 40; thrice recurrent sarcoma of cheek. Onset June 1897 following blow on left side of face; excision; prompt recurrence; second operation; recurrence. Toxins (Buxton VI) given for third recurrence; complete regression; no further recurrence. Patient alive and well in autumn of 1917; not traced thereafter. (10; 30; 51; 128) 20
19. (COLEY): Male, aged 6; thrice recurrent spindle cell sarcoma of palm of hand, with axillary metastasis. Onset in 1898; excision, then amputation of ring and little fingers and metacarpals; recurrence quickly followed each operation; in the autumn of 1899 an axillary metastasis developed and was removed. Toxins (Buxton VI) then given for 3 months; no further recurrence or metastasis by 1901. (31) 3
20. (MATAGNE): Female(?) aged 36; sarcoma of left breast. Date of onset not stated. Removed surgically in 1907; rapid recurrence. Toxins given locally *prior to second operation*; no further recurrence. Patient well and free from disease in 1913. (126) 6
21. (COLEY): Miss K., aged 22; 4 times recurrent sarcoma of breast. Date of onset not recorded; 4 operations by Kammerer had been followed each time by rapidly growing recurrent tumors. Toxins (Tracy XI) started in July 1906, for treatment of 4th recurrence; 2 small masses then excised; a final small recurrent tumor also removed; toxins continued by family physician; no further recurrences. Patient well in 1931. (51; 67) 25
22. (COLEY): E.M.A., male, aged 46; recurrent mixed-cell sarcoma of triceps muscle. Onset, September 1907; excision, October 1907; prompt recurrence; 2nd surgical removal, November 1907. December 10, 1907, toxins (Tracy XI) for three weeks; did not prevent 2nd recurrence. Larger doses of toxins, *some into tumor*, caused marked regression and softening; necrotic tumor evacuated; toxins resumed for 3 weeks; another recurrence; not controlled; disarticulation of shoulder joint; no further recurrence. Patient died from chronic nephritis and uremia on June 21, 1913. (7; 67; 127) 6
23. (GREEN): J.McG., male, aged 31; recurrent ulcerated myxosarcoma of dorsal surface of right wrist, involving ulna. Onset, January 1907; enucleation, December 15, 1907; prompt recurrence, ulceration. July 21, 1907, toxins (Tracy XI) injected daily into tumor for a week; no effect; amputation at elbow February 1, 1908; more toxins for 4 months; no further recurrence of sarcoma. Carcinoma of stomach developed, causing death on May 26, 1923. (7; 10; 95) 17

SERIES B, OPERABLE SERIES, SUCCESSES

Years Traced
After Onset

24. (LUTMAN): J.S.K., male, aged 17; 6 times recurrent sarcoma of nasopharynx. Onset in 1906; 6 operations; removal difficult each time; rapid recurrence after each operation. Toxins (Tracy XI) given for 3 months in treatment of 6th recurrence; some injections directly into the growth or periphery; tumor then removed surgically with little difficulty (had become necrotic during toxin therapy); no further recurrences. Patient married and had 6 children, 19 grandchildren and 11 great grandchildren by 1975; in excellent health except for prostatectomy July 27, 1947, for benign prostatic hypertrophy, and following the death of his wife in 1966, a perforated gastric ulcer in 1967; he remarried in 1968. Last traced in very good health at age 85 in March 1975. (10; 51; 67)

69

25. (OLIVER): Female adult; twice recurrent spindle cell sarcoma of left axilla with supraclavicular metastases. Exact date of onset not stated; operations February 1907, January 1909 and April 1909. Toxins (Tracy XI) given after 3rd operation for 3 months. Metastatic masses that had reappeared after 3rd operation and were present when toxins were begun, disappeared 4 weeks after toxins were stopped; no further evidence of sarcoma. Tuberculous nodules developed along the trapezius; they were removed, along with "cheesy" tonsils; no further recurrence of sarcoma when case was reported in October 1911. (161)

5

26. (BARNES): B.M., female, aged 12; recurrent small spindle cell sarcoma of muscle and fibrous tissue over proximal humerus. Onset September 1908; excision January 30, 1909; recurrence; 2nd excision February 6, 1910. Toxins (Tracy XI) begun 6 weeks later; patient contracted typhoid fever; 2nd recurrence of less rapid growth; excised November 17, 1910. Toxins resumed; further small recurrence also of less rapid growth; excision July 3, 1911; toxins continued with intervals of rest through part of 1912 for about 2 years; no further recurrence until February 1916; excision; more toxin therapy. Patient married and had 1 child; later pulmonary tuberculosis developed, also severe pneumonia. Death in March 1919, apparently due to tuberculosis; no further evidence of sarcoma. (10; 51, p. 120; 67)

10½

27. (COLEY): Mrs. H.W., aged 25; extensive recurrent fibrosarcoma of right arm, apparently of fascial origin, beginning to involve the periosteum of the humerus. Onset in April 1909; lesion removed surgically in November 1910; rapid recurrence of tumor 18 cm. long involving ¾ of circumference of arm; considerable limitation of motion at elbow. Toxins (Tracy XI) injected into tumor, both arms and both pectoral regions; toxin therapy continued at home by family physician; total duration about 12 months; growth regressed except for fibrous stroma. Patient alive and well in 1918. (51; 128)

9

SERIES B, OPERABLE SERIES, SUCCESSES

Years Traced
After Onset

28. (COLEY AND MURRAY): Mrs. O.S., aged 43; recurrent spindle cell sarcoma of the parotid. Onset in the spring of 1909; excision June 1909; x-ray therapy in July and August 1909; recurrence; supraclavicular and cervical lymphadenopathy; toxins (Tracy XI and XI F) given for 8 to 9 months with intervals of rest; complete recovery; no further recurrence. Patient in good health next 47 years, except for herniotomy and fractured femur. For several years prior to death, a small nodular mobile tumor was present in the 1909 operation scar. Died from acute auricular fibrillation on March 22, 1956, at 90 years of age. (10; 51; 67) 47
29. (BUTEAU): W.K.S., male, aged 47; recurrent large round-cell sarcoma of the popliteal region. Onset September 15, 1912; incision and drainage on October 31, 1912; amputation on January 18, 1913; recurrence in stump; debridement. Toxins (Tracy XI) given for 9 months thereafter with intervals of rest; lesion in stump broke down again early in 1918 and was incised; toxins resumed in April 1918; given for another year; no further recurrences. Patient died on May 24, 1935 from chronic myocarditis. (7; 10) 23½
30. (COLEY): R.N.G., male, aged 28; recurrent myxosarcoma (neurogenic) of leg in region of the calf. Onset early in 1916; excision, recurrence 2 years later; growth removed with great difficulty when 8 by 13 cm. in size; extensive wound fulgurated. Toxins (Tracy XI) started on third postoperative day; given intramuscularly for 9 months; marked febrile reactions and chills; no further recurrence. Patient married and had 3 children; well for the next 27 years; died from carcinoma of the prostate, September 5, 1945. (7; 10; 128) 29
31. (COLEY): J.St.A., male, aged 57; thrice recurrent neurogenic sarcoma of flexor surface left forearm. Onset in fall of 1916; primary tumor excised; recurred locally in 9 months; excised; again recurred in 9 months; was size of walnut when removed; third recurrence; 20 x-ray treatments, January to September 1919; exploratory operation in October 1919. Toxins (Tracy XI) begun October 18, 1919; 23 injections in 34 days; radium pack treatment (8,250 mch.), bare tubes inserted; slight improvement; amputation at upper third of humerus; post operative infection; drainage for 5 weeks; more toxins for 2 months; no further recurrence. Patient died from myocarditis, chronic nephritis and influenza on February 10, 1929. (67; 128) 13
32. (OCHSNER): Male, aged 10; recurrent sarcoma of antrum. Date of onset not stated. Primary tumor removed surgically in Seattle; recurrence; prognosis practically hopeless; second operation in 1917. Toxins (Parke Davis XIII) given postoperatively for a few months; no further recur-

SERIES B, OPERABLE SERIES, SUCCESSES

	Years Traced After Onset
rence. Patient in good health when last traced in 1932. (10; 67)	15
33. (OCHSNER): E.H., male, aged 18; small round cell sarcoma of the left breast, recurrent in upper angle of scar over pectoralis major. Onset in April 1915; primary growth removed in July 1915; recurred 2 years later; second operation November 23, 1917. Toxins (Parke Davis XIII) given intramuscularly above left breast and in left arm; no further recurrence. Patient in good health in 1958. (10; 67)	42½
34. (COLEY): E.R., male, aged 44; recurrent round cell sarcoma of left thumb. Onset in June 1921. Amputation of proximal phalanx October 24, 1921; recurrence in posterior end of metacarpal bone. Toxins (Parke Davis XIII) given for 6 months; recurrent tumor regressed completely; no further recurrence. In 1942 or 1943 carcinoma of the stomach developed; operation on August 21, 1943, in Massachusetts; died from postoperative shock. (7; 10; 67)	22
35. (GREY TURNER): M.I.N., female, aged 13; recurrent alveolar sarcoma of vastus externus muscle of right thigh. Onset about October 1, 1920; tumor was size of large orange when first widely excised. Two doses of toxins given after this operation; no effect. Rapidly growing recurrent lesion in November 1922; extensive removal of tumor measuring 13 by 20 cm., December 19, 1922. Toxins (Parke Davis XIII) given postoperatively; 15 injections in 7 weeks; excellent recovery; no further recurrence. Patient alive and well in 1975. (10)	54½

INOPERABLE FAILURES, SERIES C: 67 CASES

An analysis of failures in the toxin therapy of inoperable sarcoma of the soft tissues (exclusive of lymphosarcoma) has been made. Some of these patients whose treatment with mixed toxins was considered a failure, lived for 22, 19, 15, 10 and 5 years after onset of the disease, and almost as many years after toxin therapy was started. It may perhaps be said that we set our sights too high. Some of these cases should be considered as at least partial successes, even if the patients died with cancer. A monumental work by Pack and Ariel (163) speaks of a woefully small five-year cure rate. Actually it would have been better to have considered these patients as five-year survivals without cancer. It can be definitely stated that a patient with sarcoma rarely dies from the initial lesion or from a local recurrence, but from metastases.

Many factors besides those under direct control of the physician may change the picture radically. For example, there is general agreement that accidental injury or incisional biopsy can initiate a phase of intensive growth in a previously dormant tumor. With rapid growth, an invasion of the luxuriant blood supply by tumor emboli is a simple matter.

Fourteen of the cases were terminal when the treatment was begun, and 11 patients were already cachectic or in poor general condition. Although these may be counted as failures, they should perhaps be considered as instances of "compassionate" therapy. Some of the patients listed in the category of "failures" were treated with a potent product, but many received the weak toxins available at the time of treatment. In some, the potent toxins were used for an extremely short period. In a few, a potent product was used for a short time, and then resumed after a recurrence had taken place. Had the toxins been used continuously without interruption for six months or more, many more permanent results could have been produced. The vital importance of duration of therapy is now more clearly recognized. (152; 153) Early discontinuance of therapy was a great mistake inasmuch as complete regressions were recorded after persistent use of the potent toxins, even for tumors that had recurred after cessation of initial therapy. Incomplete regression was noted in many cases. In 9 patients there was extensive necrosis and sloughing of the tumors, which contributed to, and in some cases caused the death of the patient. A few patients died of toxemia due to absorption of large amounts of necrotic tumor tissue. These cases suggest the need for establishing drainage surgically or for incomplete removal of some of the tumor in order to avoid these problems.

Two of the patients died from hemorrhage because a collapse of the sarcomatous tissue resulted in bleeding from a large vessel that was involved in the growth.

Some patients received large amounts of radiation before or during toxin

therapy. Critical attention has been increasingly directed to the adverse effects on the body of excessive irradiation. These include damage to normal tissue and function, diminished immunologic and hematologic integrity, and even subsequent development of other neoplasms, including leukemia. Experimental and clinical studies indicate that either prior bacterial infections or injections of microbial products such as Coley toxins, or *Corynebacterium parvum*, can protect the body against the deleterious effects of irradiation. What is also of great importance is that a potentiated response of the tumor to radiation is achieved by prior or concomitant bacterial vaccine therapy, thus making a smaller radiation dose effective. (1; 12; 104; 133; 137-152; 181; 203)

Similar protective effects have recently been noted by clinicians using bacterial vaccines before or during chemotherapy, with potentiation of the response to smaller doses. Children in Uganda with endemic infections also respond very dramatically to very small amounts of chemotherapy. (6)

In some instances the toxin treatment was associated with marked relief of pain, although the final result was a failure. A few patients in whom treatment was a failure died from such causes as typhoid fever, radiation necrosis, and uremia due to blockage of the ureters by tumor tissue.

In a certain number of patients it seemed that toxins prolonged life beyond the expected survival period. One patient lived 22 years after toxin therapy was started, and several others lived for six years afterwards.

SERIES C: ANALYSIS OF FAILURES—67 CASES OF INOPERABLE SARCOMA OF THE SOFT TISSUES

STAGE OF THE DISEASE WHEN TOXINS WERE BEGUN:

Primary inoperable, 15 cases: #3, 6, 17, 18, 19, 24, 27, 37, 38, 41, 46, 47, 51, 53, 56

Recurrent, 28 cases:

1 seven times, #7

3 five times, #1, 11, 21

5 three times, #4, 12, 45, 48, 49

19 once, #5, 10, 13, 14, 15, 16, 22, 26, 34, 36, 37, 41, 43, 44, 55, 59, 62, 65, 67

Multiple primary, 1 case: #30

Metastases present, 22 cases: #1, 2, 3, 9, 10, 12, 13, 21, 28, 30, 33, 37, 42, 52, 54, 57, 59, 60, 61, 65, 66, 67

Terminal, 14 cases: #6, 9, 10, 14, 17, 20, 37, 40, 60, 63, 64, 65, 66, 67

Cachexia present or general condition poor, 11 cases: #15, 24, 25, 30, 34, 46, 52, 54, 55, 62, 63

OTHER TREATMENT PRIOR TO TOXINS:

Radiation: 11 cases:

#40: x-ray therapy ineffective

#46: x-ray therapy twice weekly for 4½ months; tumor doubled in size

#56: radium therapy (gold needles); diathermy, fulgurations (temporary benefit)

#57: x-ray therapy following excision did not prevent recurrence

#58: x-ray therapy (46 treatments); recurrence increased rapidly during treatment

#59: x-ray therapy; no benefit

#61: radium pack (8000 mch.), x-ray therapy (4 treatments) given 12 days after toxins; no decrease in size of tumor during radiation

#63: x-ray and radium therapy seemed to aggravate the condition

#64: x-ray therapy (many courses), also radium therapy (5 treatments over 15 month period) did not prevent recurrence but destroyed eyelashes and brows

#65: x-ray therapy (many courses to various metastatic areas totalling 32,024r); patient's natural resistance to the neoplasm was remarkably high (died 8½ years after onset); an unusual case

#66: x-ray therapy (4311 r) and radium therapy (1100 mch.) did not control the disease

SERIES C, ANALYSIS OF FAILURES

Surgery: 56 cases:

- 1 – six operations: #7
- 3 – five operations: #1, 11, 21
- 2 – “great many”, “several operations”: #8, 60
- 7 – three operations: #20, 31, 33, 35, 45, 49, 56
- 10 – two operations: #4, 23, 25, 35, 40, 42, 59, 62, 63, 67
- 11 – primary growth removed, usually completely; recurrence or metastases untreated or irradiated: #2, 10, 26, 29, 34, 36, 43, 44, 55, 57, 64
- 7 – incomplete removal of primary tumor: #5, 13, 19, 31, 41, 48, 65
- 11 – explorative and/or biopsy: #6, 28, 30, 34, 37, 38, 46, 47, 50, 52, 54
- 3 – amputation: #28, 31, 33
- 1 – electrolytic needles: #24

OTHER TREATMENT DURING OR AFTER TOXIN THERAPY

Radiation: 9 cases

- #21: x-ray for 6 weeks after 2 courses of toxins; *complete regression*
- #23: x-ray (5 treatments about 2 weeks after toxins begun caused very rapid increase in growth)
- #25: x-ray thrice weekly during toxin therapy (often same day); *very rapid improvement*
- #28: x-ray (30 treatments) 5 weeks after toxins
- #31: x-ray (32 treatments) after ulcer healed, during toxin therapy
- #33: x-ray, 5 weekly (begun a week after toxins); little improvement
- #54: radium packs (5 treatments) between 1st and 2nd course of toxins; *marked improvement before and after radiation*; sudden death due hemorrhage
- #55: x-ray (3 treatments) before, radium packs (2 treatments) during toxin therapy
- #63: x-ray before, radium pack after (48,000 mch.); patient lost ground rapidly; much radiation sickness

Surgery: 10 cases

- 3 – external carotids tied: #19, 21, 23
- 1 – drainage established surgically: #20
- 1 – surgical removal (3rd operation); tumor much less vascular than before: #35
- 2 – incomplete removal: #1, 9
- 1 – metastases, primary tumor removed at 2 operations 2 weeks after toxins: #9

SERIES C, ANALYSIS OF FAILURES

- 1 - cicatrix removed after 2nd course of toxins; no evidence of tumor:
#13
- 1 - neck dissection after toxins; patient died on operating table: #44

EFFECTS OF TOXIN THERAPY

Complete regression: 8 cases

- #7: potent toxins 4 weeks; too rapid absorption of necrotic tumor, persistent nausea
- #8: potent toxins 3½ years intermittently
- #12: potent toxins 3 months; resumed briefly later
- #13: potent toxins 3 months; resumed after further recurrence; again regressed
- #22: potent toxins 2 months; resumed after recurrence
- #25: potent toxins, 3 courses, with x-ray; later weak toxins; total one year
- #40: potent toxins, 3 courses i.m.; at first marked, later no reactions
- #62: weaker product daily at first i.m. and i.t.; total 7 months

Incomplete regression: 29 cases:

- #1, 2, 3, 4 (marked), 6, 16, 18, 19, 26, 28, 30, 31, 33, 35, 37, 47, 48, 49, 52, 53, 54, 56, 57, 58, 59, 61, 63, 64, 67

Temporary arrest of growths, 9 cases:

- #11, 21, 31, 32, 41, 43, 44, 46, 65

Marked relief of pain, 12 cases:

- #13, 15, 23, 24, 26, 28, 37, 41, 53, 59, 64, 67

Cessation of hemorrhage, 1 case:

- #19

Necrosis or sloughing of tumor, 9 cases:

- #6, 12, 14, 15, 18, 19, 29, 30, 34

Little or no apparent benefit from toxins, 12 cases:

- #5: only 5 doses
- #10: recurrence (28 × 38 cm), axillary involvement; toxin given i.m. remote from tumor
- #12: terminal; only 7 doses in the 15 days before death

SERIES C, ANALYSIS OF FAILURES

- #20: probable lung involvement; primary tumor 13×20 cm.; toxins given only 9 weeks (appetite remained excellent)
- #27: only 2 doses; patient died after second dose given intra-abdominally
- #30: terminal; multiple primary tumors, metastases, arteriosclerosis and chronic nephritis; only 21 doses of weak product injected into tumors
- #33: weak product given 6 weeks during x-ray therapy
- #37: terminal; 21 doses in 42 days
- #38: only 2 doses; child, aged 2, died 3 days after 2nd dose
- #55: weak product; very small doses intermittently after radium and x-ray
- #60: terminal; weak product; only 6 small doses
- #66: terminal uterine tumor; multiple metastases (shock); 4 doses toxins, little reaction; died 3 days after last dose

Complications

Death during or soon after toxin therapy:

- 1 – typhoid: #4
- 5 – sepsis: #5, 14, 26, 29, 30, (all prior to 1901)
- 1 – necrosis; collapse of tracheal wall: #53
- 2 – necrosis; hemorrhage: #45, 54
- 1 – radiation necrosis: #8
- 1 – uremia due to blocked ureters: #67

Toxemia due to absorption of large amounts of necrotic tumor: 7 cases:

#5, 6, 14, 34, 40, 43, 64. These cases suggest the need for establishing drainage surgically, or for incomplete removal of the tumor

Late survivals: 9 cases in which it would appear that the toxins prolonged the patient's life beyond the expected survival period:

- Myxosarcoma (#8): about 21 years after toxins begun (22 years after onset)
- Tendon sheath (#12): 4 years after toxins begun (5 years after onset)
- Thigh, groin (#13): about 2 years after toxins begun (4 years after onset)
- Uterus, broad ligament (#15): about 6 years after toxins begun (6½ years after onset)
- Thigh (#16): about 2 years after toxins begun (21 years after onset)
- Neck; metastases (#21): about 2½ years after toxins begun (15 years after onset)
- Sarcoma of ovary (#22): 4 years after toxins begun
- Sarcoma of chest wall (#31): 6 years after toxins begun (9 years after onset)
- Angiosarcoma of nasopharynx (#42): 5 years after toxins begun (10 years after onset)

This page left blank intentionally.

TABLE 1. SERIES C: INOPERABLE FAILURES: 67 CASES

Physician References	Sex Age	Histologic Diagnosis Extent of Disease	Other Treatment Before or After Toxins	Type of Toxin Used; Site & Duration	Immediate Result	Final Result
1. Lloyd & Coley (14, 17, 19, 67)	F 20	spindle cell sarcoma (tendon sheath?) palm of hand, 5 times recurrent, with axillary metastases	5 operations prior to toxins; incomplete curettage during toxin therapy June 1894	Type IV, spring 1893; stopped during summer; resumed Oct. 1893, i.m. or near growth in hand; treated as ambulatory case by Lloyd; hospitalized by Coley	when toxins given steadily in adequate dosage, tumor decreased; after incomplete curettage patient gained 20 lbs; well 15 mos.	further recurrence; amputation; died of brain metastases, 7 yrs. after onset (2½ yrs. after toxins begun)
2. Coley (27)	M 48	myxosarcoma thigh muscles, recurrent, far advanced multiple tumors	surgical removal	Type IV for 4 wks. June 1894; site not stated	temporary decrease; later rapid growth	death 4 mos. after toxins begun
3. Coley (7; 67; 128)	F 48	sarcoma face, orbit, with exophthalmos, extensive involvement cervical lymph nodes	none	Buxton V & VI, 28 in 58 days; site?	some regression	died 2 yrs. after onset
4. Coley (26; 128)	F 7½	round and spindle cell sarcoma ovary, bilateral twice recurrent; trauma	surgical removal of primary and first recurrence	Buxton V, 10 doses in 3 wks.; site?	considerable decrease in size	contracted typhoid fever; died 6 wks. later
5. Coley (7; 67; 128)	M 43	recurrent round cell sarcoma thigh; onset 4 mos. after trauma	surgical excision (incomplete)	Buxton V, 5 doses in 5 days begun 10 days after operation; site? little reaction	wound healed	death 7 mos. after operation; "septic poisoning and sarcoma"
6. Andrews & Smith (2)	M adult	very extensive sarcoma iliac fossa extending 2/3 of way to umbilicus	aspiration biopsy; later abscess opened freely irrigated with hydrogen peroxide	Buxton VI i.m. (ineffective); then into tumor every 48 hrs.; duration?	tumor softened and broke down; immense abscess formed; <i>much of tumor became necrotic</i>	life prolonged but died of exhaustion 8 mos. after onset
7. Rumbold (17; 31; 51)	F adult	times recurrent round cell sarcoma of breast	6 operations prior to toxins	Buxton VI for 4 wks.; local injections?	patient weak; persistent nausea; <i>complete regression</i>	internal metastases developed; death (autopsy)

8. Coley (51; 193)	M 37	infiltrating myxosarcoma chest wall; many times recurrent	many operations; whole anterior chest scarred	Buxton VI for 3½ yrs. with intervals of rest; site?	complete regression	well 8 yrs.; further recurrence; toxins resumed; biopsy; 12 x-ray treatments; necrosis whole upper sternum; death 4 mos. later
9. McArthur (19; 51)	F 5½	terminal round cell sarcoma antrum of Highmore, nares, nasopharynx; severe exophthalmos; cervical metastases; bedridden	stimulants, tonics, rectal feeding; after 2 wks. of toxins, cervical nodes removed; 3 wks. later primary tumor removed	Buxton VI every 48 hrs. for about 5 wks.; resumed after recurrence developed	tumors became operable; severe exophthalmos diminished; gained 32 lbs.; recurrence after toxins stopped; temporary improvement when resumed	disease not controlled; death 2 mos. after last injection
10. Coley (67; 128)	M 45	ulcerated recurrent spindle cell sarcoma scapular region 28 × 38 cm. with axillary involvement	surgical removal of primary tumor; recurrence untreated	Buxton VI remote from tumor for 6 wks.	slight regression; no marked effect (compare with Case 11 in Series A, inoperable successes)	died 2 months later
11. Coley (19; 128)	F 62	5 times recurrent myxosarcoma abdominal wall, iliac region 23 × 24 cm.	5 operations prior to toxins	Buxton V & VI; site? 39 doses in 3 mos.	temporary arrest	death 20 mos. after toxins begun, 12 yrs. after onset
12. Coley & Meixell (19; 25; 67; 128)	F 20	sarcoma tendon sheath hand 3 times recurrent with metastasis to axillary node; trauma	2 operations prior to toxins	Buxton V & VI for 3 mos. in arm (i.m.) resumed later for brief period	complete disappearance; perfect function; 5 mos. later axillary metastasis excised; marked necrosis	later, another recurrence; amputation; no further toxins, disease generalized; death 5 yrs. after onset

TABLE 1, SERIES C, INOPERABLE FAILURES, (cont'd)

Physician References	Sex Age	Histologic Diagnosis Extent of Disease	Other Treatment Before or After Toxins	Type of Toxin Used; Site & Duration	Immediate Result	Final Result
13. LaFetra & Coley (25; 26; 30)	F 48	recurrent spindle cell sarcoma thigh, groin, edema entire extremity; trauma	incomplete surgical removal; large mass in groin not touched; old scar removed after 2nd course of toxins;	Buxton VI begun 11 wks. after operation, given 3 mos.; resumed after further recurrence; site?	pain ceased; <i>complete regression; edema subsided, leg normal</i> ; recurrence 7 mos. later; <i>another regression after toxins resumed</i>	later, another recurrence no further treatment; death about 6 yrs. after onset
14. Harris (25)	F 31	terminal recurrent large round cell sarcoma ovary size of coconut causing obstruction, extreme distention	panhysterectomy for primary tumor; recurrence untreated	Buxton VI s.c., increased to 40 minims; very little reaction; about 18 in 16 days	wound opened on 4th day; almost normal bowel movements; in 3rd wk. tumor became gangrenous; fecal matter discharged through wound	septic absorption from immense sloughing tumor; death about 4 wks. after toxins begun
15. Willy (10; 51; 67)	F 42	recurrent mixed cell sarcoma uterus, broad ligament size of coconut, with extensive adhesions, hemorrhages	laparotomy; prognosis "few wks."; arsenic orally; pyoktanin injected into tumor	Buxton VI; later weaker Parke Davis IX, given spasmodically for 6 yrs. by husband (physician); injections into tumor (cervical area) more effective	<i>prompt complete regression in 10 days</i> ; recurrence after toxins stopped; <i>another regression when resumed; gained 22 lbs.</i>	disease controlled 6 yrs.; patient returned to Europe; another attempt at removal; died during surgery
16. Coley (37)	M 49	spindle cell sarcoma thigh recurrent 9 mos. after operation	extensive surgical removal year after onset; later hip-joint amputation	Buxton VI for 3 mos.; site?	marked regression at first; growth remained stationary, then increased again	further recurrence; died 4 yrs. after onset
17. Nicholson (156)	F 46	terminal round cell sarcoma uterus both broad ligaments; 32 lb. weight loss	none; terminal case	Buxton VI every 48 hrs. for 15 days; some reaction; site?	no apparent benefit	death 13 days after first injection

18. Meriwether (131)	F 33	small round cell sarcoma apex of Scarpa's triangle, foul discharge, much pain; cervical node metastasis	mass lanced, then grew rapidly; patient had left-sided pleurisy	Buxton VI, briefly (patient objected); resumed; injected into primary tumor	decreased 50%; after toxins stopped primary tumor increased; <i>cervical metastasis disappeared during further toxin therapy</i> , primary tumor did not; another tumor appeared on left arm; <i>regressed during continued toxin therapy</i>	disease not controlled; patient emaciated; death 5 mos. after toxins begun
19. Coley (29; 128)	M 42	recurrent round cell sarcoma nares, antrum, of very rapid growth; frequent hemorrhages	incomplete surgical removal; after toxins, external carotid tied, curettage	Buxton VI in or near growth (40 in 73 days) good reactions; 2 more courses after recurrence	<i>pronounced regression; hemorrhages ceased; sloughing of tumor in nasal cavity</i> ; recurrence when toxins stopped	slow, steady increase; death from hemorrhage at attempted removal (another hospital)
20. Coley (67; 128)	M 25	terminal round cell sarcoma thigh 13 x 20 cm.; trauma, strain	exploratory operation curetted twice; sinuses irrigated with potassium permanganate; later, surgical drainage	Buxton VI 8 days after 2nd curettage; given 9 wks.; site? (fever prior to toxins)	no apparent benefit, but appetite remained remarkably good	pulmonary symptoms; death 4 mos. after toxins begun
21. Coley (33; 34; 55; 128)	M 70	5 times recurrent very vascular round cell sarcoma neck size of orange, posterior to scalenus anticus muscle; metastases to femoral, axillary, right cervical lymph nodes	5 operations; left external carotid tied after initial course toxins; later x-ray therapy (6 wks); complete regression of tumors in neck and axilla in 4 wks.	Buxton VI; only 1 reaction; given 3 wks. resumed for 11 days (i.m.)	at first slight improvement; later no effect; patient discouraged; bored with hospital life	further metastases in groin responded to further radiation; death (?) from cerebral thrombosis 15 years after onset, 2 years after toxins
22. Porter (51; 100)	F 40	round cell sarcoma lt. ovary recurrent in pelvis	?	Buxton VI for 2 mos.; site?; toxins resumed when recurrent tumors developed; type? site?	<i>complete disappearance</i> ; patient remained well 4 yrs.	recurrence not controlled; date of death not stated

TABLE 1, SERIES C, INOPERABLE FAILURES, (cont'd)

Physician References	Sex Age	Histologic Diagnosis Extent of Disease	Other Treatment Before or After Toxins	Type of Toxin Used; Site & Duration	Immediate Result	Final Result
23. Coley (33; 67)	M 25	twice recurrent round cell sarcoma parotid	2 operations prior to toxins; later external carotid tied; x-ray therapy	Buxton VI for 3 wks. in small doses; site?	at first, slight regression and <i>considerable relief of pain</i> ; later, no effect	death 6 mos. after onset
24. Emerson (82)	F 64	spindle cell sarcoma tonsil; 28 lb. weight loss; 5 bloody discharges from lt. breast (patient obese)	tumor on forehead destroyed by caustic 4 yrs. previously; electrolytic needles in tonsil tumor; later several x-ray treatments	Parke Davis IX or Buxton VI in tumor or arm twice weekly for 2 mos.; after recurrence toxins resumed (in arms, poor absorption)	patient gained 25 lbs.; only 1 more bloody discharge from breast; general health improved	metastases developed; patient failed rapidly after toxins stopped; death 17 mos. after onset
25. Coley (36; 37; 40; 46; 67; 128)	M 16	round cell sarcoma chest wall, necrosis 8th and 9th ribs; onset following pleurisy with effusion	necrotic ribs; gelatinous masses partially removed; x-ray therapy thrice weekly same day as toxins; 2d curettage (recurrence); profuse hemorrhage	Buxton VI for 2 mos. in region of wound; moderate to good reactions; 3½ mos. later Parke Davis IX, 13 doses in 40 days; no reaction; 3rd course, 97 doses in 6 mos.	<i>complete regression; patient in excellent health; gained 25 lbs.</i> ; then local recurrence	disease progressed locally; death 2½ yrs. after onset
26. Shield (51; 176)	F 44	myeloid sarcoma breast recurrent in scar and beneath clavicle	mastectomy; recurrence untreated	Lister Institute VIII, large doses into vascular tumor mass; some severe reactions; toxins given about 17 days	<i>marked relief of pain; larger growth disappeared in 17 days; smaller became half necrotic; mass under clavicle smaller</i> ; 2 days after last dose, staph. pyemia	death from pyemia in 48 hrs.; autopsy; <i>all tumors had disappeared or were necrotic</i> ; (toxin used was sterile)
27. Battle (3)	not stated	spindle cell sarcoma abdominal peritoneum	not stated	Lister Institute VIII i.m. in arm; 1 into abdominal tumor	abdominal measurements decreased 2.5 cm.	patient died after intraabdominal dose
28. Rigby (67)	F 14	spindle cell sarcoma aponeurosis left knee, involving periosteum, recurrent in amputation flaps; metastases to ilium	exploration; biopsy; amputation; x-ray (30 treatments) begun 5 wks. after toxins; 13 more during 2nd course of toxins	Lister Institute VIII 5 in other leg, rest into tumor; 47 in 120 days; good febrile reactions; toxins resumed after 3½ mos.	<i>gradual regression; immediate cessation of pain</i> (before x-ray begun); pain increased when toxins stopped and ceased when resumed	disease not controlled; mass in right groin; death 12 mos. after toxins begun, 4 yrs. after onset

29. Semken (67)	young male	recurrent extensive mixed cell sarcoma fascia of pectineus muscle over proximal femur, involving periosteum	primary tumor removed surgically; recurrence untreated	Parke Davis IX, later Buxton VI; 24 doses in 76 days, usually into tumor but a few into abdominal wall s.c.; reactions more marked with VI than with IX	tumor began to break down; patient became septic	disease not controlled; death 4½ mos. after toxins begun
30. George & Warthin (94)	M 73	large spindle cell sarcoma right forearm; axillary metastasis; also had adenocarcinoma pylorus, polyp on cardia, myomata of stomach wall; condition hopeless; also arteriosclerosis, chronic bronchitis and nephritis	incisional biopsy, arm tumor; no other therapy	Parke Davis IX into tumor every 24 or 48 hrs. for 41 days	<i>large areas necrotic at sites of injection, but tumor grew very rapidly peripherally; involved whole arm; abscess; septic poisoning</i>	death 3½ mos. after toxins begun; autopsy showed <i>extensive necrosis in sarcoma and in metastasis</i>
31. Parlett (7; 67; 128)	M 26	sarcoma chest wall, pectoral muscles to clavicle; metastasis 4th finger rt. hand, recurrent tumor on hand	incomplete removal twice; amputation of finger; x-ray treatments during toxin therapy; no effect; severe x-ray burn	Parke Davis IX into tumor and shoulder for 15 mos.; resumed 3 mos. later for about 4 mos. with more x-ray therapy; final course	no improvement at first; <i>another recurrence responded to toxins injected into or near tumor masses; in good condition; disease controlled over 6 yrs.</i>	death pulmonary metastases 9 yrs. after onset, 6 yrs. after toxins begun
32. Underson (67)	F young adult	spindle cell sarcoma post orbital region, involving left naris and roof of mouth	biopsy; x-ray treatments after toxins	Parke Davis IX daily, usually in shoulder muscle or cheek, for about 3 mos.	<i>growth ceased for about 4 mos.</i>	disease not controlled; death about 9 mos. after toxins begun
33. Coley (67; 128)	M 56	small spindle cell sarcoma deltoid muscle of shoulder, twice recurrent in distal clavicle, scapular region, ribs, cervical lymph nodes (trauma)	biopsy; excision; interscapulothoracic amputation; x-ray therapy week after toxins (4 a week); dissection of recurrent tumor	Parke Davis IX locally every 24-48 hrs. in large doses; little reaction; given during radiation for about 6 wks.	little improvement	death 6 mos. later

TABLE 1, SERIES C, INOPERABLE FAILURES, (cont'd)

Physician References	Sex Age	Histologic Diagnosis Extent of Disease	Other Treatment Before or After Toxins	Type of Toxin Used; Site & Duration	Immediate Result	Final Result
34. Bull (42; 67)	M 34	recurrent extensive vascular mixed cell sarcoma inner proximal thigh; 20 lb. weight loss, much pain, very weak, bedridden	exploration; large hematoma evacuated; spurting hemorrhage 3 days later; tumor removed; rapid recurrence untreated	Tracy X alternately into tumor and remote from it; toxins stopped because Dr. Bull became ill; no other physician available to treat patient	immediate improvement; tumor broke down and rapidly drained large amounts of dark fluid; in 3 wks. mass of tumor 13 cm. in diameter separated and was easily lifted out; base clean; almost complete regression	toxemia developed; control lost; death 2 mos. after first dose
35. Green (10; 96)	M 67	twice recurrent small spindle cell sarcoma soft tissues of scapular region, primary tumor highly vascular	2 operations prior to toxins; 3rd after toxins (much less hemorrhage; tumor anemic, degenerated)	Tracy XI into arm and tumors, 12 doses in 4 wks.; resumed after 3rd operation twice weekly for 2½ mos. into arm and back muscles	tumor less vascular, distinctly smaller; another recurrence 1 mo. after last dose of toxins; regressed slightly; inactive	lived 9 yrs. after toxins begun; died sarcoma of cervical spine at age 76
36. Green (10; 96)	F 37	recurrent small round cell sarcoma parotid region involving sternomastoid	primary tumors removed surgically; recurrence untreated	Tracy XI into arm or tumors for 2 wks.; slight reactions	after 2nd dose injected into tumor, growth softer but larger; unimproved	death 2 yrs. after onset, 6 mos. after toxins begun
37. Large (114)	M 45	very vascular round cell sarcoma postnasal region, nares occluded; bilateral optic neuritis, exophthalmos	small section removed for biopsy	Tracy XI for 1 mo.; family then stopped treatment; resumed briefly	within a month patient able to breathe through both nares; improving; severe headaches developed when toxin stopped, but were relieved when resumed	death from cerebral metastases
38. Green (10; 96)	F 2	fibrosarcoma palate and superior maxilla	incision; profuse bleeding; section removed for biopsy	Tracy XI; 2 doses into tumor	severe reaction to second dose (104°F.); normal next day but rose to 102.6°F. that afternoon; patient grew rapidly worse	death 3 days after 2nd dose; temperature 107.6°F. (no autopsy)

39. Mitchell (67; 164)	M 45	recurrent round and spindle cell sarcoma thigh, metastases to lungs, liver, kidneys and mesentery, <i>condition terminal</i>	exploration; considerable hemorrhage; area tightly packed; postoperative infection did not prevent recurrence	Tracy XI, 21 doses in 42 days; reactions 100°-104.2°F., once 105.2°F.	<i>tumor swelled and discharged large amounts of necrotic tissue</i>	disease progressed; death 5 wks. after 1st dose
40. Coley (51; 128)	F 16	large recurrent fibrosarcoma ovary, filling pelvis and lower abdomen, much weight loss, cachexia	primary tumor (6½ lbs.) removed surgically; 2nd operation merely exploratory	Tracy XI given 5 wks.; marked reactions; resumed 3 wks. later for 1 or 2 wks.; month later 3rd course, 9 doses in 21 days i.m.; no reactions	<i>complete regression in 8 wks.; toxemia from rapid absorption; diffuse pain over entire body, especially joints; patient lost 36 lbs.; anemia; some improvement with final course</i>	disease not controlled; death 6 mos. after toxins begun
41. Large (114)	M 19	round cell sarcoma postnasal region, naris, superior maxilla, all sinuses on left, extending into cranium; exophthalmos, severe pain	growth probed; severe bleeding; incisional biopsy; eye enucleated and upper jaw resected (incomplete removal of tumor)	Tracy XI started 2 wks. after surgery given for about 3½ mos.; site?	<i>toxins held growth in abeyance; no pain during therapy, excruciating pain after toxins were stopped</i>	death 2 mos. after toxin stopped
42. Rule (7; 67; 128)	M 21	twice recurrent angiosarcoma nasopharynx, lymph node metastases	two operations; 2nd recurrence untreated	Tracy XI, minute doses into chest, shoulder and pectoral muscles; no reactions; given about 6 mos.	<i>patient improved steadily; gained 20 lbs.</i>	later, multiple metastases; death 4½ yrs. after toxins begun, 9½ yrs. after onset
43. Harmer (10; 100)	M 42	recurrent fibrosarcoma thigh 12 × 13 cm.; also had osteitis deformans	exploration; mass size of orange removed; immediate recurrence	Tracy XI, every 2 or 3 days for 7 wks.; site?	growth softer but not smaller; patient suffered from absorption of necrotic tumor	rapid growth when toxins stopped; death a few weeks later
44. Boyer (10; 67)	F adult	recurrent endothelioma nasopharynx	surgical removal; rapid recurrence, x-ray therapy ineffective	Tracy XI, usually daily for 6 wks.; at first into tumor, later into muscles	growth arrested; then spread to deep cervical nodes	neck dissection attempted; patient died on operating table

TABLE 1, SERIES C, INOPERABLE FAILURES, (cont'd)

Physician References	Sex Age	Histologic Diagnosis Extent of Disease	Other Treatment Before or After Toxins	Type of Toxin Used; Site & Duration	Immediate Result	Final Result
45. Harmer (67; 100)	M 22	3 times recurrent spindle cell sarcoma thigh of rapid growth	3 operations prior to toxins	Tracy XI for 5 wks. small doses; moderate, then severe reactions; site?	tumor "broke" after 5 wks. of toxin therapy	death 7 wks. after toxins begun; sudden severe hemorrhage from large vessel involved in growth
46. Coley (10; 128; 193)	M 50	retroperitoneal spindle cell sarcoma 21 × 24 cm.; 20 lb. weight loss	exploration; biopsy; x-ray therapy twice weekly for 4½ mos.; sodium cacodylate (all prior to toxins)	Tracy XI, 14 doses in 24 days; no marked reactions; possibly continued at home briefly; site?	disease arrested temporarily	death regarded as due to carcinoma of pancreas 4 yrs. after onset of retroperitoneal mass
47. Lilienthal (10)	F 6 mos.	small round cell sarcoma left nose, upper lip	specimen removed for biopsy	Parke Davis XII daily i.m.; later, alternately into tumor and buttock; stopped during severe measles; resumed; total 6 mos.	<i>no benefit until given into tumor; then slight decrease; growth stationary during measles; afterwards growth very rapid</i>	death 11 mos. after onset
48. Coley (7; 46; 67)	F 5	endothelioma face involving left superior maxilla	incision; antiphlogistine applied; incomplete removal; KI given	Parke Davis XII into tumor; then P.D. XIIF (filtrates) alternately into pectorals for about 6 mos.	<i>tumor softer, more movable; regressed some; patient gained weight; rapid growth each time toxins stopped</i>	death 18 mos. after onset
49. Mertz (10; 67)	M 42	3 times recurrent sarcoma rt. mid-thigh involving groin, popliteal space	3 operations; 3rd recurrence untreated	Parke Davis XII into tumor masses, usually daily, slight reactions; given 6 mos.	<i>tumor masses regressed about 50%; severe pain after toxins stopped</i>	death 10 mos. after toxins stopped, 5 yrs. after onset
50. Lee (10; 67)	M 59	sarcoma cervical region (type not recorded)	biopsy	Parke Davis XII into tumor and shoulder for 4 mos.	<i>improved at first; mass much smaller; breathing better</i>	later, no benefit; death

51. Harmer (100)	M 14	sarcoma thigh invading pelvis size of melon, sloughing, trauma	none, apparently	Parke Davis XII for 7 wks. into growth	<i>some disintegration of tumor at sites of injection; no marked effect</i>	death 6 mos. after onset; pulmonary, hepatic metastases
52. Allen (10; 67)	F 42	extensive myxosarcoma abdomen and pelvis, organs covered with metastases; patient almost bedridden	exploration; some tumors removed for biopsy; 4 radium packs	Parke Davis XIII i.m. every 4-5 days for 18 mos.; very little reaction	<i>patient improved greatly; almost complete regression of tumor; then a bad fall; condition rapidly declined</i>	death 16 mos. after toxins begun
53. Grey (10)	M about 40	far advanced sarcoma posterior mediastinum; dull pressure pain; could not swallow	none?	Parke Davis XIII into deltoid muscles about 2 wks.	<i>pain relieved; patient could swallow in few days</i>	sudden death due to collapse of tracheal wall from necrosis of tumor
54. Coley & Cooper (67; 128)	M 49	very extensive retroperitoneal spindle cell sarcoma, metastases to liver, intestines, parietal peritoneum; 35 lb. weight loss	exploration; biopsy radium packs during toxin therapy (33, 021 mch.)	Parke Davis XIII, 4 a week (apparently i.m.) for 4½ mos.; no marked reactions	within 2 wks. tumor smaller and softer; <i>rapid regression, patient's general health improved markedly; gained 25 lbs.</i> ; sudden fatal hemorrhage from vessel involved in growth	death 9 mos. after onset; <i>autopsy showed all metastases above umbilicus had disappeared, also those on liver and parietal peritoneum; primary tumor necrotic</i>
55. Coley (10; 128)	F 27	recurrent mixed cell sarcoma axilla; 13 lb. weight loss (trauma)	local treatment with salves and poultices; excision; 3 x-ray treatments, also radium packs during toxins	Parke Davis XIII i.m. in very small doses; no reactions; given 8 wks. with intervals of rest	no apparent benefit	death 3½ mos. after toxins begun

TABLE 1, SERIES C, INOPERABLE FAILURES, (cont'd)

Physician References	Sex Age	Histologic Diagnosis Extent of Disease	Other Treatment Before or After Toxins	Type of Toxin Used; Site & Duration	Immediate Result	Final Result
56. Coley (7; 67)	F 50	recurrent fungating round cell sarcoma antrum, ethmoid, superior maxilla, whole lt. molar region, lt. lateral nasal septum, lt. eye closed; rt. eye divergent strabismus, pain, perforation	nasal polyps excised; tooth extracted; incision of tumor; pus drained; excision; recurrences treated with radium needles diathermy, fulguration, causing perforation	Parke Davis XIII, 20 doses i.m. and 3 i.v. in 34 days; good reactions	<i>almost immediate improvement; protruding fungating tumor largely disappeared, leaving opening at site of perforation at junction hard and soft palate</i>	disease not controlled; death 16 mos. after toxins begun
57. Cheney (7; 67)	F 45	spindle cell sarcoma of rt. leg, metastases to lt. cervical region and many large lung metastases	excision; deep x-ray therapy	Parke Davis XIII in small doses; no severe reactions; site? duration?	<i>definite improvement; much less dyspnea; general condition excellent</i>	disease not controlled; death 4 mos. after toxins begun
58. Pratt (7; 67)	F adult	recurrent fibrosarcoma distal internal third of thigh	excision; 46 x-ray treatments; recurrent tumor increased rapidly during radiation; amputation after toxins	Parke Davis XIII (usually injected remote from tumor but some into it) for about a month, with intervals of rest	<i>decrease in size; surrounding tissues became softer but tumor did not</i>	mediastinal and lung metastases; death year after toxins begun
59. Flock (7; 67)	M adult	recurrent large round cell sarcoma fascia of foot, metastases to inguinal and femoral region, some edema of leg	x-ray therapy; arch supports; operation; more x-ray for recurrence; metastases; recurrent tumor excised; 5 more x-ray, no effect	Parke Davis XIII into abdominal wall; later, into tumor or near it; 14 in 19 days; few more after 2nd course of x-ray therapy	<i>pain and edema relieved; general condition improved markedly; left inguinal metastases reduced in size; 2 new ones appeared in skin</i>	disease not controlled; death year after onset, 4 mos. after toxins begun
60. Rilling (10; 67)	M 35	terminal ulcerated spindle cell sarcoma lt. leg; abdominal and liver metastases, obstruction	numerous growths removed for biopsy	Parke Davis XIII, 6 doses in 6 days; only 1 caused a reaction	no apparent benefit	rapid increase in liver metastases; death 1 mo. after toxins begun

61. Coley (10; 128)	M 37	very extensive myxosarcoma thigh, with abdominal metastases	radium (8,000 mch.); x-ray (4 treatments) during toxin therapy; 1 more x-ray treatment later	Parke Davis XIII i.m. and i.v.; 30 in 60 days	<i>gained 15 lbs. during treatment; no regression evident until later; markedly improved temporarily; then both primary and metastatic masses increased greatly</i>	death 11 mos. after toxins begun
62. Wentz (10; 67)	F 50	extensive recurrent sarcoma breast, involving thorax below clavicle; severe pain	2 operations; plasters applied; mastectomy; improved with collodaurum, cachexia disappeared	Parke Davis XIII i.m.; later into tumor; daily at first, then every 2 or 3 days for about 7 mos.	<i>complete regression; patient well for a few months, then became ill again</i>	death from multiple metastases
63. Coley (10; 128)	F 30	twice recurrent malignant leiomyoma or fibrosarcoma sheath of rectus involving colon, bladder; nodules in scars, condition hopeless, husband a suicide due to her illness	primary tumor removed, also half of each ovary(cysts) and appendix; suspension operation; recurrence 5 mos. later; x-ray therapy aggravated it; 2nd operation for 2nd recurrence; radium (48,000 mch.)	Parke Davis XIII i.m. (doses too small to be effective); later given more aggressively by Coley, into tumor; severe reactions; about 40 doses in 3 mos.	<i>no effect until given into tumor; then mass became much smaller and more mobile; patient lost ground rapidly after radium therapy; tumor increased</i>	death 16 mos. after onset, 3 mos. after toxins begun
64. Coley (10; 67)	M 7	twice recurrent very extensive malignant juvenile nasopharyngeal polypoid angiomyxosarcoma orbit involving sphenoidal fissure and ethmoid; great pain	excision; radium; intensive prolonged x-ray therapy for both recurrences; transfusion	following x-ray therapy, patient had scarlet fever (tumor increased during it); Parke Davis XIII and special Type VI i.m. for 3½ mos.; good reactions	<i>pain ceased entirely 2 wks. after toxins begun; marked rapid improvement in 4 wks.; tumor entirely necrotic; then continuous fever of 103°-104°F. due to absorption of necrotic tumor tissue</i>	improvement ceased; pain returned; death 1 mo. after toxins stopped, about 2 yrs. after onset

TABLE 1, SERIES C, INOPERABLE FAILURES, (cont'd)

Physician References	Sex Age	Histologic Diagnosis Extent of Disease	Other Treatment Before or After Toxins	Type of Toxin Used; Site & Duration	Immediate Result	Final Result
65. Memorial Hospital (128)	M 31	recurrent leiomyosarcoma (of reticulum cell sarcoma) lt. thigh, bilateral pulmonary metastases (patient had great natural resistance to his neoplasm)	attempted excision; x-ray therapy to thigh (6,500 r), to back (6,100 r); patient well almost 6 yrs., then metastases to lungs; further local recurrence; intensive radiation of thigh and lungs (total, 34, 800 r)	Parke Davis XIII concurrently with next to final course of x-ray therapy; 14 in 14 days i.v.; marked reactions	<i>temporary good response to combined therapy</i>	death 2½ yrs. after lung involvement, 8½ yrs. after onset
66. Wehrly (10)	F 60	terminal leiomyosarcoma uterus, pulmonary metastases; diaphragm and pancreas also involved; in shock	untreated; patient was a Christian Scientist	S.K.I. XIV, 4 doses in 4 days; first dose i.m.; others i.v.; slight reactions	no effect	death 3 days after last dose, 13 mos. after onset
67. Wehrly (10)	F 46	recurrent leiomyosarcoma cervix and broad ligaments; metastases bilateral internal iliac, lymph nodes along aorta, lower lt. lung, severe pain, emesis	biopsy; panhysterectomy; iliac lymph nodes removed; x-ray therapy (3095 r to recurrence and 427 r to lung); radium to apex vagina (1,100 r); no benefit	S.K.I. XIV, 15 doses in 17 days; all but first dose, i.v.	<i>complete relief of pain; patient ate well; all lymph node metastases regressed completely; hydronephrosis developed; uremia due to blockage of ureters from tumor tissue</i>	death 3 days after last dose; autopsy showed much less tumor present than at operation 7 mos. before

SERIES D OPERABLE FAILURES

The following 14 cases are the only known patients with operable sarcoma of the soft tissues that were unsuccessfully treated by Coley toxins given before or after surgery. The first seven were primary lesions, the last seven recurrent when toxins were begun. Nine of these patients also had considerable radiation. (Bibliography references follow each case abstract.)

- | | Period of
Survival (Years) |
|---|-------------------------------|
| 1. (R.M. GREEN*): T.J.G., male, aged 24. Round cell sarcoma left arm above elbow; onset June 1907; excision February 8, 1908; amputation refused. February 10, 1908, toxins (Tracy XI) begun; 3 small doses i.m. weekly for seven weeks; slight febrile reactions; recurrence in elbow joint; amputation of shoulder joint advised and finally performed. Death February 1, 1909 listed as due to "phthisis, postoperative condition for sarcoma". (7; 95) | 1 2/3 |
| 2. (CALKINS): N.O., male, aged 20. Large polyhedral cell sarcoma thigh; football injury in September 1910; onset thereafter; more rapid growth, June 1, 1911; osteopath "massaged and kneaded it thoroughly"; exploratory incision mid-August 1911; hip-joint amputation August 28, 1911. September 10, 1911, toxins (Tracy XI) 3 weekly almost steadily for 12 months, then at monthly intervals for another 6 months; only mild reactions. Patient resumed work; lived on restricted vegetarian diet; subacute pleurisy of right lung, February 1913; death October 7, 1913, apparently from pulmonary metastases. (67) | 3 |
| 3. (COLEY): D.S., male, aged 27. Round cell sarcoma of soft tissues over tibia; onset March 1920; biopsy November 1920. November 11, 1920, toxins (Tracy XI) combined with radium pack (10,000 mch.); 17 injections in 45 days; some febrile reactions to 103°-104°F.; several sinuses drained; <i>complete regression</i> ; toxins continued twice weekly for 2 months; <i>gained weight, symptom-free</i> January 19, 1921; then pulmonary metastases, death June 2, 1921. (10; 67; 128) | 1 1/2 |
| 4. (COLEY): M.B., male, aged 19. Fibrosarcoma or neurogenic sarcoma soft tissues over radius, eroding bone; onset September 1920. December 21, 1920 toxins Tracy XI and Parke Davis XIII given i.m. for 3 1/2 months; <i>circumference of tumor decreased 4 cm. in 2 weeks</i> ; exploratory incision January 5, 1921; 3 radium packs (31,400 mch.); disease controlled temporarily; later more radium given by Bloodgood without effect; axillary metastases | |

* Name of attending physician or hospital

SERIES D, OPERABLE FAILURES

	Period of Survival
April 1922; pulmonary metastases; death May 1, 1923. (51; 59; 128)	2½
5. (ARMSTRONG): J.M.T., male, aged 80. Fibrosarcoma muscles of forearm; date of onset not stated; preliminary x-ray therapy. April 24, 1920 toxins (Parke Davis XIII) given with more x-ray and radium; 38 in 65 days; little or no reaction except when injected into central vascular part of tumor; steady increase in size, considerable pain; amputation June 29, 1920 (<i>growth breaking down</i>); 14 more injections, only 1 marked reaction; pulmonary metastases December 1920; death in February 1921. (10; 67)	1+
6. (COLEY): M.S., male, aged 77. Diffuse round cell sarcoma chest wall, involving 9th and 10th ribs and pleura; onset March 1921; exploratory operation November 11, 1921; tumor size of half an orange found; capsule torn, free hemorrhage, pneumothorax; 1 radium pack (8,159 mch). November 19, 1921, toxins (P.D. XIII) started; 7 in 3 weeks; <i>complete clinical regression, patient in excellent health</i> . July 7, 1922, another radium pack (3,073 mch.); metastases in chest, abdomen and brain; death September 18, 1923. (10; 128)	2½
7. (MAYO CLINIC): J.F.M., male, aged 17. Reticulum cell sarcoma (Grade IV) involving plantar fascia and muscles of right foot in longitudinal arch region without bone involvement. Incisional biopsy; amputation; toxins (Sloan Kettering XIV); 10 i.v. in about 12 days; reactions to 104°F.; metastases in right groin and left scapula apparent 1 month after last dose; 6 more i.v., severe reactions; x-ray therapy to groin, scapular region, mediastinum, pelvis, left shoulder and metastatic lesions (29 treatments in all); generalized metastases thereafter; further extensive x-ray therapy; blood transfusions; death a year after onset (67; 127)	1
8. (COLEY): A.G., male, aged 43. Twice recurrent spindle cell sarcoma right gluteal region; metastases to inguinal lymph nodes; onset May 1894; growth size of fist removed at operation July 8, 1895; recurrence; 2nd operation January 1896; another recurrence; mass 10 × 15 cm.; considerable edema of entire limb; at 3rd operation May 27, 1896 entire mass removed; inguinal metastases also removed. May 30, 1896, toxins (Buxton VI), 17 in 38 days; no marked reactions; <i>considerable diminution in edema of limb, pain decreased, patient able to walk</i> ; recurrence April 1897; toxins resumed for 3 weeks, old cicatrix then excised; no evidence of disease; another recurrence; death. (128)	4
9. (ANSBACH): Mrs. L., aged 35. Fourth recurrence of spindle cell sarcoma muscles and fascia over sacroiliac joint; onset prior to June 1918; excision	

SERIES D, OPERABLE FAILURES

Period of
Survival

June 6, 1918; recurrent tumor removed September 11, 1918; thorough course x-ray therapy; another local recurrence; 3rd operation August 12, 1919; radium and more x-ray therapy; 4th operation January 29, 1920, left gaping wound. February 20, 1920, toxins (Tracy XI) given i.m. intermittently for 8 to 10 weeks; no marked reactions, no effect; death in July 1920. (10, 67)

2

10. (STEWART): R.G., male, aged 27. Recurrent round cell sarcoma psoas muscle involving 7.5 cm. area inner table of ilium; onset April 1908; surgical removal August 15, 1908; recurrence; x-ray therapy every 2nd day; *erysipelas November 1908 caused arrest of growth*. Beginning February 25, 1909 toxins (Parke Davis XII) given subcutaneously; no reactions; with Tracy XI toxins only 1 decided reaction; total duration of therapy 4 weeks; *complete regression in 3 months; gained 40 pounds*; well for 7 months; then rapid recurrence and death in 1910. (67, 186)

2

11. (HARMER): G.P.C., male, aged 34. Thrice recurrent fibrosarcoma of parotid; onset summer of 1910; excision October 1910; recurrence within 2 months; 2nd operation February 21, 1911; 3 doses toxins (Parke Davis XII) thereafter; no reactions; 2nd recurrence 6 months later; paralysis right side of face and right eyelids; 3rd operation; more toxin therapy advised but not given, as patient felt he must return to work at once; 3rd recurrence, toxins for 2 months in out-patient department; good reactions; *tumor mass almost disappeared in 6 weeks*; recurrence; no further treatment; death on May 15, 1912. (100, 120)

almost 2

12. (COLEY): I.A., male, aged 37. Fourth recurrence of neurogenic sarcoma leg; onset, late 1914; primary tumor removed in 2 operations; recurrence; 3rd operation; 23 x-ray treatments in 1919; no regression; deep radiation ulcer 6 × 8 cm.; marked skin damage; 4th operation (biopsy only). Toxins (Tracy XI) February 10, 1920; 31 injections i.m. in 49 days; no marked reactions; radium pack treatments (23,687 mch.) February to April 1920; biopsy April 5, 1920 showed extensive fibrosis and some necrosis, but disease involved tibia; amputation April 28, 1920; toxins then given for about 8 months. *Patient free from recurrence, in excellent health for 12 years; gained a lot of weight*; then dieted (1932) and lost 10 pounds. At this time pulmonary symptoms developed with hemoptysis; in February 1933 coughed up piece of tumor tissue, found to be metastatic spindle cell sarcoma; chest films showed a tumor involving the right upper lobe; died suddenly October 5, 1933, with hemoptysis. (10; 128)

19

13. (COLEY): F.R., male, aged 24. Twice recurrent neurogenic sarcoma

SERIES D, OPERABLE FAILURES

	Period of Survival
right forearm (brachio-plexus muscle); onset August 1923; 2 operations followed by prompt recurrences; 2nd recurrence untreated; wound gaping. August 22, 1924 toxins (Parke Davis XIII); only 7 i.t. in 16 days; <i>tumor softened and decreased 2.5 cm. in diameter after first dose; became more circumscribed</i> ; amputation September 10, 1924; no further toxins; diffuse pulmonary metastases; death January 31, 1927. (128)	4½
14. (COLEY AND CRANDALL): Mrs. F.K., aged 40; recurrent extensive neurogenic sarcoma left thigh; onset December 1926; during second pregnancy in 1928 tumor increased much more rapidly; primary growth removed surgically when size of grapefruit; recurred (22 cm. in length); x-ray therapy. May 1, 1929, toxins (Parke Davis XIII) 5 i.v.; <i>definite regression</i> ; radium packs (28,000 mch.); 8 more toxins i.v.; <i>50 per cent regression in 4 weeks</i> ; radium packs (45,000 mch.); toxins i.m. and sometimes i.v.; radiation ulcer 6 × 3 cm. on posterior left thigh; another radium pack; further x-ray therapy; slight improvement; inguinal, abdominal and lung metastases; death March 30, 1930. (67, 128)	3¼

SUMMARY AND CONCLUSIONS

An analysis of all microscopically proven cases of inoperable (137) and operable (49) sarcoma of soft tissues treated by bacterial toxin therapy has been made. The four most important factors affecting prognosis with such treatment are:

- (a) The preparation used. (see above pp. 106-108 and 141-146).
- (b) The technique of administration as regards site, dosage, frequency and, especially, duration of injections. There were a few successes with the weaker preparations (VIII, IX, XII, XIII) when they were administered in much larger doses for prolonged periods.
- (c) The stage or extent of the disease when toxins were begun.
- (d) The prior therapy given, i.e., extensive or repeated surgery or large amounts of x-ray or radium. These are all immunosuppressive and decrease the responsiveness to subsequent toxin therapy and other forms of immunotherapy.

In the majority of successful cases the injections were given every 24 to 48 hours during the early part of treatment, and were given so as to produce a brisk reaction with chills and febrile reactions of 102°-105°F. Results were much more satisfactory and occurred more promptly when at least some of the injections were given in or near the tumor or its metastases.

Probably several of the failures (both operable and inoperable) should have been excluded since the patients received less than 10 injections or were terminal when toxin therapy was begun. It is now clearly apparent that such a brief course can be of little or no benefit.

With more precise knowledge of the bacteriological problems involved in preparing effective immunopotentiating microbial products, and in administering them most effectively, there is urgent need for more widespread cooperative clinical studies of these promising agents.

There is no need to concentrate such studies on any one agent such as Coley toxins, or B.C.G., since others, such as *Corynebacterium parvum* (105), *staphylococcus*, *Escherichia coli* or *Pseudomonas aeruginosa* vaccines may be used alone, combined, or in sequence for comparative studies. Yeast extracts have shown markedly beneficial effects experimentally (102), as cited by Nauts (152), and are now being used clinically in Europe (136) and in this country. (75; 76; 119) These purified preparations deserve much more widespread use.

Radiation and chemotherapy may also be used in certain cases of sarcoma of soft tissues, especially if given after immunotherapy.

SUMMARY AND CONCLUSIONS

BCG is now being used clinically in many parts of the world and has not been discussed in this review since the literature is readily available.

Further clinical studies should now be planned on the best use of streptococcal enzymes. It is of interest that tumors which secrete mucin seemed to respond far less dramatically to Coley toxins. It is quite possible that the streptococcal enzymes played a significant role in the dramatic regressions observed in so many cancer patients following erysipelas or other streptococcal infections. Since these thermolabile enzymes are destroyed by heat sterilization, they were not present in the Coley toxins in which heat sterilization was used.

The role of fibrinolysis in cancer prognosis and treatment has received increasing attention in recent years due primarily to the work of Thorne and his colleagues in Ireland, who have studied the role of various proteolytic enzymes in immune mechanisms. These studies have clearly indicated that cellular immune mechanisms may be activated by certain proteolytic enzymes. (189, 190)

Since modern cancer immunology has shown us the great importance of these cellular immune factors in the incidence, prognosis and response to conventional treatments in cancer patients, it is encouraging that Thorne and others have observed clinically that the induction of fibrinolysis enhances the activity of cellular immune mechanisms. Its proper application to the treatment of cancer patients holds many exciting possibilities. The effective removal by streptokinase of blocking factors, be they mucin or antibodies, may greatly improve the effectiveness of various forms of immunotherapy if given before and during such treatment. It would seem that injections of these enzymes must be given in or near the tumor area to utilize their fibrinolytic effects to greatest advantage.

One must not destroy an extensive inoperable vascular sarcoma by bacterial vaccine therapy so rapidly that the excretory, reticuloendothelial and lymphoid tissues are overwhelmed. To avoid this problem, it may be possible to remove some of the tumor mass, or during treatment to evacuate some of the necrotic tumor tissue or to use streptokinase-streptodornase to facilitate debridement. (191) Through their catalytic and enzymatic properties such enzymes facilitate the elimination of necrotic debris, permit more effective use of drugs and aid in healing or regeneration of tissues destroyed by the tumor. (109)

One important point not yet considered by most oncologists who are now using BCG or bacterial vaccines in the treatment of cancer is that patients in Europe, Japan and the United States and certain other areas have had very few exposures to tuberculosis or pyogenic infections, or infectious diseases which a century ago were endemic or epidemic all over the world. Therefore our immune reactions have not been stimulated and are not nearly as active as those of patients in

SUMMARY AND CONCLUSIONS

countries where vaccines and antibiotics have not been used to prevent or abort infections.

In this connection it is of interest that patients with inoperable cancer treated by BCG, who demonstrate a strong tuberculin response, react more markedly to BCG therapy with good tumor regression (10), whereas those who do not react, do not respond so well. Concurrent or prior infections in cancer patients receiving Coley toxins have also appeared to exert a favorable effect on the response to such therapy. (10; 134; 140-153) A number of thoracic surgeons have noted the increased five-year survival in patients who developed empyema following surgery for lung cancer. (142)

Cooperative clinical trials should now be undertaken in many countries using carefully planned protocols for microbial products (including bacterial vaccines and enzymes) not only in inoperable cases but also in the operable cases as an adjuvant to surgery, radiation or chemotherapy. The experiences outlined in this end result study can offer useful guidelines in planning such studies, not only in sarcoma of soft tissues but in other malignant tumors, so as to avoid the mistakes in technique or use of inadequate preparations which occurred in the early years before modern tumor immunology had pointed the way to the mechanisms of immunopotentialiation.

BIBLIOGRAPHY

1. Ainsworth, E.J. and Forbes, P.D.: The effect of *Pseudomonas pyrogen* on survival of irradiated mice. *Radiation Research* **14**: 767-774. 1961. (Also personal communications)
2. Andrews, E.: A study of a few suggestive cases. *Chicago Med. Rec.* **8**: 1-8. 1895. (Case 4)
3. Battle, W.H.: A case illustrating the advantage of Coley's fluid in the treatment of inoperable tumours. *Trans. Med. Soc. London.* **21**: 362-364. 1897-1898.
4. Beebe, S.B. and Tracy, M.: The treatment of experimental tumors with bacterial toxins. *J.A.M.A.* **49**: 1493-1498. 1907.
5. Bloodgood, J.C.: The treatment of tumors of the upper jaw by cautery; a preliminary report. *Trans. Amer. Surg. Assn.* **31**: 225-226. 1918. (Discussion by W. B. Coley)
6. Burchenal, J.H.: Geographic chemotherapy—Burkitt's tumor as a stalking horse for leukemia: Presidential address. *Cancer Research* **26**: 2393-2405. 1966.
7. Bureaus of Vital Statistics, State and Municipal: death records.
8. Busch, W.: Verhandlugen ärztlicher Gesellschaften (Proc. April 14, 1866). Einfluss von Érysipèle . . . (no title given). *Berl. klin. Wchnschr.* **3**: 245-246. 1866. (also Niederrheinische Gesellschaft für Natur-und Heilkunde zu Bonn, (Proc.) *Berl. klin. Wchnschr.* **5**: 137-138. 1868.)
9. Butlin, H.T.: On the Operative Surgery of Malignant Disease. 2nd Edition. London, J. & L. Churchill. 1900
10. Cancer Research Institute Records; personal communications from patients or their physicians, hospitals or relatives.
11. Christian, S.L., and Palmer, L.A.: An apparent recovery from multiple sarcoma with involvement of both bone and soft parts, treated by toxins of erysipelas and *Bacillus prodigiosus* (Coley). *Am. J. Surg.* **4**: 188-197. 1928. See also; Apparent recovery from multiple sarcomata, *Military Surgeon* **61**: 42-47, 1927. (Died 37 years after onset of a heart attack)
12. Cole, D.R., Dreyer, B., Rousselot, L.M. and Tendler, M.D.: The radioprotective and anti-tumor effects of mixed bacterial toxins and anthramycin. *Amer. J. Roentg. Radium Ther. & Nuclear Med.* **47**: 997-1002. 1966.

BIBLIOGRAPHY

13. Coley, W.B.: Contribution to the knowledge of sarcoma. *Ann. Surg.* **14**: 199-220. 1891.
14. Coley, W.B.: A preliminary note on the treatment of inoperable sarcoma by the toxin products of erysipelas. *Post-Graduate* **8**: 278-286. 1893.
15. Coley, W.B.: The treatment of malignant tumors by repeated inoculations of erysipelas, with a report of original cases. *Am. J. M. Sc.* **105**: 487-511. 1893.
16. Coley, W.B.: Treatment of inoperable malignant tumors with the toxins of erysipelas and *Bacillus prodigiosus*. *Tr. Am. Surg. A.* **12**: 183-212. 1894.
17. Coley, W.B.: The treatment of inoperable malignant tumors with the toxins of erysipelas and *Bacillus prodigiosus*. *Med. Rec.* **47**: 65-70. 1895.
18. Coley, W.B.: Spindle-celled sarcoma of the abdominal wall successfully treated by the mixed toxins of erysipelas and *Bacillus prodigiosus*. *Ann. Surg.* **26**: 232-234. 1897.
19. Coley, W.B.: The therapeutic value of the mixed toxins of erysipelas and *Bacillus prodigiosus* in the treatment of inoperable malignant tumors. *Am. J. M. Sc.* **112**: 251-281. 1896.
20. Coley, W.B.: Further observations upon the treatment of malignant tumors with the mixed toxins of erysipelas and *Bacillus prodigiosus*, with a report of 160 cases. *Bull. Johns Hopkins Hosp.* **65**: 157-162. 1896.
21. Coley, W.B.: The Indications for the Non-operative Local Treatment of Tumors. The Value of Toxins. Concord, New Hampshire, Republican Press Assn. 1896. (Case 3, pp. 9-10)
22. Coley, W.B.: Recurrent round celled sarcoma of the lip treated with mixed toxins. *Post-Graduate* **12**: 346-348. 1897.
23. Coley, W.B.: Inoperable sarcoma cured by mixed toxins of erysipelas. *Ann. Surg.* **25**: 174-177. 1897.
24. Coley, W.B.: A case of recurrent inoperable spindle-celled sarcoma of the parotid successfully treated with the mixed toxins of erysipelas and *Bacillus prodigiosus*. *Ann. Surg.* **28**: 244-246. 1898.
25. Coley, W.B.: The treatment of inoperable sarcoma with the mixed toxins of erysipelas and *Bacillus prodigiosus*: immediate and final results in one hundred and forty cases. *J.A.M.A.* **31**: 389-395 and 456-465. 1898. (See also *Med. Rec.* **54**: 294-295. 1898)
26. Coley, W.B.: The influence of injury upon the development of sarcoma. *Ann. Surg.* **27**: 259-284. 1898.
27. Coley, W.B.: Mixed toxins of erysipelas and *Bacillus prodigiosus* in treatment of sarcoma. *J.A.M.A.* **34**: 906-908. 1900.

BIBLIOGRAPHY

28. Coley, W.B.: The treatment of inoperable cancer. *St. Paul Med. J.* **2**: 365-374. 1900.
29. Coley, W.B.: Late results of the treatment of inoperable sarcoma with the mixed toxins of erysipelas and *Bacillus prodigiosus*. *Philadelphia Med. J.* : 1013-1017. 1901.
30. Coley, W.B.: Acute traumatic malignancy. *Med. News* **78**: 575-578 and 614-618. 1901.
31. Coley, W.B.: Late results of the treatment of inoperable sarcoma with the mixed toxins of erysipelas and *Bacillus prodigiosus*. *Tr. Am. Surg. A.* **19**: 27-42. 1901.
32. Coley, W.B.: The influence of the roentgen ray upon the different varieties of sarcoma. *Tr. Am. Surg. A.* **20**: 308-334. 1902.
33. Coley, W.B.: Small round cell sarcoma of the parotid successfully treated by the mixed toxins of erysipelas and *Bacillus prodigiosus*. *Ann. Surg.* **35**: 421-425. 1902.
34. Coley, W.B.: Treatment of cancer (including sarcoma) in *Twentieth Century Practice of Medicine*, ed. by T. J. Stedman. New York, William Wood & Co., 1903, Suppl. to Vol. 21, p. 767 (Case VII).
35. Coley, W.B.: Observations upon the symptomatology and treatment of sarcoma. *Trans. Lehigh Valley Med. A.* **1**: 55-78. 1903.
36. Coley, W.B.: Final results in the x-ray treatment of cancer. *Ann. Surg.* **42**: 161-184. 1905.
37. Coley, W.B.: Amputation of the hip-joint for sarcoma, with a report of seven cases without mortality. *Tr. South. Surg. A.* **16**: 77-96. 1903.
38. Coley, W.B.: Treatment, operative and by the mixed toxins. *Brooklyn M.J.* **20**: 313-317. 1906.
39. Coley, W.B.: Late results of the x-ray treatment of sarcoma. *Arch. Phys. Therap.* **3-4**: 161-169. 1906. (p. 166)
40. Coley, W.B.: Late results of the treatment of inoperable sarcoma by the mixed toxins of erysipelas and *Bacillus prodigiosus*. *Am. J. M. Sc.* **131**: 373-430. 1906.
41. Coley, W.B.: Inoperable sarcoma: a further report of cases successfully treated with the mixed toxins of erysipelas and *Bacillus prodigiosus*. *Med. Rec.* **72**: 129-137. 1907.
42. Coley, W.B.: Sarcoma of the long bones: the diagnosis, treatment and prognosis with a report of sixty-nine cases. *Ann. Surg.* **45**: 321-368. 1907.

BIBLIOGRAPHY

43. Coley, W.B.: Inoperable round cell sarcoma of the back; with metastatic tumor involving a large portion of the lower jaw; entire disappearance under 21 months' treatment with the mixed toxins. *Ann. Surg.* **48**: 1908.
44. Coley, W.B.: The treatment of sarcoma with mixed toxins of erysipelas and *Bacillus prodigiosus*. *Boston M. & S. J.* **158**: 175-182. 1908.
45. Coley, W.B.: Ms. for an unfinished monograph on toxin therapy. 1908-1936.
46. Coley, W.B.: The treatment of inoperable sarcoma by bacterial toxins. *Proc. Roy. Soc. Med. (Surg. Sect.)* **3**: 1-48. 1909-1910.
47. Coley, W.B.: The treatment of inoperable sarcoma with the mixed toxins of erysipelas and *Bacillus prodigiosus*. *Trans. New Hampshire M. Soc.* pp. 225-268. 1910.
48. Coley, W.B.: A report of recent cases of inoperable sarcoma successfully treated with mixed toxins of erysipelas and *Bacillus prodigiosus*. *Surg., Gynec. & Obst.* **13**: 174-190. 1911.
49. Coley, W.B.: Disappearance of a recurrent carcinoma after injections of mixed toxins. *Ann. Surg.* **55**: 897-898. 1912.
50. Coley, W.B.: Inoperable adenocarcinoma of the soft palate, rendered operable by the use of the mixed toxins. *Ann. Surg.* **58**: 559-561. 1913.
51. Coley, W.B.: The Treatment of Malignant Inoperable Tumors with the Mixed Toxins of Erysipelas and *Bacillus Prodigiosus*, with a Brief Report of 80 Cases Successfully Treated with the Toxins from 1893-1914. Brussels, M. Weisenbruch. 1914.
52. Coley, W.B.: Inoperable recurrent sarcoma of the upper jaw successfully treated with the mixed toxins of erysipelas and *Bacillus prodigiosus*. *Ann. Surg.* **62**: 353. 1915.
53. Coley, W.B.: Inoperable recurrent tumor of nasopharynx, involving ethmoid, sphenoid, frontal and superior maxillae bones (carcinoma); disappearance under six weeks' treatment with the mixed toxins. *Ann. Surg.* **62**: 353-358. 1915.
54. Coley, W.B.: Inoperable spindle-celled sarcoma of the superior maxilla; disappearance under 2½ months' treatment with the mixed toxins of erysipelas and *Bacillus prodigiosus*. *Ann. Surg.* **62**: 504-506. 1915.
55. Coley, W.B.: Primary neoplasms of the lymphatic glands, including Hodgkin's disease. *Tr. Am. Surg. A.* **33**: 499-644. 1915. (See also *Ann. Surg.* **33**: 35-70. 1916)

BIBLIOGRAPHY

56. Coley, W.B. and Huguot, J.P.: Melanotic cancer; with a report of 90 cases. *Tr. Am. Surg. A* **34**: 319-383. 1916.
57. Coley, W.B.: Further observations on the conservative treatment of sarcoma of the long bones. *Ann. Surg.* **70**: 633-660. 1919. (See also *Trans. Am. Surg. A.* **37**: 273-336. 1919.)
58. Coley, W.B., and Coley, B.L.: End results in 169 operable cases of periosteal osteogenic sarcoma and endothelioma, including a small group of malignant central sarcoma. *Tr. Am. Surg. A.* **43**: 857-949. 1925.
59. Coley, W.B., and Coley, B.L.: Primary malignant tumors of the long bones; end results in one hundred and seventy operable cases. *Arch. Surg.* **13**: 779-836. 1926; **14**: 63-141. 1927.
60. Coley, W.B., and Blum, D.M.: Large malignant tumor (sarcoma) of the uterus with multiple bone metastases (femur, pelvic bones and skull); case successfully treated by hysterectomy and Coley's toxins (erysipelas and *Bacillus prodigiosus*). *Am. J. Surg.* **23**: 47-53. 1934.
61. Coley, W.B.: Sarcoma of the long bones. Clinical lecture on end results. Exhibition of patients illustrating end results of treatment. *S. Clin. North America* **9**: 583-618. 1929.
62. Coley, W.B.: Treatment of bone sarcoma. *Cancer Review* **4**: 426-436. 1929.
63. Coley, W.B.: Endothelial myeloma of tibia; long-standing cure by toxin treatment. *Ann. Surg.* **93**²: 447-452. 1931.
64. Coley, W.B.: The treatment of sarcoma of the long bones. *Tr. Am. Surg. A.* **50**: 383-417. 1932.
65. Coley, W.B.: Unpublished paper read before the American Association for Cancer Research, New York, November 19, 1934.
66. Coley, W.B.: Wilm's tumor. *Am. J. Surg.* **29**: 463-464. 1935.
67. Coley, W.B.: Office records, 1892-1936: now the property of Cancer Research Institute.
68. Coley, W.B.: Diagnosis and treatment of bone sarcoma. *Glasgow M. J.* **126**: 49-86; 128-164. 1936.
69. Collis, M.H.: On the Diagnosis and Treatment of Cancer and the Tumors Analogous to It. London, J. Churchill Sons, 1864.
70. Council on Pharmacy and Chemistry, American Medical Association. *J.A.M.A.* **103**: 1067. 1934.
71. Cushing, H., and Wolbach, S.B.: The transformation of a malignant para-

BIBLIOGRAPHY

- vertebral sympathicoblastoma into a benign ganglioneuroma. *Am. J. Path.* **3**: 203-216. 1927.
72. Da Costa, J.C.: *Modern Surgery*, ed. 10, Philadelphia, W.B. Saunders Co., 1931.
73. De Courcy, J.L.: The spontaneous regression of cancer. *J. Medicine* **14**: 141-146. 1933.
74. Delario, A.J.: Methods of enhancing roentgen-ray action. *Radiology* **25**: 617-627. 1935.
75. DiLuzio, N.R., Pisano, J. C. and Saba, T.M.: Evaluation of the mechanism of glucan-induced stimulation of the reticuloendothelial system. *J. Reticuloendothelial Soc.* **7**: 731-742. 1970.
76. DiLuzio, N.R.: Macrophages, recognition factors and neoplasia. *In: The Reticuloendothelial System: IAP Monograph #16*. The Williams & Wilkins Co., Baltimore. 1975.
- 76a. DiLuzio, N.R., McNamee, R., Jones, E., Lassoff, S., Sear, W. and Hoffman, E.O.: Inhibition of growth of Shay myelogenous leukemic tumor in rats by glucan and glucan activated macrophages. *In: Proceedings VII International Congress of the Reticuloendothelial Society*. Plenum Press. 1975.
- 76b. DiLuzio, N.R.: Pharmacology of the reticuloendothelial system. *In: Proceedings VII International Congress of the Reticuloendothelial Society*. Plenum Press. 1975.
77. Donnelly, A.J., Havas, H.F., and Groesbeck, M.F.: Mixed bacterial toxins in the treatment of tumors. II. Gross and microscopic changes produced in sarcoma 37 and in mouse tissues. *Cancer Res.* **18**: 149-154. 1958.
78. Doub, H.P.: Artificial fever as a therapeutic agent. *Radiology* **25**: 360-361. 1935.
79. Doub, H.P.: Osteogenic sarcoma of the clavicle treated with radiation and fever therapy. *Radiology* **25**: 355-356. 1935. (Patient alive 1974)
80. Duran Reynals, F.: Reactions of spontaneous mouse carcinomas to blood carried bacterial toxins. *Proc. Soc. Exper. Biol. & Med.* **32**: 1517-1521. 1935.
81. Editorial on Coley's Toxins. *J.A.M.A.* **103**: 1071. 1934.
82. Emerson, F.P.: Sarcoma of the tonsil treated with Coley's toxins. *Laryngoscope* **17**: 212-214. 1907.
83. Eve, F.: Myeloid sarcoma of the tibia. *Lancet* **2**: 1355-1357. 1912.
84. Everson, T.C. and Cole, W.H.: Spontaneous regression of cancer: preliminary report. *Ann. Surg.* **144**: 366-383. 1956.

BIBLIOGRAPHY

85. Ewing, J.: Cancer Problems. *In*: Second Report of the Huntington Cancer Research Fund, New York. 1907.
86. Fehleisen, F.: Ueber Erysipel. *Deutsche Ztschr. f. Chir.* **16**: 391-397. 1881-1882.
87. Ferry, N.S. and Fisher, L.W.: Immunizing properties of bacterial antigens prepared after various methods. *Brit. J. Exper. Path.* **5**: 185-198; 205-212. 1924.
88. Fowler, G.A.: Testicular cancer treated by bacterial toxin therapy as a means of enhancing host resistance. End results in 63 determinate cases. Monograph #7, New York Cancer Research Institute*, New York, 1968.
89. Fowler, G.A.: Enhancement of natural resistance to malignant melanoma with special reference to the beneficial effects of concurrent infections and bacterial toxin therapy. New York Cancer Research Institute*, Monograph #9, New York. 1969.
90. Fowler, G.A.: Beneficial effects of acute bacterial infections or bacterial toxin therapy on cancer of the colon or rectum. New York Cancer Research Institute*, Monograph #10. New York. 1969.
91. Fowler, G.A.: The apparently beneficial effects of concurrent infections, inflammation or fever and of bacterial toxin therapy on neuroblastoma. New York Cancer Research Institute* Monograph #11. New York. 1970.
92. Fowler, G.R.: Sarcoma of the tonsil and fauces removed by external pharyngectomy. *Brooklyn M.J.* **10**: 319-322. 1896.
93. Fowler, G.R.: The use of animal toxins in the treatment of inoperable malignant tumors. *Am. J. M. Sc.* **116**: 161-190. 1898.
94. George, C., Jr.: The treatment of inoperable tumors. *Philadelphia Med. J.* **9**: 64-69. 1902.
95. Green, R.M.: The use of Coley toxins in the treatment of sarcoma. *Boston M. & S. J.* **165**: 1-6. 1911.
96. Green, W. E.: The Coley treatment of inoperable sarcoma by the mixed toxins of erysipelas and *Bacillus prodigiosus*. *North Am. J. Homoeop.* (New York) **22**: 685-687. 1907.
97. Greenwood, H.H.: Note on a case of melanotic sarcoma treated by Coley's fluid. *Lancet* **2**: 881-882. 1912. (Also **1**: 25. 1912.)
98. Gregory, J.: *Bacillus subtilis* as an antibiotic in the treatment of cancer. *Southern M. J.* **43**: 397-403. 1950.

* Name changed in 1973 to Cancer Research Institute Inc.

BIBLIOGRAPHY

99. Harmer, T.W.: Remarks upon the effects observed in the use of the mixed toxins (Coley) in certain cases of sarcoma. *Boston M. & S. J.* **171**: 253-261. 1914.
100. Harmer, T.W.: A study of the efficiency of mixed toxins (Coley) in inoperable sarcoma. A critical analysis of 134 microscopically proven cases. *Boston M. & S. J.* **172**: 331-338; 373-377; 411-416; 440-448; 1915.
101. Havas, H.F., Groesbeck, M.E. and Donnelly, A.J.: Mixed bacterial toxins in the treatment of tumors. I. Methods of preparation and effects on normal and sarcoma 37-bearing mice. *Cancer Res.* **18**: 141-148. 1958.
102. Herbut, P.A. and Kraemer, W.H.: The possible role of the properdin system in transplantable cancer. The effect of zymosan on transplantable human carcinoma. *Cancer Res.* **16**: 1048-1052. 1956.
103. Hodenpyl, E.: The treatment of carcinoma with the body fluids of a recovered case. *Med. Rec.* **77**: 359-360. 1910.
104. Hollcraft, J.W. and Smith, W.W.: Endotoxin treatment and x-irradiation in mice bearing transplantable tumors. *J. Nat. Cancer Inst.* **21**: 311-330. 1958.
105. Israel, L.: On 414 cases of human cancer treated with Corynebacteria. Symposium on *C. parvum*. Paris. 1974.
106. Jacobi, M.: The effect of Shwartzman reaction with bacterial filtrate in transplantable tumors in animals. *Am. J. Cancer* **26**: 770-774. 1936.
107. Jacobsen, C.: Der chronische Reis des reticuloendothelialen Systems—eine Krebshemmung. *Arch. f. Dermat. U. Syph.* **169**: 562-576. 1934.
108. Jancso, M.: Histamine as a physiological activator of the reticulo-endothelial system. *Nature* **160**: 227-228. 1947.
109. Johnson, A.J.: Cytological studies in association with local injections of streptokinase-streptodornase in patients. *J. Clin. Invest.* **29**: 1376-1386. 1950.
110. Johnson, W.B.: A case of sarcoma of the palate successfully treated with the toxins of erysipelas. *Med. Rec.* **46**: 616-617. 1894.
111. Lagueux, P.: Le sérum de Coley dans les cas de sarcome ou carcinome ou dans les cas de récidence après opération. *Bull. méd. de Québec* **10**: 469-470. 1908.
112. Lambert, R.A.: Demonstration of the greater susceptibility to heat of sarcoma cells as compared with actively proliferating connective tissue cells. *J.A.M.A.* **59**: 2147-2148. 1912.
113. Landy, M. and Pillemer, L.: Elevation of the properdin levels in mice following administration of bacterial lipopolysaccharides. *J. Exper. Med.* **103**: 823-833. 1956.

BIBLIOGRAPHY

114. Large, S.H.: Four cases of sarcoma of the nose and throat treated with Coley's toxins. *Cleveland Med. J.* **10**: 318. 1911.
115. Lilienthal, H.: Mediastinal sarcoma—treated with Coley's fluid. *Ann. Surg.* **85**: 615-625. 1927.
116. Lohmann, R., Krebsstoffwechsel und Entzündung. *Klin. Wchnschr.* **10**: 1799-1802. 1931.
117. Mackay, C.G.: A case that seems to suggest a clue to the possible solution of the cancer problem. *Brit. M. J.* **2**: 138-140. 1907.
118. Magnant, E.: Cancroïde de la lèvre inférieure guéri par deux injections de lymphé humaine. *Rev. méd. de l'est.* (Nancy) **24**: 404-405. 1892.
119. Mansell, P.W.A., Ichinose, H., Reed, R.J., Krementz, E.T., McNamee, R. and DiLuzio, N.R.: Macrophage-mediated destruction of human malignant cells in vivo. *J. Nat. Cancer Inst.* **54**: 571-580. 1975.
120. Massachusetts General Hospital Records, Boston.
121. Matagne, J.H.J.: Premiers essais de traitement des tumeurs malignes inopérables par les toxines de Coley: un cas de cancer guéri. *Gaz. méd. Liège* **8**: 401-402. 1896.
122. Matagne, J.H.J.: Traitement des tumeurs malignes inopérables par l'érysipèle et les toxines de Coley. *Gaz. méd. Liège* **12**: 375-377. 1899-1900.
123. Matagne, J.H.J.: Les toxines de Coley employées dans le bût de prévenir la récidence du cancer. *Presse Méd. Belge* **54**: 1-3. 1902.
124. Matagne, J.H.J.: Présentation de cancéreux guéris par les toxines de Coley, employées conjointement avec intervention chirurgicale. *Presse méd. Belge* **57**: 173-179. 1905.
125. Matagne, J.H.J.: Vers la guérison du cancer. *Scalpel* **104**: 540-544. 1951.
126. Matagne, J.H.J.: La guérison du cancer. *Scalpel* **106**: 1387-1395. 1953.
127. Mayo Clinic Records.
128. Memorial Hospital Records, New York.
129. Menkin, V.: Dynamics of Inflammation. An Inquiry into the Mechanism of Infectious Processes. New York, Macmillan Co. 1940.
130. Menkin, V.: Newer Concepts of Inflammation. Springfield, Illinois, Charles C. Thomas. 1950.
131. Meriwether, F.T.: Some remarks upon Coley's treatment of malignant growth. *Louisville Monthly J.M. & S.* **6**: 173-177. 1900. (Case 1)

BIBLIOGRAPHY

132. Meyer, W.: Cancer. New York, Paul B. Hoeber. 1931.
133. Miller, T. N. and Nicholson, J.T.: End results in reticulum cell sarcoma of bone treated by toxin therapy alone or combined with surgery and/or radiation (47 cases) or with concurrent infection (5 cases). *Cancer* **27**: 524-548. 1971.
134. Moullin, H.M.: The treatment of Sarcoma and Carcinoma by Injections of Mixed Toxins. London, John Bale Sons & Danielsson. 1898.
135. Mynter, H.: Sarcoma of the abdominal cavity cured by the toxins of erysipelas. *Med. Rec.* **47**: 167-168. 1895.
136. Nagy, I., Jenó, A. and Koszoru, M.: Complementary immunotherapy in tumorous diseases. A ten-year's survey of mannozymb therapy. *Arch. Italiano di Pathologia e Clinica dei Tumori* **14**: 29-35. 1971.
137. Nauts, H.C., Swift, W.C. and Coley, B.L.: Treatment of malignant tumors by bacterial toxins as developed by the late William B. Coley, M.D., reviewed in the light of modern research. *Cancer Res.* **6**: 205-216. 1946.
138. Nauts, H.C. and Coley, B.L.: A review of the treatment of malignant tumors by Coley bacterial toxins, in Approaches to Tumor Chemotherapy. Publication of the American Assoc. For the Advancement of Science, Washington, D. C., 1947, pp. 217-235.
139. Nauts, H.C., Fowler, G.A. and Bogatko, F.H.: A review of the influence of bacterial infection and of bacterial products (Coley's toxins) on malignant tumors in man. *Acta med. scandinav.* **145**: Suppl. 276. 1953. (103 pp.)
140. Nauts, H.C. and Fowler, G.A.: Studies of the Effects of Bacterial Products or of Acute Bacterial Infections on Malignant Disease; Bibliography on the Effects of Acute Bacterial Infections, Inflammation, Fever or Heat, Whether Occurring Spontaneously or Induced Artificially (496 references, with brief foreword). Lakeville, Conn., Lakeville Journal. 1952.
141. Nauts, H.C., Pelner, L. and Fowler, G.A.: Sarcoma of the soft tissues, other than lymphosarcoma, treated by toxin therapy. End results in 186 determinate cases with microscopic confirmation of diagnosis: 49 operable, 137 inoperable. Monograph #3, New York Cancer Research Institute, Inc.*, New York, 1959.
142. Nauts, H.C.: The apparently beneficial effects of bacterial infections on host resistance to cancer: end results in 435 cases. Monograph #8, New York Cancer Research Institute, Inc.*, New York, 1969. (829 pp., 969 references)
143. Nauts, H.C. and Fowler, G.A.: End results in lymphosarcoma treated by toxin therapy alone or combined with surgery and/or radiation. Monograph #6, New York Cancer Research Institute, Inc.*, New York, 1969.

* Name changed in 1973 to Cancer Research Institute Inc.

BIBLIOGRAPHY

144. Nauts, H.C.: Host resistance to cancer. Review of the early and recent literature. Monograph #5, 2nd ed., New York Cancer Research Institute, Inc.*, New York, 1970.
145. Nauts, H.C.: Enhancement of natural resistance to renal cancer: beneficial effects of concurrent infections and immunotherapy with bacterial vaccines. New York Cancer Research Institute, Inc.*. Monograph #12. New York. 1973.
146. Nauts, H.C.: Ewing's sarcoma of bone: end results following immunotherapy (bacterial toxins) combined with surgery and/or radiation. Cancer Research Institute Monograph #14. New York, 1974.
147. Nauts, H.C.: Giant cell tumor of bone: end results following immunotherapy (Coley toxins) alone or combined with surgery and/or radiation (66 cases), or with concurrent infection (4 cases). Monograph #4, 2nd edition, Cancer Research Institute, New York. (To be published 1976).
148. Nauts, H.C.: Immunological factors affecting incidence, prognosis and survival in breast cancer. Part I: The immunopotentiating effects of concurrent infections, inflammation or fever. Part II: Immunotherapy, effects of bacterial vaccines. Cancer Research Institute Monograph #17. New York. (To be published.)
149. Nauts, H.C.: Multiple myeloma: beneficial effects of acute infections or immunotherapy (bacterial vaccines). Cancer Research Institute Monograph #12. New York 1975.
150. Nauts, H.C.: Bibliography of reports concerning the experimental or clinical use of Coley toxins (*Streptococcus pyogenes* and *Serratia marcescens*) 1893-1975. (383 references, including 124 by W. B. Coley) 1975.
151. Nauts, H.C.: Pyrogen therapy of cancer: a historical overview and current activities. Read at International Symposium on Cancer Therapy by Hyperthermia and Radiation. Washington, D.C., April 28-30, 1975. (in press)
152. Nauts, H.C.: Immunotherapy of cancer by microbial products. Read at the Fifth International Symposium of the Princess Takematsu Cancer Research Fund on Host Defense Against Cancer and Its Potentiation. January 28-30, 1975. (in press)
153. Nauts, H.C.: Osteogenic sarcoma: end results following immunotherapy (bacterial vaccines) 165 cases, or concurrent infections, inflammation or fever, 41 cases. Cancer Research Institute Monograph #15. New York, 1975.
154. New York Cancer Research Institute Records: see #10 (name changed 1973 to Cancer Research Institute).

* Name changed in 1973 to Cancer Research Institute Inc.

BIBLIOGRAPHY

155. New York Hospital records.
156. Nicholson, C.M.: Report of four cases of sarcoma treated by injection of erysipelas and prodigiosus toxins. *Am. J. Surg. & Gynec.* (St. Louis) **13**: 10-11. 1899.
157. Noon, L.: The influence of site of inoculation on the immunity produced. *Lancet* **2**: 396. 1909.
158. Odier, R.: Traitement des affections sarcomateuses par les toxines de M. Coley. *Rev. méd Suisse rom.* **28**: 649-654. 1908
159. Old, L.J., Clark, D.A. and Benacerraf, B.: Effect of Bacillus Calmette-Guérin infection on transplanted tumours in the mouse. *Nature* **184**: 291-292. 1959.
160. Old, L.J., Benacerraf, B., Clark, D., Carswell, E.Q. and Stockert, E.: The role of the reticuloendothelial system in the host reaction to neoplasia. *Cancer Res.* **21**: 1281-1300. 1961.
161. Oliver, J.C.: Results obtained from the use of Coley's toxins in the treatment of sarcoma. *Ohio M.J.* **7**: 483-489. 1911.
162. Owen, J.E.: The use of toxins in sarcoma. *Chicago Med. Recorder* **8**: 119-122. 1895. (See also *Tr. Illinois Med. Soc.* (Chicago) 282-227, 1897 (Case 2)
163. Pack, G.T. and Ariel, I.M.: Tumors of the Soft Somatic Tissues. New York, Hoeber-Harper. 1958.
164. Palmer, C.W.: Treatment of sarcoma with the mixed toxins of erysipelas and Bacillus prodigiosus. *J. Oph., Otol. & Laryngol.* **12**: 214-220. 1900.
165. Pelner, L.: Host-tumor antagonism. I. Evidence of tumor immunity. *J. Amer. Geriat. Soc.* **4**: 683-689. 1956
166. Pelner, L.: Host-tumor antagonism. V. The effect of ionizing radiations (radium and x-ray) upon tumor and host. *J. Amer. Geriat. Soc.* **5**: 512-519. 1957.
167. Pelner, L.: Host-tumor antagonism. IX. The reticuloendothelial system and neoplasia. *J. Amer. Geriat. Soc.* **5**: 916-931. 1957.
168. Pelner, L., Fowler, G. A. and Nauts, H.C.: Effects of concurrent infections or their toxins on the course of leukemia. *Acta med. Scand.* **162**: suppl. 338. 1958. (47 pp.)
169. Pelner, L.: Host-tumor antagonism. XII. Possible effect of the cortisone drugs on the development of metastases in patients with cancer. *J. Amer. Geriat. Soc.* **7**: 428-439. 1959
170. Pelner, L. & Fowler, G.A.: Host-tumor antagonism. XIII Sarcoma of the soft tissues treated by toxin therapy: successful series. *J. Amer. Geriat Soc.* **7**: 624-647. 1959; XIV. unsuccessful series. 698-721. 1959

BIBLIOGRAPHY

171. Pelner, L.: Host-tumor antagonism. XV. The apparently beneficial effects of acute concurrent infections or of toxin therapy on the course of malignant melanoma. *J. Amer. Geriat. Soc.* **8**: 378-397. 1960.
172. Porter, C.A.: The surgical treatment of x-ray carcinoma and other severe x-ray lesions, based on an analysis of 47 cases. *J. Med. Res.* **21** : 357-413. 1909. (Case VIII)
173. Richardson, M.H.: A case of apparently hopeless infiltration of left axilla and scapula by round cell sarcoma; extirpation attempted and abandoned; extensive and severe wound infection, followed by disappearance of the tumor. *Tr.Am.Surg.A.* **16**: 309-313. 1898. (See also *Ann. Surg.* **28**: 741-746. 1898.)
174. Shear, M.J.: Chemical treatment of tumors; reactions of mice with primary subcutaneous tumors to injection of hemorrhage-producing bacterial polysaccharide. *J. Nat. Cancer Inst.* **4**: 461-476. 1944.
175. Shear, M.J.: Discussion of paper by Reinhard, E.J., Good, J.T. and Martin, E.: Chemotherapy of malignant neoplastic diseases. *J.A.M.A.* **142**: 383-390. 1950. (p. 390)
176. Sheild, A.M.: Remarks on a case of recurrent sarcoma of the mammary gland treated with Coley's fluid with a fatal result. *Brit. M.J.* **1**: 193-194. 1897.
177. Shields, E.H.: Coley's toxins in sarcoma. *Lancet-Clinic* (Cincinnati) **111**: 701. 1914.
178. Shwartzman, G.: Reactivity of malignant neoplasms to bacterial filtrates. I. The effect of spontaneous or induced infections on the growth of mouse sarcoma 180. *Arch. Path.* **21**: 284-297. 1936.
179. Shwartzman, G.: The Phenomenon of Local Tissue Reactivity. New York. Paul B. Hoeber. 1937.
180. Shwartzman, G. and Michailovsky, N.: Phenomenon of local tissue reactivity to bacterial filtrates in treatment of mouse sarcoma 180. *Proc. Soc. Exper. Biol. & Med.* **29**: 737-741. 1932.
181. Smith, W.W., Alderman, I.M. and Gillespie, R.E.: Hematopoietic recovery induced by bacterial endotoxins in irradiated mice. *Amer. J. Physiol.* **192**: 549-556. 1958. (see also **191**: 124-130. 1957.)
182. Southam, C.M. and Pillemer, L.: Serum properdin levels and cancer cell homografts in man. *Proc. Soc. Exper. Biol. & Med.* **96**: 596-601. 1957.
183. Spencer, C.G.: A case of sarcoma treated with Coley's fluid. *J. Roy. Army M. Corps.* **12**: 449-451. 1909. (See also *Lancet* **2**: 1127. 1912)
184. Spencer, C.G.: A case of sarcoma treated by Coley's fluid. *Proc. Roy. Soc. Med.* (Clin. Sect.) **2**: 152-154. 1908-1909.

BIBLIOGRAPHY

185. Spronck, C.H.H.: Tumeurs malignes et maladies infectieuses. *Ann. Inst. Pasteur* **6**: 683-707. 1892.
186. Stewart, F.T.: Sarcoma of psoas muscle treated by Coley's fluid. *Ann. Surg.* **51**: 285-288. 1910.
187. Stone, H.B., Curtis, R.M. and Brewer, J.H.: Can resistance to cancer be induced? *Ann. Surg.* **134**: 519-527. 1951.
188. Tanchou, S.: Recherches sur le traitement médical des tumeurs cancéreuses du sein. Ouvrage pratique basé sur trois cents observations (extrait d'un grand nombre d'auteurs). Paris. Germer Baillière. 1844.
189. Thornes, R.D.: Fibrinolytic therapy of leukaemia. *J. Royal Coll. Surg. Ireland* **6**: 123-128. 1971.
190. Thornes, R.D.: Adjuvant therapy of cancer via the cellular immune mechanism or fibrin by induced fibrinolysis and oral anticoagulants. *Cancer* **35**: 91-97. 1975.
191. Tillett, W.S., Sherry, S., Christensen, L.R., Johnson, A.J. and Hazlehurst, G.: Streptococcal enzymatic debridement. *Ann. Surg.* **131**: 12-22. 1950.
192. Toolan, H.W.: Successful subcutaneous growth and transplantation of human tumors in x-irradiated laboratory animals. *Proc. Soc. Exper. Biol. & Med.* **77**: 572-578. 1951.
- 192a. Tosier, F.L.: Non-operative sarcoma: a treatment. *Vermont Med. Monthly* **15**: 217-218. 1909.
193. Tracy, M.: Office records.
194. Tupper, P.Y.: The treatment of inoperable sarcoma with Coley's mixed toxins: report of cases. *Med. Rev. (St. Louis)* **39**: 425. 1899.
195. Tuffier, T.: Le traitement du cancer inopérable. Paris. Masson et Cie. 1910.
196. Vidal, E.: Cancer et traumatisme. (Association française de Chirurgie. Comptes rendu du Congrès français de chirurgie). Paris. Alcan. 1907. (p. 902)
197. Ward, G.S.: Mixed cell sarcoma treated by local excision and Coley's fluid. No recurrence after three years. *Brit. M. J.* **2**: 1484. 1913.
198. Warthin, A.S.: Multiple primary neoplasms in one individual (spindle cell sarcoma of forearm, adenocarcinoma of pylorus, myomata of stomach wall); treatment with Coley's mixture. *Philadelphia M. J.* **8**: 701-703. 1901.
199. Winberg, O.K.: Inoperable round celled sarcoma of the upper jaw with metastases, successfully treated with the mixed toxins of erysipelas and *Bacillus prodigiosus*. *Med. Rec.* **41**: 681-684. 1902.

BIBLIOGRAPHY

200. Wolbach, S.B.: The pathological history of chronic x-ray dermatitis and early x-ray carcinoma. *J. Med. Research* **21**: 415-449. 1909. (Case 1)
201. Wyeth, J.A.: Sarcoma cured by acute inflammation. *Med. Rec.* **57**: 125-126. 1900.
202. Wyeth, J. A.: The value of inoculations of septic or toxic agents in the treatment of malignant neoplasms. *J.A.M.A.* **22**: 985-992. 1894.
203. Zweifach, B.W., Kivy-Rosenberg, E. and Nagler, A.L.: Resistance to whole-body x-irradiation in rats made tolerant to bacterial endotoxins. *Amer. J. Physiol.* **197**: 1364-1370. 1959.

71. (MORRISON) Inoperable twice recurrent rapidly growing sarcoma of the groin. Two operations were performed; Coley toxins were given after the second recurrence (about 1917) with complete recovery, traced well eight years later. (133a)

36. (MORRISON and SAINT) female, aged 22; fibrosarcoma of the back, primary in the latissimus dorsi muscle; recurrence deeply involved the serratus magnus muscle, ribs and pleura; primary lesion excised, March 1912; a year later she returned with a large deep fixed recurrence; this was excised with a wide area of serratus magnus muscle, 10 cm. of the underlying ribs and pleura; the lung was not involved; Coley toxins (Tracy XI) given for 18 months; complete recovery, in good health, no further recurrence, 1933. (133a)

Note: In reporting this and one other inoperable twice recurrent case that recovered and was traced well eight years later, they stated: "Those who refuse to accept such evidence as has been offered in support of this treatment fail in their duty to these, at present, otherwise hopeless cases."

Cancer Research Institute
1225 Park Avenue
New York, New York

Longevity in Soft Tissue Sarcomas Treated by Immunotherapy*
Inoperable Successes Series A

<u>Case Number</u>	<u>Age at Death or at last Follow Up</u>	<u>Period of Survival From Onset</u>
Case 2	Died at 75	59½ yrs. later
Case 6	Alive at 83	47 " "
Case 7	Died at 82	53 " "
Case 10	" " 93	88 " "
Case 15	" " 89	47½ " "
** Case 28	" " 92	58 " "
Case 31	" " 81	26 " "
** Case 33	" " 60	50 " "
Case 35	" " 66	28 " "
Case 39	" " 80	37 " "
** Case 40	" " 73	39 " "
Case 41	" " 81	28 " "
Case 46	" " 74	22 " "
Case 47	" " 74	28 " "
Case 49	" " 72	22 " "
Case 50	" " 81	54½ " "
** Case 52	" " 75	47 " "
Case 54	" " 68	46 " "
Case 56	" " 61	33 " "
(Very remarkable case)		
Case 57	" " 78	55 " "
Case 63	Alive at 60	62 " "
Case 65	Died at 78	51 " "
Case 68	Alive at 66	40 " "
Case 69	Alive at 73	21 " "
** Case 70	Died at 67	14½ " "

* Injections of mixed bacterial vaccines (MBV) Streptococcus pyogenes and Serratia marcescens, then known as Coley's Mixed Toxins.

** Died of second primary.

10/24/85

Cancer Research Institute
1225 Park Avenue
New York, New York

Longevity in Soft Tissue Sarcomas Treated by Immunotherapy*
Operable Successes Series B

<u>Case Number</u>	<u>Age at Death or at last Follow Up</u>	<u>Period of Survival From Onset</u>
Case 1	Died at 92½	57½ yrs. later
Case 6	Alive at 82	75 " "
** Case 10	Died at 84	49 " "
Case 11	" " 80	39 " "
Case 12	" " 90	61 " "
Case 13	" " 81	37 " "
Case 14	" " 71	27 " "
Case 15	" " 84	24 " "
Case 16	" " 81	51 " "
Case 17	Alive & well at 65	52 " "
Case 18	Alive & well at 60	20 " "
Case 24	Died at 94	77 " "
Case 28	" " 90	47 " "
Case 33	" " 86	70 " "
Case 35	" " 78	65 " "

* Injections of mixed bacterial vaccines (MBV) Streptococcus pyogenes and Serratia marcescens, then known as Coley's Mixed Toxins.

** Died of second primary.

10/24/85

